

## STANDARD ARTICLE

# Stall-side screening potential of a smartphone electrocardiogram recorded over both sides of the thorax in horses

Ignacio Corradini<sup>1</sup>  | Alicia Fernández-Ruiz<sup>2</sup> | Marta Barba<sup>1</sup>  |  
Javier Engel-Manchado<sup>2</sup>

<sup>1</sup>Servicio de Medicina Interna Equina, Departamento de Medicina y Cirugía Animal, Faculty of Veterinary Sciences, Universidad Cardenal Herrera CEU, CEU Universities, Valencia, Spain

<sup>2</sup>Servicio de Cardiología, Hospital Clínico Veterinario, Universidad Cardenal Herrera CEU, CEU Universities, Valencia, Spain

**Correspondence**

Ignacio Corradini, Universidad Cardenal Herrera CEU, CEU Universities, C/ Santiago Ramón y Cajal s/n, 46115 Alfara del Patriarca, Valencia, Spain.  
Email: ignacio.corradini@uchceu.es

**Abstract**

**Background:** Comparisons between smartphone ECG (SpECG) recordings obtained from the right and left sides of the thorax have not been reported in animals.

**Objectives:** To evaluate the screening potential of a SpECG obtained from both sides of the thorax and to compare the degree of agreement between the SpECG and a reference ECG (rECG) for measurement of the duration of baseline electrical deflections recorded over both sides of the thorax.

**Animals:** Fifty horses admitted to the equine hospital, university-owned horses, and horses from an endurance riding facility.

**Methods:** Prospective observational study. Simultaneous rECG and SpECG tracings were recorded on both sides of the thorax and evaluated by 2 experienced observers for interpretability, presence and classification of arrhythmias, and duration of deflections of the electrical baseline.

**Results:** Fifteen (15/50) horses had spontaneous arrhythmias. Excellent agreement was found between the 2 devices ( $\kappa = 0.91$ ;  $P < .001$ ; 95% confidence interval [CI] 0.79-1.03) for the detection of arrhythmias. Significantly more P waves were of diagnostic quality from the right side (20 versus 5,  $P = .001$ ) and significantly more QRS and QT intervals were of diagnostic quality from the left side (66 versus 38 and 62 versus 34, respectively,  $P < .001$ ). Substantial agreement for the duration of deflections between devices only was observed for the QRS interval (SpECG left).

**Conclusions and Clinical Importance:** It is important to obtain SpECG tracings from both sides of the thorax in horses. The SpECG is a useful stall-side arrhythmia-screening tool for some common arrhythmias in horses.

**KEYWORDS**

arrhythmia, atrial fibrillation, electrocardiogram, horse, premature complexes, smartphone

**Abbreviations:** APD, atrial premature depolarization; AVB, atrioventricular block; ICC, intraclass correlation coefficient; rECG, reference ECG; SpECG, smartphone ECG.

This is an open access article under the terms of the Creative Commons Attribution-NonCommercial-NoDerivs License, which permits use and distribution in any medium, provided the original work is properly cited, the use is non-commercial and no modifications or adaptations are made.

© 2020 The Authors. *Journal of Veterinary Internal Medicine* published by Wiley Periodicals, Inc. on behalf of the American College of Veterinary Internal Medicine.

## 1 | INTRODUCTION

Recently, smartphone electrocardiogram (SpECG) devices have been developed and evaluated for use in human and veterinary medicine, including horses, cattle, dogs, and cats.<sup>1-6</sup> Agreement between the SpECG and reference ECG (rECG) for the detection and classification of arrhythmias has been reported to be good in horses.<sup>7</sup>

It would be expected that the agreement between measurements of the duration of baseline electrical deflections as measured using the SpECG would be low when compared to a rECG because of the small dipole created.<sup>7</sup> However, excellent agreement between devices for the measurement of the duration of deflections as measured by using an SpECG in horses recently was reported.<sup>8</sup> For the acquisition of SpECG readings in humans, the patient touches each electrode of the device with the right and left hands, respectively, creating a recording similar to lead I in a 12-lead rECG.<sup>3</sup> However, in veterinary species, the electrodes of the SpECG must be positioned over the wall of the thorax. Both electrodes are inseparable, hence it is impossible to provide a larger dipole in SpECG recordings performed in animals. In reports on dogs and cats, patients were placed in right lateral recumbency and the SpECG was recorded over the left side of the thorax only.<sup>4,6</sup> Similarly, in recent studies performed in cattle and horses, recordings only were obtained from the left side of the thorax.<sup>7,8</sup> However, readings from the right side of the thorax have not been reported.

## 2 | OBJECTIVES

Our objectives were to (a) evaluate the stall-side screening potential of a SpECG when recordings are obtained from both sides of the thorax for the detection of spontaneous arrhythmias in horses and to (b) compare the degree of agreement between the SpECG and rECG for the measurement of the duration of deflections recorded over the left and right sides of the thorax.

## 3 | HYPOTHESES

The SpECG is a good stall-side screening tool for cardiac rhythm abnormalities in horses when recorded on either side of the thorax, and there is a good agreement between the 2 devices for the measurement of the duration of baseline electrical deflections when measured on tracings obtained from both sides of the thorax by using the SpECG.

## 4 | MATERIALS AND METHODS

### 4.1 | Animals

Client-owned horses admitted to the equine veterinary teaching hospital, university-owned horses from the school herd, and horses from a neighboring endurance riding facility were included. Ours was a

prospective, observational study. Cases were recruited over a 4-month period. The study protocol was approved by the institutional welfare and ethics committee and signed consent forms were obtained for client-owned animals.

### 4.2 | Electrocardiogram acquisition

For each horse, a 1-minute ECG tracing was recorded by using the SpECG (AliveCor Veterinary Heart Monitor AC-002 model; IDT Technology Limited, AliveCor, Inc, San Francisco, California) and the rECG (EDAN SE'1200; 3/F-B, Nanshan Medical Equipments Parc., Shekou, People's Republic of China) simultaneously, with the SpECG positioned on 1 side of the thorax. After recording on 1 side, the SpECG was placed on the opposite side of the thorax. The position of the rECG remained unchanged. The SpECG was positioned over the left and right precordial areas without clipping hair, after alcohol rubbing, and with the negative electrode (microphone end of the smartphone) positioned in a cranio-dorsal direction and the positive electrode in a caudo-ventral direction. Electrode positioning for the reference base-apex ECG was performed as follows: the yellow electrode (left arm, +) was placed over the precordial area on left side, the red electrode (right arm, -) was placed on the upper neck on the right side, and the black electrode (ground electrode) was placed at the jugular furrow over the right side to obtain a bipolar base-apex lead recording.<sup>9</sup>

The study personnel simultaneously started recordings with a rECG and a SpECG to synchronize both devices. A 1-minute recording using the SpECG over the left side was performed first, followed by another recording using the SpECG placed over the right side of the thorax, while the rECG remained unchanged. The 1-minute readings from the SpECG were recorded at a paper speed of 25 mm/s with a gain of 20 mm/mV and a 50 Hz filter, and saved into a PDF file in medical standard format for print. The 1-minute recordings obtained using the rECG were printed directly using the ECG machine at a paper speed of 25 mm/s with a gain of 10 mm/mV and a 100 Hz filter (lead I). Two experienced observers independently evaluated all paper copies of the tracings obtained simultaneously using both devices on each side of the thorax.

### 4.3 | Interpretability of the recordings and classification of cardiac rhythm abnormalities

The observers rated all SpECG tracings based on general quality of the recordings with the aid of a magnifying glass. Interpretability of the P wave, QRS interval, and T wave were evaluated on each side of the thorax of all horses. The criteria used to classify the interpretability included ease of detection of each electrical event, amplitude, and clear delimitation between baseline and the cardiac electrical deflections. Each rater assigned 1 of the following rankings as follows: (a) noninterpretable (non-visible or hardly visible deflection with unclear delimitation between baseline and the vertical deflection of each wave on the SpECG tracing), (b) interpretable but with difficulty (easily visible deflection with unclear

delimitation between the baseline and vertical deflection of each wave on the SpECG tracing), and (c) of diagnostic quality, defined as an easily visible deflection with clear delimitation between the baseline and vertical deflection of each wave on the SpECG tracing. Heart rate was calculated manually over a period of 1 minute.

Presence or absence of notable cardiac rhythm abnormalities and their classification (defined as atrial fibrillation, atrial premature depolarizations [APDs], ventricular premature depolarizations) or conduction disorders (including different degrees of atrioventricular blocks [AVBs] and sinus pause), was confirmed by the 1-minute reference base-apex ECG readings and the results were compared at a later time to those obtained using the SpECG taken from each side of the thorax.

On a second assessment, tracings obtained using the SpECG from the right and left sides from horses with arrhythmias were compared side-by-side by the examiners to perform a subjective evaluation of the quality of the readings.

#### 4.4 | Comparison of the duration of baseline electrical deflections

Ten cardiac cycles from 10 horses (5 cardiac cycles from each side of the thorax) were randomly selected as follows: each cardiac cycle was assigned consecutive numbers from the beginning of the tracing. An online random number generator ([www.random.org](http://www.random.org)) was used to select the cardiac cycles to be evaluated individually. Five consecutive cardiac cycles starting at the randomly generated number were used to record the duration of electrical deflections on both sides of the thorax. The durations of P wave, PR, QRS, and QT intervals were measured to the nearest fifth of a millimeter with the aid of a magnifying glass by both observers.

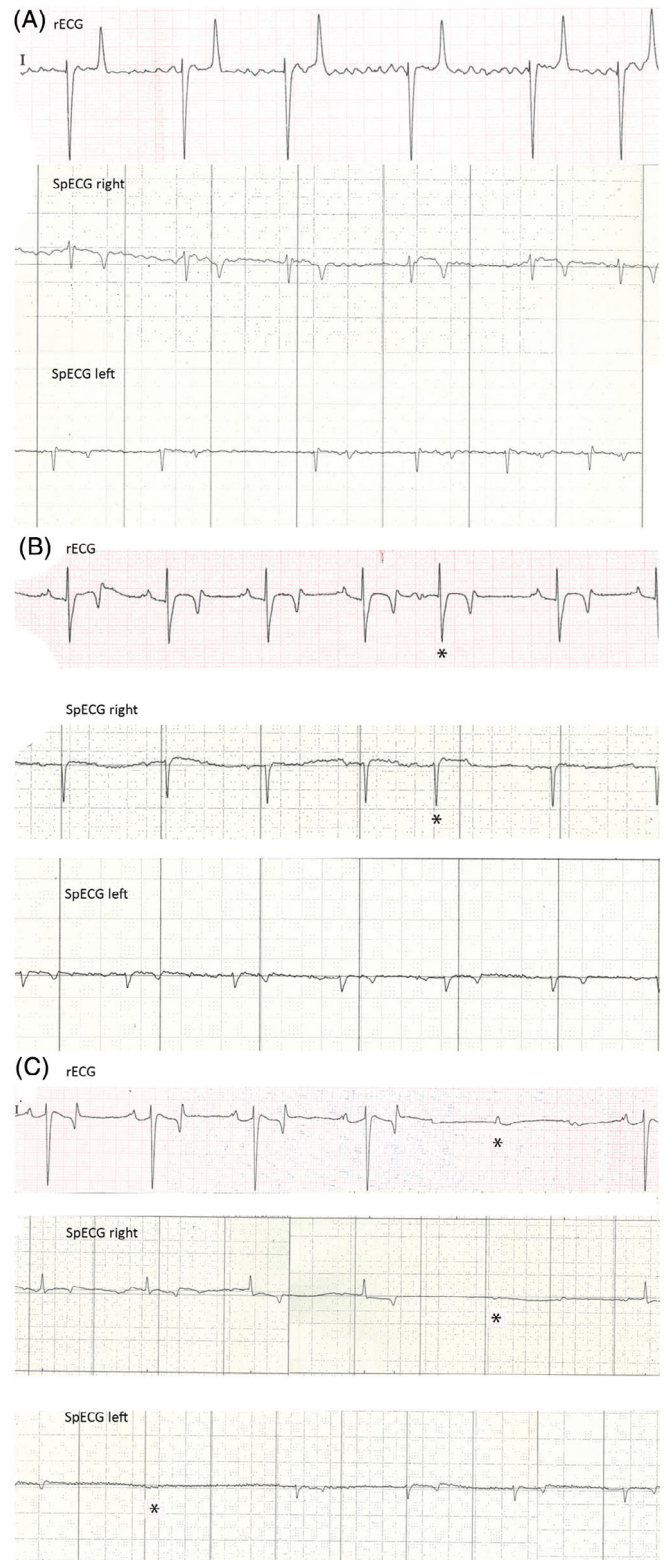
## 5 | DATA ANALYSIS

Data were tested for normality using the Shapiro-Wilk test and Q-Q plots. Data are presented as mean and SD. Differences were considered significant when  $P \leq .05$ . Data were analyzed using SPSS 24.0 (IBM Corp, IBM, Armonk, New York).

**TABLE 1** Cardiac rhythm abnormalities detected in the study horses by the 2 raters, compared with the rECG

Cardiac rhythm abnormalities	rECG	SpECG	
		Rater 1	Rater 2
AF	1	1	1
APD	2	2	1
1° AVB	1	1	1
2° AVB	6	6	6
Sinus pause	5	5	5

Abbreviations: 1° AVB, first-degree atrioventricular block; 2° AVB, second-degree atrioventricular block; AF, atrial fibrillation; APD, atrial premature depolarization; SpECG, smartphone ECG.



**FIGURE 1** Side-by-side examples of SpECG tracings obtained from the right and left sides of the thorax in horses with A, atrial fibrillation; B, atrial premature depolarization (APD); and C, second-degree AV-block. Note that for example A, the APD was only recorded while the recording was obtained from the right side of the thorax. The tracing from the left side has been included to allow for comparison of the baseline electrical events between sides and the rECG

	rECG	SpECG right	rECG	SpECG left
P wave	0.11 (0.037)	0.072 (0.029)	0.098 (0.027)	0.069 (0.027)
P-R interval	0.29 (0.079)	0.27 (0.081)	0.28 (0.081)	0.28 (0.077)
QRS interval	0.086 (0.018)	0.065 (0.021)	0.089 (0.020)	0.078 (0.022)
Q-T interval	0.46 (0.033)	0.48 (0.051)	0.44 (0.039)	0.46 (0.036)

**TABLE 2** Mean (SD) for the duration (seconds) of the P wave, P-R, QRS, and Q-T intervals as measured on tracings obtained with the smartphone from the right and left sides of the thorax and the rECG

**TABLE 3** Variance between the reference ECG and SpECG parameters for the duration of different baseline electrical deflections

		Absolute bias S [mean (SD)]	Student's t test P value	Proportional bias ( $r^2$ -P value)	ICC $\alpha$ [CI] P	Correlation (r)
P wave	L	+0.028 (0.030)	<.001	<0.001 (.92)	.18 [-0.29 to 0.48] <.19	0.39
	R	+0.037 (0.030)	<.001	0.022 (.15)	.76 [0.64 to 0.84] <.001	0.62
PR interval	L	+0.0027 (0.050)	.62	0.008 (.42)	.89 [0.83 to 0.93] <.001	0.80
	R	+0.023 (0.054)	<.001	0.001 (.78)	.85 [0.74 to 0.91] <.001	0.77
QRS interval	L	+0.011 (0.020)	<.001	0.008 (.39)	.63 [0.35 to 0.77] <.001	0.52
	R	+0.021 (0.021)	<.001	0.028 (.09)	.44 [0.11 to 0.70] <.001	0.45
QT interval	L	-0.025 (0.03)	<.001	0.008 (.38)	.58 [0.20 to 0.76] <.001	0.67
	R	-0.032 (0.046)	<.001	0.192 (.001) <sup>a</sup>	.54 [0.22 to 0.71] <.001	0.47

Abbreviations: ICC, intraclass correlation coefficient; L, SpECG recording obtained from left side of the thorax; R, SpECG recording obtained from right side of the thorax.

<sup>a</sup>Linear regression analysis results are consistent with the presence of proportional bias.

## 5.1 | Stall-side screening potential of the SpECG

Cohen's kappa ( $\kappa$ ) statistical analysis was used to evaluate agreement between devices and interrater reliability for presence of cardiac rhythm abnormalities (present or absent) and classification of cardiac arrhythmias between the rECG and SpECG devices, respectively, for each side of the thorax. The sample size was determined based on published data for the selection of minimum sample size requirements for Cohen's kappa ( $2 \times 2$  table, at a power of 80% and an alpha value of .05).<sup>10</sup>

## 5.2 | Interpretability of the baseline electrical deflections

The interpretability of the P wave, QRS interval and T wave from the left and right sides was compared by means of a Pearson chi-square test with multiple pairwise comparisons, yielding probability values for each combination of independent category levels. A Bonferroni correction to control for type I error inflation was applied.

## 5.3 | Comparison of the duration of baseline electrical deflections

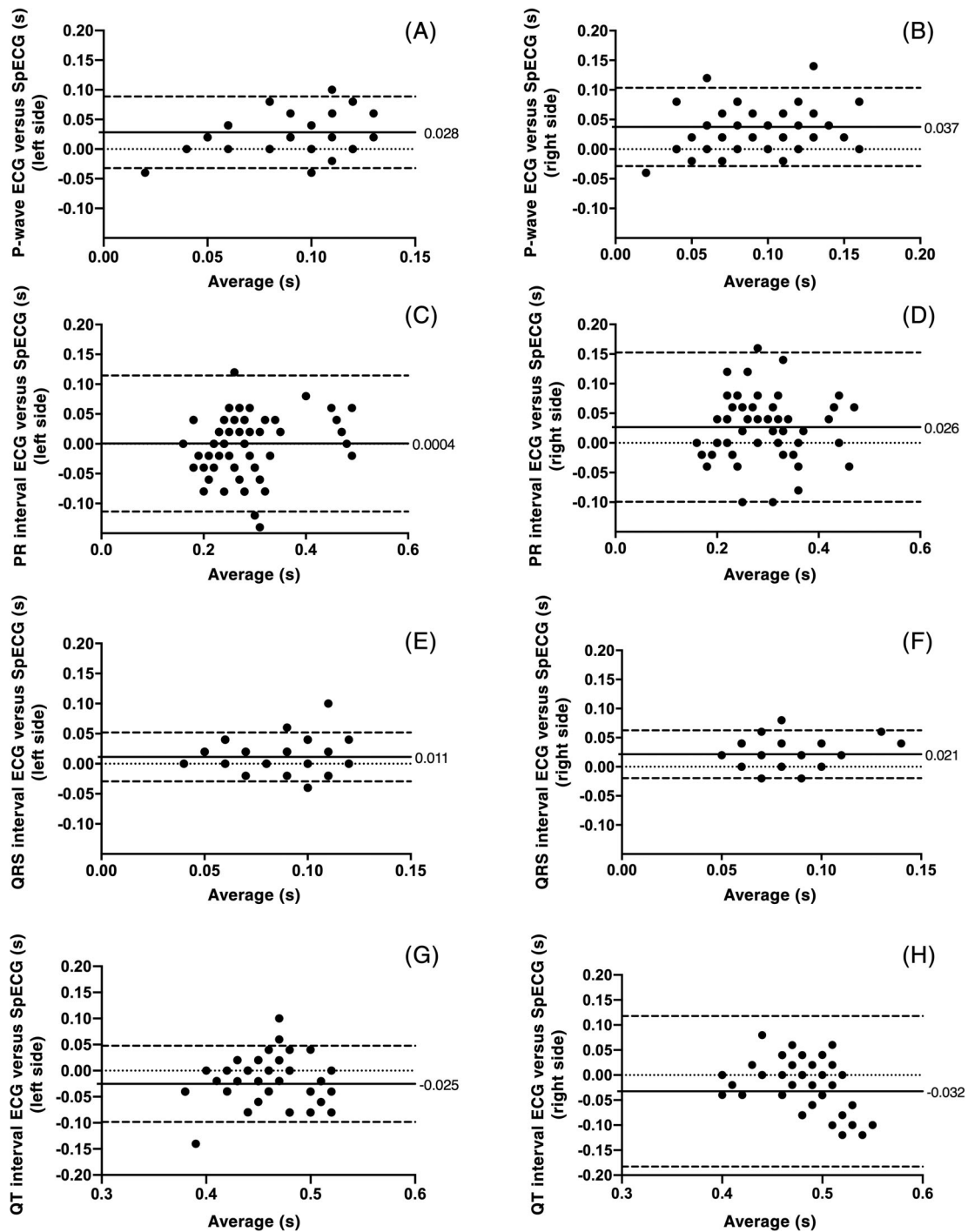
The means and SDs for the duration in seconds of the P wave, PR, QRS, and QT intervals were tested for significant differences between measurements obtained using both devices (SpECG and rECG base-apex lead) by use of a paired sample t test. To evaluate the reliability (versus the rECG) of the SpECG, the intraclass correlation coefficient

(ICC) was calculated. Limits of agreement (Bland-Altman) plots were used to assess the pattern and extent of the agreement between both devices for each side of the thorax. Substantial agreement was predefined as an absolute mean bias of <0.02 seconds for all measured electrical events based on previous studies.<sup>11</sup> Acceptable limits of agreement (95% of observations) were determined a priori (95% of the recordings within  $\pm 0.04$  seconds of the mean difference for the P wave and QRS interval, and  $\pm 0.05$  seconds of the mean difference for the P-R and Q-T intervals). When a consistent bias (absolute systematic bias) was detected, the mean difference was recorded and subtracted from or added to the SpECG measurements, and the limits of agreement were recalculated. To compare inter-rater variability, the ICC for measurements performed by both raters on each side of the thorax was calculated.

Sample size was determined based on a simplified guide to determine the sample size requirements for estimating the ICC for 2 rating instruments with 5 observations per subject ( $R_0$  of 0.7 versus  $R_1$  of 0.9 with a power of 80% and an alpha value of .05).<sup>12</sup>

## 6 | RESULTS

Fifty horses aged 1 month to 31 years were enrolled (mean, 12.04 years). There were 25 females (51.02%), 13 stallions (26.53%), and 11 geldings (20.40%), sex was not registered in 1 foal. Horse breeds included 18 Arabian horses, 17 crossbred horses, 8 Andalusian and 2 Andalusian crossbred horses, 2 Shetland ponies, 1 Hanoverian, 1 KWPN, and 1 Percheron horse. Two hundred SpECG and rECG tracings were recorded (50 rECG and 50 SpECG recordings per side



**FIGURE 2** Limits of agreement (Bland-Altman) plots for the differences and mean duration of electrical events between the rECG and SpECG raw measurements performed over the left and right sides of the thorax. Substantial agreement between the rECG and the SpECG (absolute bias < 0.02 seconds) was observed for the PR and QRS intervals recorded over the left side of the thorax; however, the limits of agreement for the difference of duration of PR interval between devices ( $\Delta$ PR) exceeded the predefined acceptable values (C). Agreement between the rECG and SpECG for the duration of QRS interval from the right side showed good agreement, however it was not classified as substantial. Agreement between devices for the rest of electrical deflections was acceptable to poor (A,B,G,H). A proportional bias of the measurements obtained with the SpECG for the QT interval recorded over the right side of the thorax ( $r^2 = .192$ ,  $P < .001$ ) (H) can be seen

for each of all of the horses included in the study). Automatic detection of the mean (SD) heart rate by the SpECG was 4.6 ( $\pm$ 14.0) beats per minute above that of the rECG. Manual measurements of heart rate were the same for both devices.

## 6.1 | Stall-side screening potential of the SpECG

Fifteen (30%) horses had a spontaneous arrhythmia as detected by an rECG (Table 1). Fourteen of the 15 arrhythmias were recorded from

both sides of the thorax. One arrhythmia (APD) was recorded only while the SpECG was placed over the right side of the thorax in 1 horse. Both observers detected the 14 arrhythmias recorded on tracings over both sides of the thorax. In a single instance, 1 of the observers detected an arrhythmia on the rECG but not on the SpECG (APD only present on the recording obtained from the right side). Excellent concordance was found between both devices for the screening of cardiac rhythm abnormalities ( $\kappa$ , 0.912;  $P < .001$ ; 95% CI, 0.79-1.03).

## 6.2 | Interpretability of the baseline electrical deflections

A significant difference in the interpretability of P waves was found between SpECG tracings obtained from the right and left sides of the thorax. Significantly more P waves were of diagnostic quality on tracings obtained from the right side compared to the left side (20 versus 5, respectively;  $P < .001$ ). Significantly more QRS intervals were of diagnostic quality on tracings obtained from the left side compared to the right side (66 versus 38, respectively;  $P < .001$ ) and more QRS intervals were classified as “interpretable but with difficulties” or “non-interpretable” when recorded over the right compared to the left side of the thorax (62 versus 34, respectively;  $P < .001$ ). Significantly more T waves were of diagnostic quality on tracings obtained from the left compared to the right side of the thorax (79 versus 47, respectively;  $P < .001$ ) and more T waves were classified as “interpretable with difficulties” or “noninterpretable” on the right compared to the left side (53 versus 21, respectively;  $P < .001$ ).

Upon repeat evaluation of the SpECG tracings from those horses that had cardiac rhythm abnormalities, there were 3 instances (1 atrial fibrillation and 2 second-degree AVB) in which the raters considered that recordings taken over the right side would have provided a subjective advantage for the classification of arrhythmias versus those taken over the left side (Figure 1).

## 6.3 | Comparison of the duration of baseline electrical deflections

The mean (SD) duration of the electrical deflections recorded using the rECG and SpECG from each side of the thorax is summarized in Table 2. A high concordance (ICC) was found between both devices for measurement of the duration of P wave (SpECG on the right side) and PR interval (both sides), and moderate concordance was found for the QRS interval (SpECG on left side; Table 3). However, the measurements obtained using the SpECG underestimated the duration of the P wave, P-R interval, and QRS interval and overestimated the duration of the Q-T interval. Bland-Altman plots depicting the differences between the rECG and the SpECG are shown in Figure 2A-H. Substantial agreement between the rECG and the SpECG (absolute bias  $< 0.02$  seconds) was observed for the

PR and QRS intervals recorded over the left side of the thorax (Table 3). However the limits of agreement for the difference of duration of PR interval between devices exceeded the predefined acceptable values (Figure 2C). Agreement between the rECG and SpECG for the duration of QRS interval from the right side showed good agreement, but it was not classified as substantial agreement (Table 3). Agreement between devices for the remainder of electrical deflections was acceptable to poor (Figure 2A,B,G,H). In addition, there was a proportional bias of the measurements obtained using the SpECG for the QT interval recorded over the right side of the thorax ( $r^2 = .192$ ;  $P < .001$ ; Figure 2H).

Very good agreement was found between both raters (ICC) for the measurements performed using the SpECG for the duration of PR and QT intervals, moderate for the QRS interval and medium low for the duration of the P wave.

## 7 | DISCUSSION

Our study showed that the side of the thorax at which the SpECG tracing is recorded has an impact on the interpretability of baseline electrical deflections. In addition, it shows that the SpECG is not a reliable method for the measurement of the duration of deflections of the electrical baseline. Variations in the positioning of the electrodes of the SpECG and rECG over the surface of the thorax could have accounted for important differences observed in the duration of baseline electrical deflections between devices evaluated in our study. The data also show that the SpECG may be valuable as a stall-side screening tool for the detection of some common cardiac electrical conduction abnormalities in horses, as recently described.<sup>7</sup>

In a recent study in horses, 1 of the limitations experienced by the raters was the impossibility to identify ectopic P waves on the recording obtained using a SpECG, preventing observers from determining whether an arrhythmia was ventricular or supraventricular in origin.<sup>7</sup> In our study, P waves were more often of diagnostic quality when the SpECG was placed over the right side of the thorax compared to the left. The addition of SpECG recordings obtained from right side of the thorax also appeared to provide a subjective advantage in the identification of some arrhythmias in 3/15 cases. The fact that P waves were shown to be more noticeable over the right side should encourage clinicians to record SpECG tracings from both sides of the thorax. A limitation of our study is that few supraventricular arrhythmias occurred during the study period. In addition, the design of the study does not allow determination of the diagnostic value of the SpECG for the detection of arrhythmias.

In previous studies in which the SpECG was used in veterinary species, no comparisons between the right and left sides were described.<sup>4,6-8</sup> In our study, simultaneous recordings using both devices were performed on 1 side at a time, immediately changing the SpECG to the other side of the thorax to obtain a second simultaneous recording with both devices. In 1 instance, both devices recorded a supraventricular arrhythmia (APD), whereas the SpECG recording was obtained from the right side. This arrhythmia however did not occur, whereas recordings were

performed over the left side, precluding the possibility to compare the SpECG recordings from both sides for that individual horse. It would have been ideal to obtain all 3 recordings (the rECG and SpECG readings from both sides) simultaneously, but only 1 SpECG device was available for the study.

In our study, interpretability of the P wave was superior when the SpECG was placed on the right side of the thorax, suggesting that recording SpECG tracings from both sides of the thorax may increase the ability to screen for cardiac rhythm abnormalities in horses. When the SpECG is used in domestic animals, a small dipole is created to record the ECG tracings directly from the wall of the thorax, providing a tracing with variable polarity and smaller wave amplitudes.<sup>4,8</sup> This could have an impact on the ability to detect and classify arrhythmias involving conduction of the atria. On the other hand, QRS and QT intervals were easier to interpret on tracings recorded over the left side of the thorax using the SpECG.

Concerns have been raised about the ability of the SpECG to provide accurate measurements of specific electrical events in horses.<sup>7</sup> However, excellent agreement between devices for the measurement of baseline electrical events in horses has been published recently.<sup>8</sup> In contrast to that study, there was substantial agreement as defined a priori between devices only for the QRS interval measured over the left side of the thorax in our study. The duration of all electrical events was shorter as measured by the SpECG when compared to the rECG, except for the QT interval. The mean duration of the QT interval was longer when recorded by the SpECG. Several differences with the previous study<sup>8</sup> include the fact that in our study acceptable absolute bias and limits of agreement between devices were determined a priori, before statistical analysis of the data was performed. In addition, 2 observers (instead of 1) evaluated the ECG tracings in our study.<sup>8</sup>

Except for the P-R and QRS intervals measured using the SpECG over the left side of the thorax, all other measured variables showed an absolute bias of >0.02 seconds compared to the rECG. Although substantial agreement can be classified based on absolute bias only, it is considered best practice to also predefine maximum limits of agreement and then proceed to perform the statistical tests necessary to evaluate whether these limits are exceeded or not.<sup>13</sup> Although the absolute bias for the duration of the P-R interval (with the SpECG recorded over the left side) showed substantial agreement ( $\Delta < 0.02$  seconds), the limits of agreement (95% CI) were wider than those defined a priori for our study (Figure 2D). The difference between devices for the duration of the P wave as measured using the SpECG over the right and left sides, and QRS and P-R intervals measured over the right side of the thorax, showed an absolute positive systematic bias (Figure 2). Constant biases indicate that the test measurements obtained with the test device (SpECG) measure consistently higher or lower intervals when compared to a reference method (rECG).<sup>14</sup> Part of the variability observed on the tracings obtained could be explained by vectocardiography theory that shows that the shape and magnitude of electrical cardiac deflections vary depending on the placement of surface electrodes on the body of the horse.<sup>15</sup> Similarly, it is likely that the bias observed for the duration of the P wave recorded over the right side of the thorax also could be explained by the this theory. There is an obvious difference in the

position of the SpECG electrodes over the thoracic surface when the device is placed on the right versus left side of the thorax.

In our study, the absolute bias in PR interval obtained (+0.0027 seconds on left and +0.023 seconds on right sides, respectively) was relatively small. The moderate correlation of the SpECG with the rECG for the duration of QRS (left side +0.011 seconds and right side +0.021 seconds) suggests that VPDs could be screened using the SpECG, considering that VPDs may show abnormal QRS morphology. Establishing normal values for the duration of electrical deflections recorded with the SpECG may be an approach that could help overcome some of the problems associated with absolute biases observed in our study. However, this device should not be used to monitor dangerous ventricular arrhythmias. A reference base-apex ECG should be used for primary diagnosis or monitoring of potentially life-threatening cardiac arrhythmias. For instance, an increase in >25% of QRS duration from baseline (0.019 seconds on the left side and 0.016 seconds on the right side) during quinidine treatment for atrial fibrillation potentially could be missed using the SpECG. The absolute bias between devices observed in our study was +0.011 seconds and +0.021 seconds for the left and right sides, respectively. However, the SpECG should be tested to evaluate whether it is capable of detecting a trend of increase in duration of the QRS interval of 25% from the baseline. In a previous study evaluating VPD and R-on-T phenomenon in horses suffering from solitary atrial fibrillation, QRS interval was 0.025 seconds longer than normal QRS interval at gallop and 0.1 seconds shorter than normal QRS interval at rest.<sup>16</sup> The absolute bias for the QT interval measurements obtained using the SpECG in our study was -0.025 seconds on the left side and -0.032 seconds on the right side. In a recent study, significant QT interval prolongation after sotalol treatment resulted in a 0.039 seconds increase in the QT interval mean of the sotalol group compared to control group.<sup>17</sup> Therefore, QT prolongation should be detected despite the shorter QT interval absolute bias measured using the SpECG in our study. Again, establishing normal values for the duration of cardiac electrical deflections in horses using the SpECG could be helpful. Another factor that could influence the clinical interpretation of SpECG measurements is body weight, because the larger the horse, the longer the PR and QT intervals.<sup>18</sup>

One of the main limitations of our study was that a low number of horses had supraventricular and ventricular arrhythmias. The data does not show improved detection and classification of arrhythmias on 1 side versus the other. Our findings show that obtaining SpECG readings from both sides of the thorax provides complementary information that may aid in the screening of cardiac rhythm abnormalities. Our study shows that the device is a valuable screening tool for some common arrhythmias in horses. However, the objective of using an SpECG should not be to pursue a primary clinical diagnosis of cardiac rhythm disturbances, but to provide an affordable, widely available tool for the screening of cardiac rhythm abnormalities in horses. As described in a recent study in horses, automatic detection of heart rate by the SpECG was inaccurate when compared to manual heart rate calculation.<sup>7</sup> The automatic heart rate detection used by the SpECG should not be relied upon for the determination of the heart rate in horses.

## ACKNOWLEDGMENTS

The authors acknowledge students S. Dani, A. Duchenne, C. Germain, and L. Lafin for their help during the study execution phase. This work was presented at the 11th ECEIM Annual Congress, November, Ghent, Belgium.

## CONFLICT OF INTEREST DECLARATION

Authors declare no conflict of interest.

## OFF-LABEL ANTIMICROBIAL DECLARATION

Authors declare no off-label use of antimicrobials.

## INSTITUTIONAL ANIMAL CARE AND USE COMMITTEE (IACUC) OR OTHER APPROVAL DECLARATION

This study was approved by the University Institutional Welfare and Ethics Committee (CEEA\_17\_002).

## HUMAN ETHICS APPROVAL DECLARATION

Authors declare human ethics approval was not needed for this study.

## ORCID

Ignacio Corradini  <https://orcid.org/0000-0002-4053-8863>

Marta Barba  <https://orcid.org/0000-0002-3677-7239>

## REFERENCES

- Bonelli F, Vezzosi T, Meylan M, et al. Comparison of smartphone-based and standard base-apex electrocardiography in healthy dairy cows. *J Vet Intern Med.* 2019;33(2):981-986.
- Gropler MR, Dalal AS, Van Hare GF, Silva JNA. Can smartphone wireless ECGs be used to accurately assess ECG intervals in pediatrics? A comparison of mobile health monitoring to standard 12-lead ECG. *PLoS One.* 2018;13:e0204403. <https://doi.org/10.1371/journal.pone.0204403>.
- Haberman ZC, Jahn RT, Bose R, et al. Wireless smartphone ECG enables large-scale screening in diverse populations. *J Cardiovasc Electrophysiol.* 2015;26(5):520-526.
- Kraus MS, Gelzer AR, Rishniw M. Detection of heart rate and rhythm with a smartphone-based electrocardiograph versus a reference standard electrocardiograph in dogs and cats. *J Am Vet Med Assoc.* 2016;249(2):189-194.
- Muhlestein JB, Le V, Albert D, et al. Smartphone ECG for evaluation of STEMI: results of the ST LEUIS pilot study. *J Electrocardiol.* 2015;48(2):249-259.
- Vezzosi T, Buralli C, Marchesotti F, et al. Diagnostic accuracy of a smartphone electrocardiograph in dogs: comparison with standard 6-lead electrocardiography. *Vet J.* 2016;216:33-37.
- Kraus MS, Rishniw M, Divers TJ, Reef VB, Gelzer AR. Utility and accuracy of a smartphone-based electrocardiogram device as compared to a standard base-apex electrocardiogram in the horse. *Res Vet Sci.* 2019;125:141-147.
- Vezzosi T, Sgorbini M, Bonelli F, et al. Evaluation of a smartphone electrocardiograph in healthy horses: comparison with standard base-apex electrocardiography. *J Equine Vet Sci.* 2018;67:61-65.
- Verheyen T, Decloedt A, De Clercq D, et al. Electrocardiography in horses, part 1: how to make a good recording. *Vlaams Diergen Tijds.* 2010;79:331-336.
- Bujang MA, Baharum N. Guidelines of the minimum sample size requirements for kappa agreement test. *Epidemiol Biostat Public Health.* 2017;4(2):e12267.
- Garabelli P, Stavrakis S, Albert M, et al. Comparison of QT interval readings in normal sinus rhythm between a smartphone heart monitor and a 12-lead ECG for healthy volunteers and inpatients receiving sotalol or dofetilide. *J Cardiovasc Electrophysiol.* 2016;27(7):827-832.
- Bujang MA, Baharum N. A simplified guide to determination of sample size requirements for estimating the value of intraclass correlation coefficient: a review. *Arch Orofac Sci.* 2017;12:1-11.
- Giavarina D. Understanding Bland Altman analysis. *Biochem Med (Zagreb).* 2015;25(2):141-151.
- Magari RT. Statistics for laboratory method comparison studies. *BioPharm.* 2002;15:28-32.
- Holmes JR, Alps BJ. Studies into equine electrocardiography and vectorcardiography II. Cardiac vector distributions in apparently healthy horses. *Can J Comp Med.* 1967;31:150-155.
- Verheyen T, Decloedt A, Van Der Vekens N, et al. Ventricular response during lungeing exercise in horses with lone atrial fibrillation. *Equine Vet J.* 2013;45(3):309-314.
- Decloedt A, Broux B, De Clercq D, et al. Effect of sotalol on heart rate, QT interval, and atrial fibrillation cycle length in horses with atrial fibrillation. *J Vet Intern Med.* 2018;32(2):815-821.
- Schwarzwald CC, Kedo M, Birkmann K, Hamlin RL. Relationship of heart rate and electrocardiographic time intervals to body mass in horses and ponies. *J Vet Cardiol.* 2012;14(2):343-350.

**How to cite this article:** Corradini I, Fernández-Ruiz A, Barba M, Engel-Manchado J. Stall-side screening potential of a smartphone electrocardiogram recorded over both sides of the thorax in horses. *J Vet Intern Med.* 2020;34:2101-2108. <https://doi.org/10.1111/jvim.15795>