

# An Extensile Approach to the Radial Aspect of the Carpus: "The Link Incision"

Syed Suhaib Jameel, MBBS, MS, MRCS and  
Roshin Thomas, MBBS, MS, DNB, MRCS, Dip Sports Med, FRCS (Tr&Orth)

**Abstract:** The structures on the radial side of the wrist and thumb base can be approached by a longitudinal incision on the radial side of the wrist. However, longer longitudinal scars can be cosmetically unacceptable and can result in a scar contracture. It is preferable to curve longer incisions along the Langer's skin lines to achieve better scar characteristics. Curving the incision also enables an extensile approach and provides easy access to the thumb base, radial carpus, and radial wrist joint. We describe our approach as a "Link" between the most common approaches that surgeons are familiar with; the dorsoulnar approach to the thumb metacarpophalangeal joint for ulnar collateral ligament repair and the flexor carpi radialis approach for distal radial fracture fixation. The zone between these two incisions is not as frequently approached. Our incision connects these two well established incisions and we have described a step by step approach to this unfamiliar area. This "Link zone" overlies the thumb trapeziometacarpal joint, scaphotrapezio-trapezoid joint, and the radial styloid. It contains superficial branches of the radial nerve, first extensor compartment tendons, and the deep branch of radial artery in the anatomic snuff box. The "Link incision" is an extensile approach in both the proximal and distal directions.

**Key Words:** trapeziometacarpal joint, scaphotrapeziotrapezoid joint, radial styloid, first extensor compartment, trapeziectomy, link incision, surgical technique

(*Tech Hand Surg* 2019;23: 94–100)

The wrist carpus can be approached through various incisions depending on the structure that needs to be accessed.<sup>1</sup> Although modifications continue to evolve, basic principles of surgical exposure remain the same.<sup>2</sup>

Repair of ulnar collateral ligament (UCL) of the thumb metacarpophalangeal (MCP) joint and distal radial fracture fixation through the flexor carpi radialis (FCR) approach are two common procedures surgeons are familiar with. However, the area between these two incisions is more difficult to approach due to the complex anatomic structures in this zone. The senior author developed an approach connecting ("linking") the proximal aspect of the UCL incision and the distal aspect of the FCR incision using a curved radial incision to safely access this area (Fig. 1). We have described the step by step technique of this approach.

From the Dumfries and Galloway Royal Infirmary, Dumfries, Scotland, UK. Conflicts of Interest and Source of Funding: The open access fee has been funded by the Research & Development Unit, Dumfries & Galloway Royal Infirmary. The authors report no conflicts of interest.

Address correspondence and reprint requests to Roshin Thomas, MBBS, MS, DNB, MRCS, Dip Sports Med, FRCS (Tr&Orth), Department of Trauma and Orthopaedics, Dumfries and Galloway Royal Infirmary, A75, Cargenbridge, Dumfries, DG2 8RX, Scotland, UK.  
E-mail: roshinthomas@nhs.net.

Copyright © 2019 The Author(s). Published by Wolters Kluwer Health, Inc. This is an open-access article distributed under the terms of the Creative Commons Attribution-Non Commercial-No Derivatives License 4.0 (CCBY-NC-ND), where it is permissible to download and share the work provided it is properly cited. The work cannot be changed in any way or used commercially without permission from the journal.

## ANATOMY

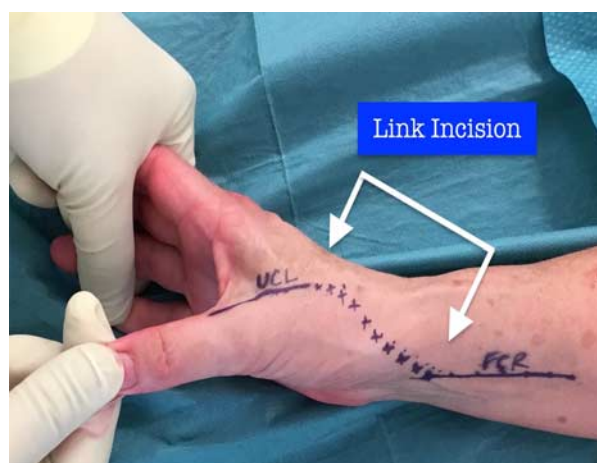
The structures encountered during the exposure using the "link incision" include superficial branches of the radial nerve, first extensor compartment tendons and deep branch of the radial artery. The link incision enables easy access to the FCR and abductor pollicis longus (APL) tendons if they are required for a reconstruction and the extensor carpi radialis longus (ECRL) can also be exposed by retracting the dorsal skin flap. In the deeper plane, bony structures extending from the base of the first metacarpal to the radial aspect of the distal radius can be safely exposed.

### Superficial Branch of the Radial Nerve (SBRN)

About 8 cm proximal to the radial styloid, the SBRN becomes subcutaneous by piercing the deep fascia between the brachioradialis and ECRL tendons. Approximately 5 cm proximal to the radial styloid the SBRN divides into a lateral and medial branch.<sup>3</sup> The lateral branch supplies the dorsoradial aspect of the thumb<sup>4</sup> and the medial branch goes to the dorsal aspect of the wrist and splits into 3 or 4 branches providing sensory innervation to the ulnar aspect of the thumb, dorsal aspect of index, middle finger, and dorsoradial aspect of ring finger.<sup>5</sup> Overall the SBRN supplies the dorsal aspect of lateral three and half digits. The lateral branch lies in close proximity with the first extensor compartment and is at most risk to damage at the time of surgery. Variations of the SBRN branching pattern have been described<sup>6</sup> and branches of the cephalic vein are closely related to the SBRN in the radial styloid area.<sup>7</sup>

### Deep Branch of the Radial Artery

At the level of the wrist, the radial artery lies lateral to the FCR tendon in close association with the superficial branch of the



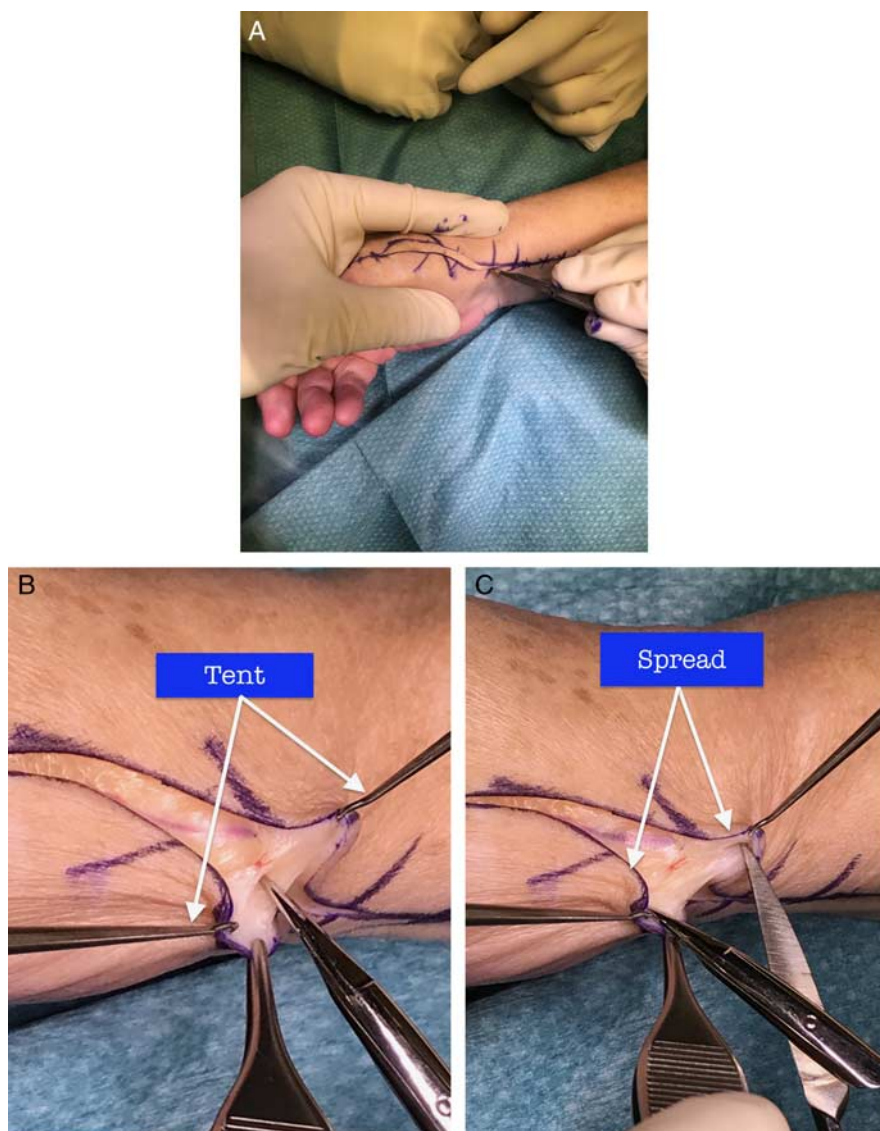
**FIGURE 1.** Link Incision connecting UCL incision and FCR incision. FCR indicates flexor carpi radialis; UCL, ulnar collateral ligament. [full color online](#)

radial nerve and lateral cutaneous nerve of forearm.<sup>8</sup> It then divides into a superficial palmar branch and a deep dorsal branch just proximal to the wrist crease. The superficial palmar branch passes through, and occasionally over the thenar muscles and anastomoses with the superficial branch of the ulnar artery to form the superficial palmar arch.<sup>4</sup> The deep dorsal branch of radial artery, enters the floor of anatomic snuff box under the tendons of APL and extensor pollicis brevis (EPB).<sup>9</sup> It courses distally in the anatomic snuff box toward the first intermetacarpal area and then enters the palmar aspect by passing between the two heads of first dorsal interossei. It arches in the palm to anastomose with deep branch of ulnar artery to complete the deep palmar arch.<sup>4,5</sup> The deep branch of the radial artery can divide into 2 or 3 branches before passing between the two heads of the first dorsal interossei.<sup>10</sup> Before formation of deep palmar arch, the radial artery gives out branches including the dorsal carpal branch, first to fourth dorsal metacarpal arteries, arteria princeps pollicis, and the radialis indicis.<sup>4,5</sup> The clinically relevant branches arising from

the deep branch of the radial artery including the 1,2 intercompartmental supraretinacular artery and dorsal scaphoid branch are found in the anatomic snuff box and 3 different patterns of origin have been described.<sup>11</sup> The venae comitantes accompany the artery and are prone to injury during dissection due to its thinner wall.

### First Extensor Compartment

The first extensor compartment is a fibro-osseous tunnel formed by the extensor retinaculum and a shallow osseous groove at the lateral edge of the radial styloid containing 2 tendons, APL and EPB.<sup>12</sup> Common variations seen in this compartment are the presence of a vertical septum which splits this into a distinct subcompartment and presence of an osseous ridge with a double groove in the bony floor.<sup>12</sup> The presence of a septum varies in literature and in cadaveric studies range from 24% to 77.5%.<sup>13,14</sup> APL can have multiple slips, EPB could be absent in nearly 6% of healthy individuals<sup>14</sup> and rarely



**FIGURE 2.** A, Incising skin under tension to expose subcutaneous fat. B and C, Skin flaps elevated in a “tent and spread” manner using skin hooks and dissecting scissors. [full color online](#)

an APL tendon slip can be found along with the EPB in its subcompartment.<sup>15</sup>

**INDICATIONS/CONTRAINDICATIONS**

The link incision can be used to access all bony and soft tissue structures along the radial aspect of distal radius, radial carpus and thumb metacarpal base (The Link Zone). Furthermore, it can be extended safely both in the proximal and distal directions to access structures beyond the link zone. The approach enables the key structures to be identified and secured on the way-in and they remain safely retracted throughout the procedure.

**COMPLICATIONS**

The SBRN is highly vulnerable to traumatic and iatrogenic injury.<sup>7,16</sup> The variable branching pattern of the SBRN around the area of the radial styloid necessitates careful dissection to identify and protect the branches from iatrogenic injury. Delicate handling of the SBRN branches can help avoid postoperative paresthesia along its distribution. Variations of radial artery, both in its course and branches at the anatomic snuffbox predisposes this pedicle to injury.<sup>17</sup> Careful mobilization and retraction with vascular slings helps secure the vascular pedicle from damage.

**TECHNIQUE**

**Step-1: Skin Incision (The Link Incision)**

The “link incision” is an S-shaped curved incision extending from the thumb MCP joint on the dorsoulnar side (proximal aspect of the UCL incision) to the volar aspect of the wrist (distal aspect of the FCR incision) (Fig. 1). The transverse part of the incision can be placed along Langer’s skin lines overlying the joint that needs to be addressed or obliquely connecting the UCL and FCR incisions if multiple joints need to be exposed. The incision can be extensile in the distal direction along the UCL incision and proximally along the FCR incision. The curve of the “S” shaped incision can be narrow or broad depending on the extent of skin flap retraction needed for the exposure. The proximal part of the incision (FCR part of the incision) can be placed further radially, parallel to the FCR, if exposure of the FCR and radial artery in this area is unnecessary for the procedure. Hence, the incision is versatile with

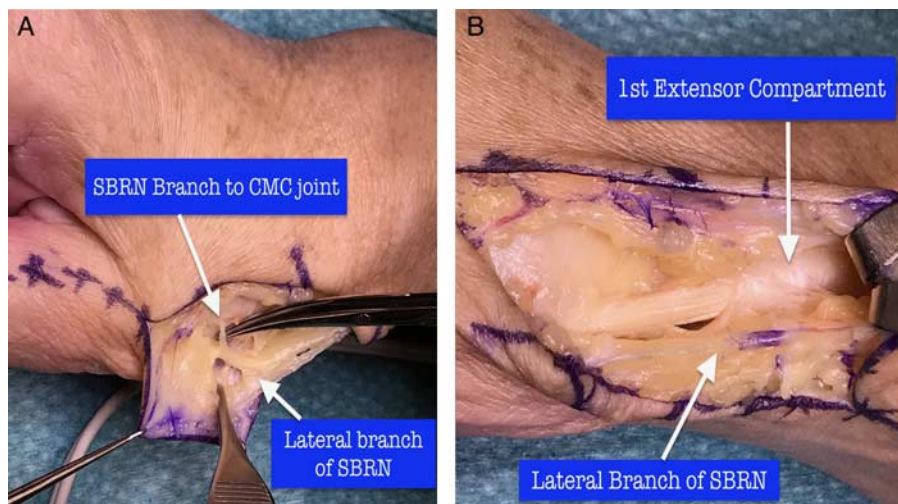
regard to its length, curvature and positioning of the transverse and longitudinal limbs.

**Step-2: Elevating Skin Flaps (Tent and Spread Technique)**

With the skin held under tension (stretched) between the surgeons’ thumb and fingers, an incision is made through the skin under direct vision (Fig. 2A). Loupe magnification is recommended. This safely exposes the superficial layer of the subcutaneous fat. Once fat is exposed, skin hooks are used to lift-up the skin flaps in a tent manner (Fig. 2B). Blunt dissection along the longitudinal line of the cutaneous nerves helps spread the fatty tissue (Fig. 2C). This helps isolate the cutaneous nerve branches which can then be safely retracted. Transverse veins that come in the way of the approach are cauterized or ligated and longitudinal cephalic vein branches are retracted. The plane of deeper dissection is through the first extensor compartment. The medial branch of the radial cutaneous nerve and its distal branches are protected within the subcutaneous fat that is retracted in the dorsal direction. The lateral branch of the radial cutaneous nerve to the radial side of the thumb is in close proximity to the first extensor compartment. This branch is more liable to injury and it is hence carefully dissected and mobilized palmarward safely away from deeper fascia. Mobilizing this branch away from the first extensor compartment helps easy identification throughout the procedure and also at the time of skin closure. At times, a small branch to the carpometacarpal (CMC) joint of the thumb is encountered and this can be neurectomized with electrocautery to improve safe retraction of the lateral branch of the SBRN (Fig. 3A). However, care must be taken to cauterize this branch closer to the joint (further away from the lateral branch) to avoid inadvertent electrocautery injury to the lateral branch (Fig. 3B).

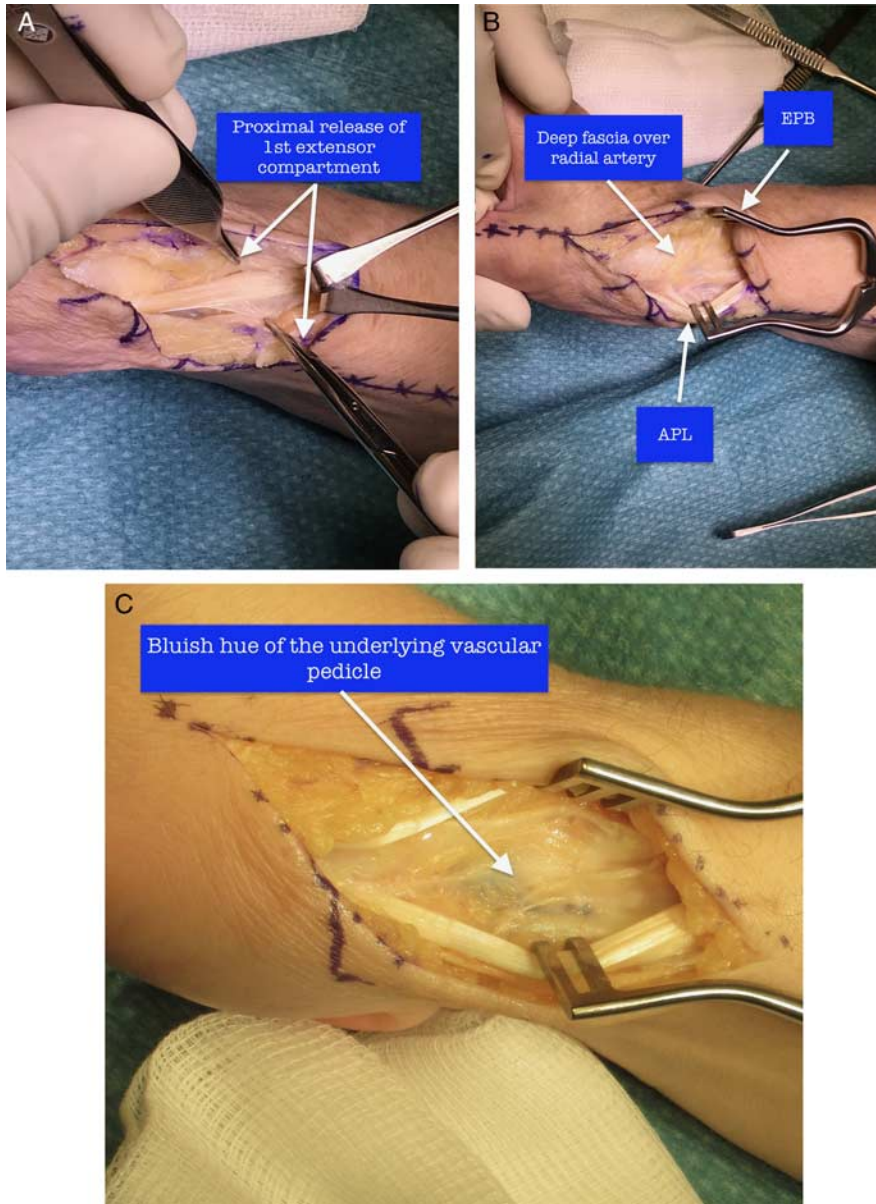
**Step-3: First Extensor Compartment Release (De Quervain’s Release)**

Incise the sheath over first extensor compartment in a distal to proximal manner (Fig. 4A). Perform a proximal release of the retinaculum in the radial styloid region (as for a De Quervain’s release). Elevate skin flaps along with the superficial branches of the radial nerve to enable proximal release the first extensor retinaculum under direct vision. Look for and release EPB



**FIGURE 3.** A, SBRN branch to CMC joint. B, First extensor compartment and lateral branch of SBRN. SBRN indicates superficial branch of the radial nerve. [full color online](#)





**FIGURE 4.** A, First extensor compartment release. B, Fascia over vascular pedicle. C, Bluish vascular hue under the fascia. APL indicates abductor pollicis longus; EPB, extensor pollicis brevis. full color online

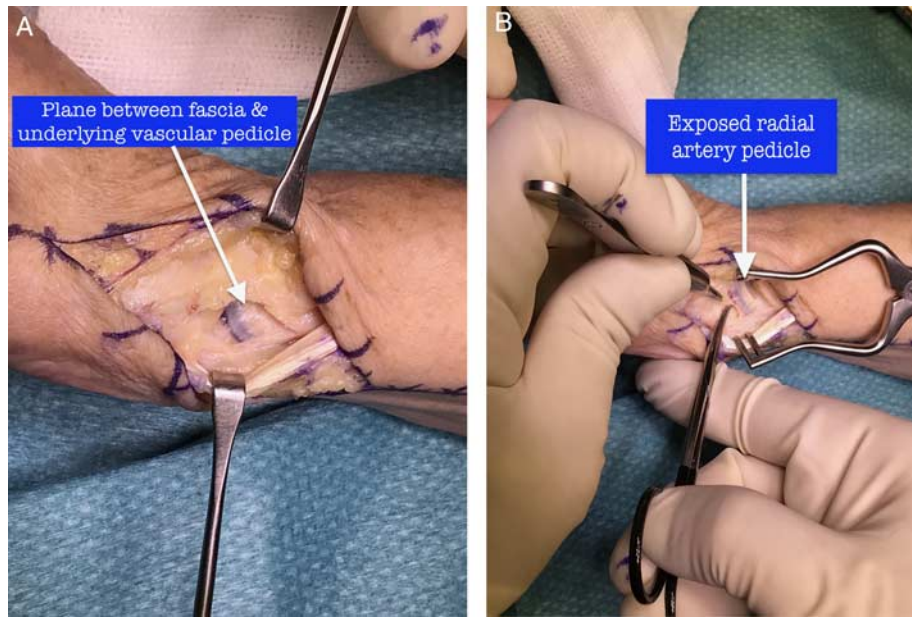
which can be in a separate compartment. Retraction of the tendons of APL palmarly and EPB dorsally protects the palmar and dorsal radial cutaneous branches on either side and exposes the deep fascia overlying the radial artery (Fig. 4B). Self-retaining retractors with blunt prongs are useful to help with steady retraction.

#### Step-4: Mobilizing the Radial Artery and Venae Comitantes (Mobilize Vascular Pedicle With a Soft Tissue Sleeve)

The deep fascial layer covering the radial artery pedicle separates the tendons in the first extensor compartment from the vascular pedicle. If an Esmarch bandage has not been used to exsanguinate the limb before tourniquet inflation, the bluish hue from the underlying vascular pedicle is visible through the fascia (Fig. 4C).

A small segment of the fascia, away from the region of the vascular pedicle, is pinched with forceps and a small opening is made with a scalpel. Create a plane between the fascia and the underlying vascular pedicle by careful blunt dissection through the fascial incision. Insert a blunt McDonald dissector under the fascia to protect the vascular pedicle when the fascia is being incised.

The fascia is then incised in a longitudinal direction, either with a scalpel or a scissors, to expose the underlying radial artery pedicle in the anatomic snuff box (Fig. 5A). The pedicle is then mobilized and protected. The radial artery has multiple branches both proximally and distally. Most of the time, retraction of the vascular pedicle is in the proximal direction and hence the distal branches are cauterized or ligated depending on the size of the branches. Blunt dissection is performed along the longitudinal axis of the vascular pedicle



**FIGURE 5.** A, Fascia is incised to expose the vascular pedicle. B, Dissecting vascular pedicle with a soft tissue cuff. [full color online](#)

(Fig. 5B). Avoid skeletonizing the vascular pedicle and always leave a sleeve of soft tissue along the pedicle to prevent inadvertent damage to the venae comitantes that could easily get damaged during dissection. Aim to develop a plane just over the capsule so as to lift the vascular pedicle in its soft tissue cuff away from the joint capsule. Inserting a vascular retraction sling helps lift the pedicle up and away from the capsule enabling an easier deep dissection. Retraction of the radial artery pedicle with two vascular slings safely exposes the underlying capsule thereby providing access to the bony structures extending from the thumb CMC joint to the radial styloid (Fig. 6A).

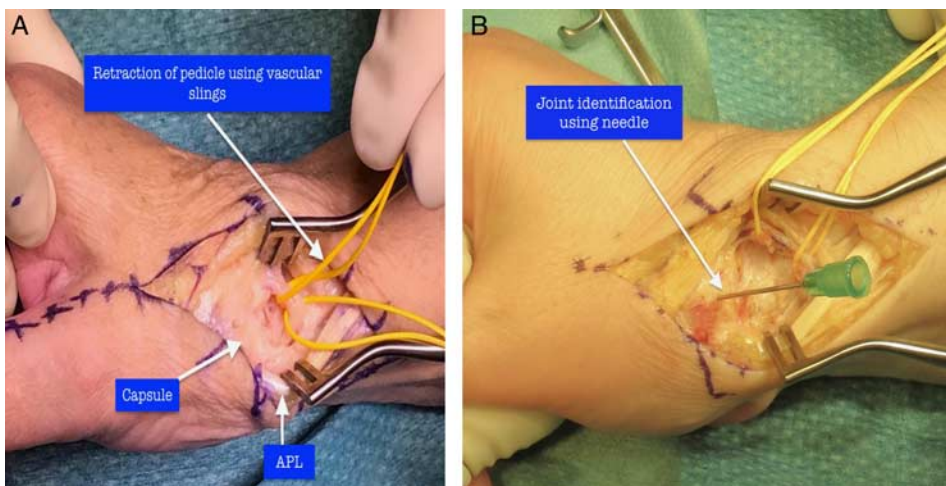
**Step-5: Longitudinal Capsulotomy (Thick Capsuloperiosteal Flaps)**

This approach provides exposure of the thumb CMC, scaphotrapezotrapezoid and radial styloid overlying the radio scaphoid joints. The joints can be identified using a needle or an image

intensifier (Fig. 6B). A capsulotomy with thick capsuloperiosteal flaps (Fig. 7A) is then made to expose the intended joint. We prefer a longitudinal capsulotomy to enable a secure repair. However, capsular incisions can be transverse, T-shaped, or fashioned to create a capsular flap for an interposition. Thick capsular flaps enable a secure repair (Fig. 7B). Avoid sharp pronged retractors and excessive retraction to prevent the capsular layer from tearing. Following the intended procedure, the capsule is closed and the vascular slings are removed. We do not attempt to repair the first extensor compartment retinaculum and leave it open as for a DeQuervains release.

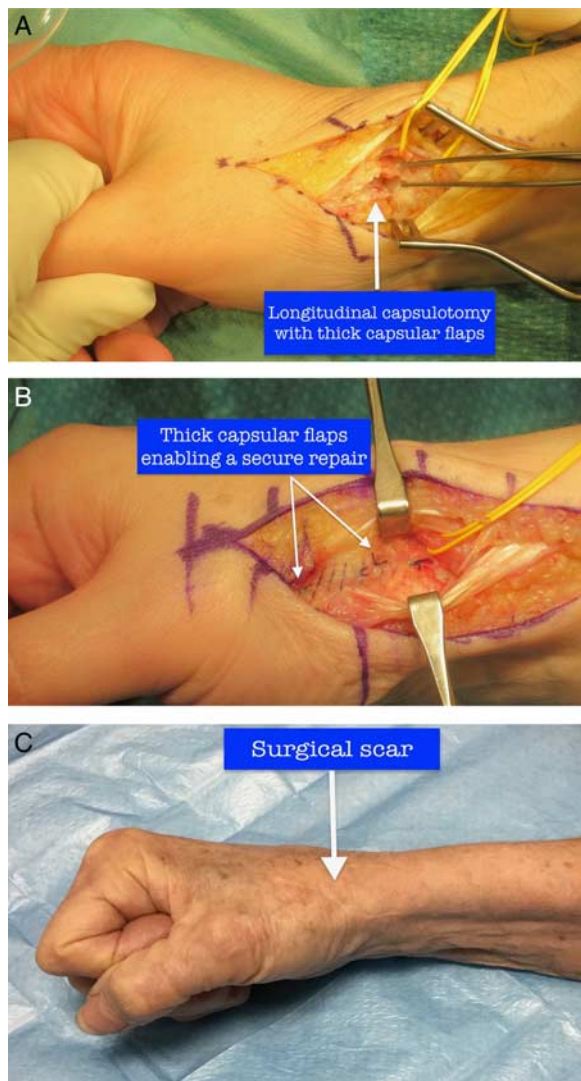
**Step-6: Skin Closure (Lift and Stitch)**

Skin closure can be performed in the way the surgeon prefers. However, meticulous care should be taken to avoid catching the branches of the SBRN when the skin and subcutaneous suture bites are taken. Lifting the skin flaps with a forceps, away from



**FIGURE 6.** A, Radial artery pedicle secured with vascular slings (yellow color). B, Joint identification using a needle. [full color online](#)





**FIGURE 7.** A, Thick capsular flaps. B, Secure capsular repair. C, Well-healed surgical scar. [full color online](#)

the underlying SBRN branches, while taking suture bites helps avoid this problem. This is more so with bites through the palmar skin flap which is intimately close to the lateral branch of the SBRN. The curved surgical scars in this area heal well with good cosmesis (Fig. 7C).

### DISCUSSION

Safe surgical approaches to the thumb base, radial aspect of the carpus, and radial aspect of the distal radius are important in elective and trauma surgery.<sup>18,19</sup> Detailed knowledge of the anatomy of the neurovascular structures and its variation are of importance to prevent iatrogenic complications.<sup>7,17</sup>

The extensile nature of the Link incision makes it a useful approach for various procedures in the “link zone.” Swanson et al<sup>20</sup> described an 8 cm curved longitudinal incision for silicone implant arthroplasty of the trapeziometacarpal joint. The distal limb of that incision starts 2 cm distal to the thumb CMC joint and is parallel to the EPB tendon. It then curves to the palmar side along the distal wrist crease and runs proximally on the volar

aspect parallel to the FCR tendon. As the link incision is the proximal continuation of the UCL incision, the distal limb of the incision is placed more dorsally and would hence enable a safe exposure of the dorsal area between the first and second metacarpal bases, radial artery as it enters the first dorsal interosseous muscle and the ECRL attachment to the second metacarpal base. The transverse limb of our incision can be tailored to sit over the joint that needs to be exposed. For a specific exposure of the trapeziometacarpal joint the transverse limb is placed along the distal wrist crease. However, for a more proximal and wider exposure a gentle curve of the incision from the dorsal to palmar side creates smooth skin corners and enables a wider atraumatic retraction of skin flaps. Unlike Swanson’s incision, the link incision is versatile with regard to its length, curvature, and positioning of the transverse-longitudinal limbs.

The link incision incorporates surgical principles that obtain a wide exposure and enables protection of the neurovascular structures. It is extensile both proximally (FCR incision) and distally (UCL incision) along established surgical approaches. The concept of a curved incision along Langer’s lines helps achieve better cosmesis.<sup>21</sup> Our concept of bridging the two commonly used surgical approaches enables easy understanding of this approach. The link incision is a “workhorse” incision to the radial aspect of the carpus as it is a safe and versatile approach.

### REFERENCES

- Marcuzzi A, Leigheb M, Russomando A, et al. Personal technique for wrist dorsal approach. *Acta Biomed.* 2014;85 (Suppl 2):37–45.
- Tay SC, Shin AY. Surgical approaches to the carpus. *Hand Clin.* 2006;22:421–434.
- Samarakoon LB, Lakmal KC, Thillainathan S, et al. Anatomical relations of the superficial sensory branches of the radial nerve: a cadaveric study with clinical implications. *Patient Saf Surg.* 2011;5:28.
- Standring S. *Gray’s Anatomy: The Anatomical Basis of Clinical Practice*, 41st ed. Canada: Elsevier; 2016.
- Andrew Lee PW. *Green’s Operative Hand Surgery, Fourth Edition. Plastic & Reconstructive Surgery.* USA: Elsevier; 2000;105:798.
- Poublon AR, Walbeehm ET, Coert JH, et al. The branching pattern of the superficial branch of the radial nerve: description of a third branching type. *Eur J Anat.* 2013;17:237–242.
- Robson AJ, See MS, Ellis H. Applied anatomy of the superficial branch of the radial nerve. *Clin Anat.* 2008;21:38–45.
- Warwick D, Alam M. Anatomy of the carpus and surgical approaches. *Orthop Trauma.* 2011;25:317–323.
- Gelberman RH, Panagis JS, Taleisnik J, et al. The arterial anatomy of the human carpus. Part I: the extraosseous vascularity. *J Hand Surg Am.* 1983;8:367–375.
- Gupta C, Ray B, Dsouza AS, et al. A morphological study of variations in the branching pattern and termination of the radial artery. *Singapore Med J.* 2012;53:208.
- Waitayawinyu T, Robertson C, Chin SH, et al. The detailed anatomy of the 1,2 intercompartmental supraretrinacular artery for vascularized bone grafting of scaphoid nonunions. *J Hand Surg Am.* 2008;33:168–174.
- Lee ZH, Stranix JT, Anzai L, et al. Surgical anatomy of the first extensor compartment: a systematic review and comparison of normal cadavers vs. De Quervain syndrome patients. *J Plast Reconstr Aesthetic Surg.* 2017;70:127–131.
- Gonzalez MH, Sohlberg R, Brown A, et al. The first dorsal extensor compartment: an anatomic study. *J Hand Surg Am.* 1995;20:657–660.
- Jackson WT, Viegas SF, Coon TM, et al. Anatomical variations in the first extensor compartment of the wrist. A clinical and anatomical study. *J Bone Joint Surg Am.* 1986;68:923–926.

15. Rousset P, Vuillemin-Bodaghi V, Laredo J-D, et al. Anatomic variations in the first extensor compartment of the wrist: accuracy of US. *Radiology*. 2010;257:427–433.
16. Catalano LW, Zlotolow DA, Hitchcock PB, et al. Surgical exposures of the radius and ulna. *J Am Acad Orthop Surg*. 2011;19:430–438.
17. Nayak SB, Kumar N, Aithal Padur A, et al. Variant superficial branch of radial artery along with supplementary tendons on the dorsum of the hand and their surgical implications. *Case Rep Surg*. 2016;2016:9581759.
18. Alsousou J, Bhalaik V. Anatomy and approaches of the wrist. *Orthop Trauma*. 2017;31:229–236.
19. Hagert E, Ferreres À, Garcia-Elias M. Nerve-sparing dorsal and volar approaches to the radiocarpal joint. *J Hand Surg Am*. 2010;35:1070–1074.
20. Swanson AB, deGoot Swanson G, Watermeier JJ. Trapezium implant arthroplasty: long-term evaluation of 150 cases. *J Hand Surg Am*. 1981;6:125–141.
21. Rubin LR, Langer K. On the anatomy and physiology of the skin. I. The cleavability of the cutis. *Br J Plast Surg*. 1978;31:3–8.