

## CASE REPORT

## Endovascular Treatment for Infra-inguinal Autologous Saphenous Vein Graft Occlusion Using Self Expanding Nitinol Stents

T. Yanagiuchi<sup>\*</sup>, M. Kimura, J. Shiraishi, T. Sawada

Department of Cardiology, Japanese Red Cross Kyoto Daiichi Hospital, Kyoto, Japan

**Introduction:** For patients with infra-inguinal autologous vein bypass graft occlusion, conventional open surgical repair or endovascular treatment (EVT) for native vessel occlusion have generally been performed.

**Report:** A 73 year old female with non-healing ulcer and gangrene of the left lower leg was diagnosed as having infra-inguinal autologous saphenous vein graft occlusion. In this case, surgical repair such as patch angioplasty, interposition graft, or replacement graft did not seem promising because of repeated previous infection in the polytetrafluoroethylene (PTFE) vascular prosthesis and absence of available autologous vein due to past surgery. Moreover, there was no chance of crossing the native vessel, since the proximal superficial femoral artery (SFA) had already been resected. Thus, EVT was performed for the occluded autologous vein graft, implanting multiple self expanding bare nitinol stents throughout the vein graft achieving complete revascularization, good medium term patency, and dramatically improved wound healing.

**Conclusion:** Endovascular recanalization using multiple bare stents could be an alternative treatment for infra-inguinal autologous vein graft occlusion.

© 2016 The Authors. Published by Elsevier Ltd on behalf of European Society for Vascular Surgery. This is an open access article under the CC BY-NC-ND license (<http://creativecommons.org/licenses/by-nc-nd/4.0/>).

Article history: Received 3 October 2015, Revised 29 January 2016, Accepted 3 February 2016,

**Keywords:** Autologous vein graft, Endovascular treatment, Self expanding nitinol stent, Chronic total occlusion

### INTRODUCTION

For cases of infra-inguinal autologous vein bypass graft stenosis and occlusion, conventional surgical repair such as vein patch angioplasty, interposition grafting, or jump grafting have generally been performed.<sup>1,2</sup> Recent advances in endovascular devices and techniques have gradually enabled endovascular treatment (EVT) as a feasible alternative for native vessel occlusion or critical vein graft stenosis.<sup>3</sup> However, there are few reports demonstrating the utility of endovascular revascularization for occluded vein grafts.<sup>4</sup> Moreover, there are just a few previous reports of stenting vein grafts,<sup>5,6</sup> and no articles reporting full lining of the vein graft with stents. Here, a rare case of a patient with infra-inguinal autologous vein graft occlusion who underwent successful endovascular recanalization implanting multiple self expanding bare nitinol stents throughout the vein graft with good medium-term patency is reported.

### CASE REPORT

A 73 year-old female with a 15 year history of hemodialysis presented with infection of the polytetrafluoroethylene

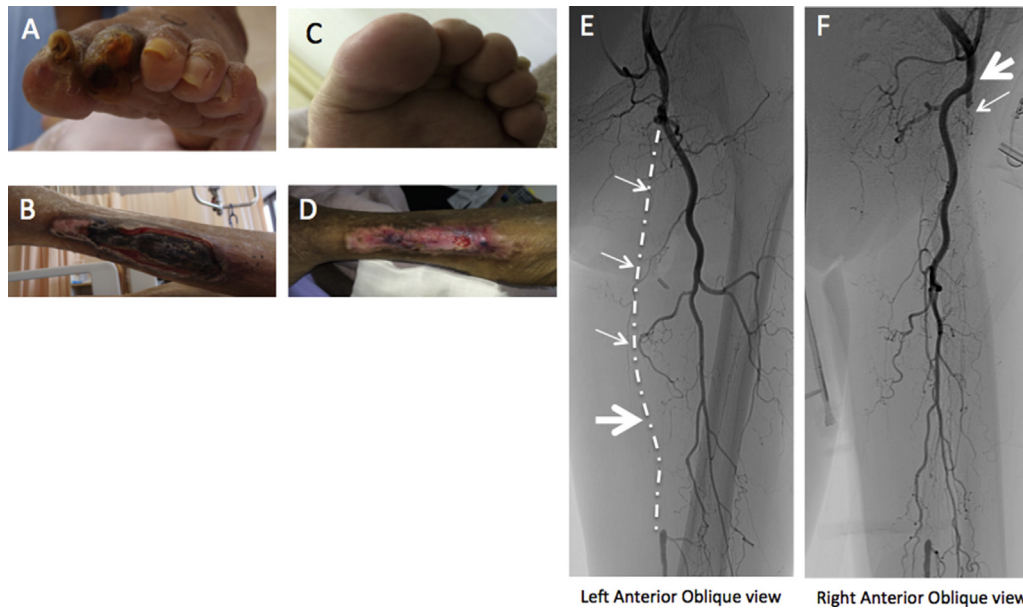
(PTFE) vascular access between the left superficial femoral artery (SFA) and the left common femoral vein (CFV). Resection of the infected graft and subsequent venous patch closure of the anastomoses was performed. Subsequently she experienced repeated pseudo-aneurysm ruptures, and underwent partial proximal SFA resection and bypass grafting using autologous saphenous vein between the common femoral artery (CFA) and the mid-SFA. Periodic graft surveillance using ultrasound detected vein graft occlusion 6 months after the operation. She was referred for treatment of her non-healing left leg ulcer 12 months after the bypass. There was gangrene of the left second toe, and an ulcer in the left lower leg overlying the fibula (Fig. 1A and B).

For diagnosis and intervention a 6F low profile sheathless guiding catheter (Parent Plus, Medikit, Lincol, UK) was inserted in the contralateral right common femoral artery. Angiography identified the resected proximal SFA and complete occlusions in the bypass graft and mid-SFA (Fig. 1E and F). The distal SFA flow was supplied by collaterals from the deep femoral artery (DFA), which appeared to be insufficient to heal the wounds. In this case, surgical repair did not seem promising, because of repeated previous infection of the PTFE vascular prosthesis and absence of an available autologous vein because of past surgery. Moreover, there was no chance of crossing the native vessel, since the proximal SFA had already been resected. Thus, it was concluded that EVT might be the only

<sup>\*</sup> Corresponding author. Department of Cardiology, Japanese Red Cross Kyoto Daiichi Hospital, Honmachi, Higashiyama-ku, Kyoto 605-0981, Japan.  
E-mail address: [takashi.yanagiuchi@gmail.com](mailto:takashi.yanagiuchi@gmail.com) (T. Yanagiuchi).

2405-6553/© 2016 The Authors. Published by Elsevier Ltd on behalf of European Society for Vascular Surgery. This is an open access article under the CC BY-NC-ND license (<http://creativecommons.org/licenses/by-nc-nd/4.0/>).

<http://dx.doi.org/10.1016/j.ejvssr.2016.02.001>



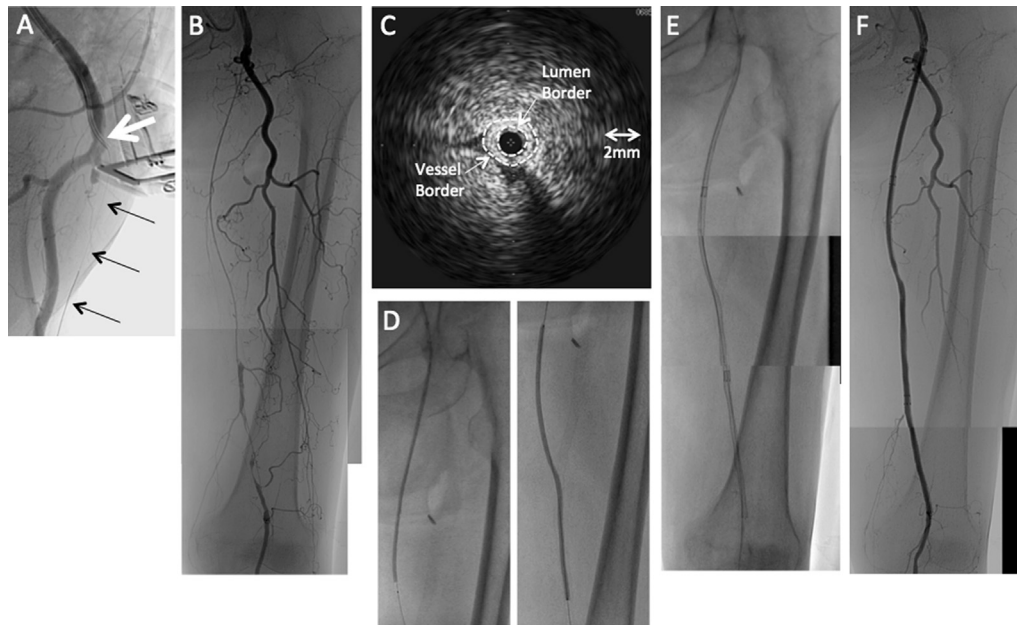
**Figure 1.** (A,B) Non-healing gangrene of the left second toe, and an ulcer in the left lower leg overlying the fibula, after occlusion of the infra-inguinal autologous saphenous vein graft. (C,D) The ulcer and gangrene have gradually healed after endovascular treatment. (E) Baseline angiography showed occlusion of the common femoral to mid superficial femoral artery (SFA) bypass graft (small arrow) and the distal arterial anastomosis in mid SFA (large arrow). (F) The small arrow indicates occlusion of the native SFA, and the large arrow indicates the proximal arterial anastomosis.

treatment for revascularization of the occluded autologous vein graft. A 4F intramuscular catheter, almost right angled at the tip, was used to engage the bypass graft ostium, and a 0.014 in soft hydrophilic guidewire (Chevalier Floppy, Cordis, Fremont, CA) supported by a microcatheter (Prominent, Tokai Medical Products, Kasugai, Japan) was advanced via the graft into the mid-distal SFA occlusion (Fig. 2A). Then, a 0.014 in stiff guidewire (Athlete Ruby Hard, Kaneka, Osaka, Japan) with a microcatheter that had a curved tip (CXI, 2.6F angle, Cook Medical, Bloomington, IN) successfully retrogradely penetrated the distal cap of the distal obstructed SFA lesion using multi-directional angiography (Fig. 2B). The guidewire was advanced intraluminally. Intravascular ultrasound (IVUS) showed vein graft shrinkage with no evidence of thrombus formation (Fig. 2C). The whole length of the occlusion was dilated with a balloon catheter ( $3.0 \times 150$  mm) (Fig. 2D), and then three self expanding nitinol stents (SMART,  $6 \times 80$  mm,  $6 \times 100$  mm,  $6 \times 150$  mm, Cordis) were consecutively implanted from the distal SFA to the distal CFA throughout the vein graft (Fig. 2E). These stents were subsequently post-dilated with a balloon catheter ( $4.0 \times 150$  mm). The final angiogram showed excellent recanalization of the bypass graft without distal embolization (Fig. 2F). After the revascularization, peripheral angiography and duplex ultrasonography identified sufficient expansion of the nitinol stents, and the left ankle brachial index increased from 0.55 to 1.13. The ulcer and gangrene gradually healed with the assistance of intensive wound care, and the treated vessel has remained patent with no further intervention for 15 months (Fig. 1C and D).

## DISCUSSION

Previous studies have reported that endovascular revascularization of critical infra-inguinal vein graft stenosis appeared to be safe and associated with acceptable early and medium-term patency rates, which were equivalent to open surgical repair.<sup>3,7,8</sup> In contrast, there have been very few studies that demonstrate the utility of endovascular therapy for occluded vein bypass grafts, which might lead to thrombus embolization.<sup>4</sup> In this case, given the IVUS images of vein graft shrinkage with no evidence of thrombus formation, the endovascular procedure was performed without distal protection. In cases with a high risk of distal embolization, distal protection devices might be considered.

It is also notable that self expanding bare nitinol stents were implanted throughout the vein graft. The clinical usefulness of stenting in infra-inguinal vein grafts is not yet established, and its safety and efficacy remain unclear. The bailout use of stents has chiefly been reported when balloon angioplasty fails. Mathur et al.<sup>5</sup> reviewed 18 implantations of bare and covered stents in infra-inguinal vein grafts after failure of EVT for treating graft stenosis, and reported a high overall technical success rate and primary patency rate at 1 year. Primary stenting for vein grafts used in the peripheral circulation has also been reported. Controneo et al.<sup>6</sup> described primary stent placement at the distal anastomotic stenosis in 21 patients and reported primary, assisted primary, and secondary patency rates at 1 year of 71%, 81%, and 86% respectively. In the present case, it was predicted that the residual stenosis in the arterial outflow including the mid-distal SFA, as well as severe shrinkage of the vein graft, might lead to insufficient flow



**Figure 2.** (A) 0.014 in hydrophilic soft guidewire (small arrow) supported by a 4F internal mammary artery (IMA) diagnostic catheter (large arrow) was advanced into the occluded bypass graft. (B) The occlusion was crossed successfully. (C) Intravascular ultrasound showed vein graft shrinkage with no evidence of thrombus formation. (D) Serial dilatation of the occluded graft and mid-superficial femoral artery with a 3.0 × 150 mm balloon catheter. (E) Implantation of three self expanding nitinol stents (6 × 80 mm, 6 × 100 mm, 6 × 150 mm). (F) Completion angiogram showed excellent revascularization of the bypass graft.

and vein graft re-occlusion. Therefore, the diseased segment, including the mid-distal SFA, the vein graft, and the CFA were fully covered with multiple stents in order to achieve the initial success. Although in this case patency has been maintained for 15 months, there are no available data concerning initial technical success rates and long-term results of full length lining of vein grafts with stents.

To avoid the risk of vessel rupture, covered stents might be suitable for relining of the whole graft. In the present case, however, it was considered that the implantation of covered stents at the proximal anastomosis might lead to occlusion of the DFA. In addition, the patient had a history of repeated infection in the groin, and it was predicted that the incidence of infection with covered stents might be higher than that of bare metal stents. Indeed, there are few reports regarding infection of bare metal stents in the peripheral vasculature. Since a report by Chalmers et al.<sup>9</sup> in 1993 of a case of arteritis following placement of a Palmatz stent (Cordis) in the right common iliac artery (CIA), only a few case reports of peripheral bare metal stent infections have been published over the past 20 years.<sup>9,10</sup> Moreover, covered stents for the treatment of peripheral artery disease have not been approved in Japan. Thus, bare metal stents, to entirely cover the diseased segments, were used first. When there is vessel rupture due to bare metal stent implantation, additional covered stent usage might be necessary to treat the rupture.

## CONCLUSION

The present case suggests that endovascular recanalization using multiple self expanding bare nitinol stents could be an

additional treatment option for infra-inguinal autologous vein bypass graft occlusion.

## CONFLICT OF INTEREST

None.

## FUNDING STATEMENT

None.

## REFERENCES

- Gonsalves C, Bandyk DF, Avino AJ, Johnson BL. Duplex features of vein graft stenosis and the success of percutaneous transluminal angioplasty. *J Endovasc Surg* 1999;**6**:66–72.
- Avino AJ, Bandyk DF, Gonsalves AJ, Johnson BL, Black TJ, Zwiebel BR. Surgical and endovascular intervention for infrainguinal vein graft stenosis. *J Vasc Surg* 1999;**29**:60–70.
- Mofidi R, Flett M, Nagy J, Ross R, Griffiths GD, Chakraverty S, et al. Balloon angioplasty as the primary treatment for failing infrainguinal vein grafts. *Eur J Vasc Endovasc Surg* 2009;**37**:198–205.
- Kawarada O, Sakamoto S, Harada K, Ishihara M, Yasuda S, Ogawa H. Endovascular recanalization of failed distal bypass in Burger's disease. *Cardiovasc Interv Ther* 2014;**29**:266–9.
- Mathur K, Ayyappan MK, Hodson J, Hopkins J, Duddy MJ, Tiwari A, et al. Stenting as a bail-out option after failed percutaneous transluminal angioplasty in infrainguinal vein bypass grafts. *Vascular* 2015. <http://dx.doi.org/10.1177/1708538115602835>.
- Controneo AR, Iezzi R, Quintero F. Assisted patency with primary stent placement in distal anastomotic stenoses of lower limb bypass grafts. *J Vasc Interv Radiol* 2007;**18**:25–30.
- Hagino RT, Sheehan MK, Jung I, Canby ED, Suri R, Toursarkissian B. Target lesion characteristics in failing vein

- grafts predict the success of endovascular and open revision. *J Vasc Surg* 2007;**46**:1167–72.
- 8 Perler BA, Osterman FA, Mitchell SE, Burdick JF, Williams GM. Balloon dilatation versus surgical revision of infra-inguinal autogenous vein graft stenoses: long-term follow up. *J Cardiovasc Surg* 1990;**31**:656–61.
- 9 Chalmers N, Eadington DW, Gandanhamo D, Gillespie IN, Ruckley CV. Case report: infected false aneurysm at the site of an iliac stent. *Br J Radiol* 1993;**66**:946–8.
- 10 Hogg ME, Peterson BG, Pearce WH, Morasch MD, Kibbe MR. Bare metal stent infections: case report and review of the literature. *J Vasc Surg* 2007;**46**:813–20.