

# Piebaldism: A brief report and review of the literature

Saurabh Agarwal, Amit Ojha

Department of Skin and VD, Government Medical College, Haldwani (Nainital), Uttarakhand, India

## ABSTRACT

Piebaldism is a rare autosomal dominant disorder of melanocyte development characterized by a congenital white forelock and multiple symmetrical stable hypopigmented or depigmented macules. We report a family with piebaldism affecting three successive generations and also review the literature.

**Key words:** Autosomal dominant, piebaldism, pigmentary disorder

## INTRODUCTION

Piebaldism is a rare autosomal dominant disorder characterized by the congenital absence of melanocytes in affected areas of the skin and hair due to mutations of the *c-kit* gene, which affects the differentiation and migration of melanoblasts from the neural crest during the embryonic life. Affected individuals present at birth with a white forelock and relatively stable, persistent depigmentation of skin with a characteristic distribution.

## CASE REPORT

Parents of a five-year-old boy and 21-month-old girl complained of white patches in both their children since birth. The patches were asymptomatic and had remained stable since their appearance. The examination of both children revealed large depigmented macules over the ventral part of the mid-trunk and over mid-portions of the lower extremities on the anterior aspect [Figure 1]. The shape of the depigmented macules was rhomboid. Leucotrichia was associated with the depigmented macules. Discrete, 5-15-mm, skin-colored and hyperpigmented macules were interspersed within the depigmented macules on the trunk and lower extremity (darker in the elder child). The entire back, hands and feet, upper extremity and mucosae were completely spared. A well-circumscribed white forelock in the mid-frontal region with a depigmented macule on the middle of the forehead was also seen in both children [Figure 2]. The hairs of the eyebrows

at the medial aspect were also depigmented in the younger child. The children had no obvious ocular, hearing or neurological defects. The physical and mental development was normal. There was no history of consanguinity amongst the parents. The audiograms of both the children were normal. Routine biochemical tests were also normal.

A similar pattern of depigmentation was seen in the father. There was a history of similar depigmented patches in the grandfather [Figure 3]. The rest of the family members were not involved. Both, father and grandfather had depigmented macules with leucotrichia on the lower extremity and trunk with almost similar distribution of lesions as seen in the children. White forelock in frontal region was also present. There was a history of spontaneous repigmentation (to some extent) of depigmented macules with the age in both father and grandfather.

## DISCUSSION

Piebaldism is a rare autosomal dominant disorder characterized by the congenital absence of melanocytes in affected areas of the skin and hair due to mutations of the *c-kit* gene, located on Chromosome 4q12, which affects the differentiation and migration of melanoblasts from the neural crest during the embryonic life. The *c-kit* gene encodes the cell-surface receptor transmembrane tyrosine kinase for the steel factor, an embryonic growth factor.<sup>[1]</sup> The literature contains 14 point mutations, nine

Access this article online

Website: [www.idoj.in](http://www.idoj.in)

DOI: 10.4103/2229-5178.96722

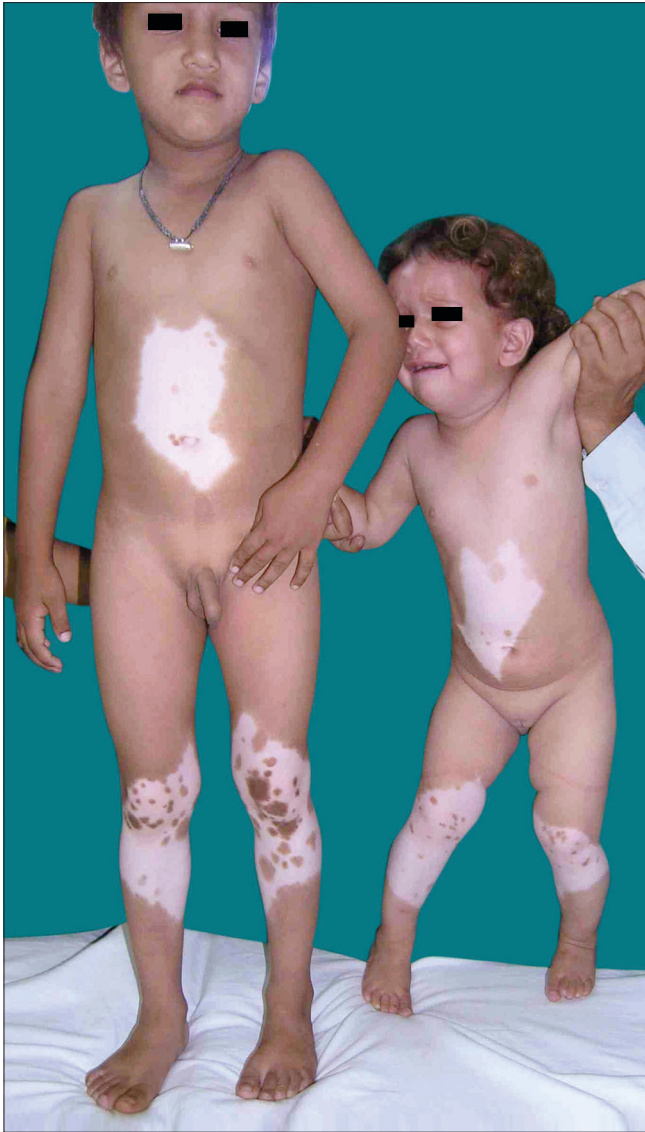Quick Response Code:



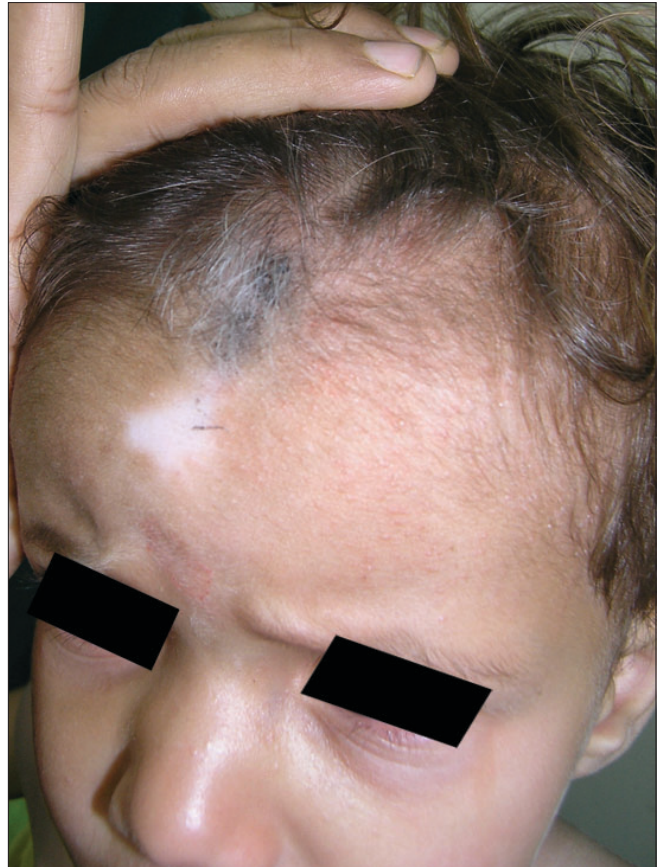### Address for

### correspondence:

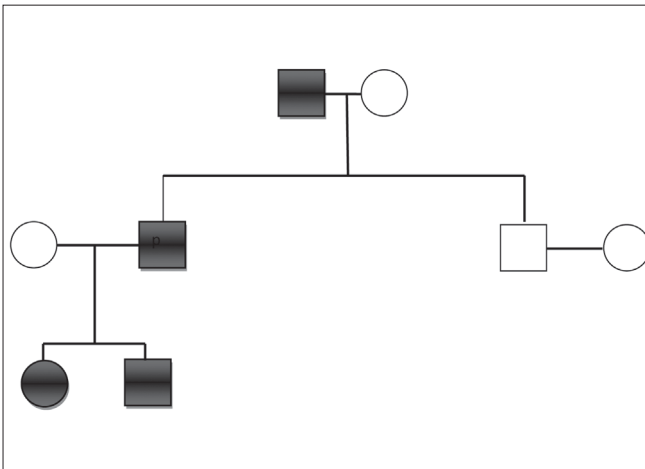
Dr. Saurabh Agarwal,  
Department of Skin  
and VD, Government  
Medical College,  
Haldwani (Nainital),  
Uttarakhand – 263 139,  
India.  
E-mail: [imsag@rediffmail.com](mailto:imsag@rediffmail.com)



**Figure 1:** Depigmentation on the trunk and mid-portion of lower extremities in two siblings. Note the islands of hyperpigmented macules within depigmentation



**Figure 2:** White forelock and depigmented macule on mid-forehead. Also note the whitening of hair of the medial one-third of eyebrows



**Figure 3:** Pedigree chart depicting the pattern of inheritance (black color represents members having piebaldism)

deletions, two nucleotide splice mutations, and three insertions of the *c-kit* gene, all causing piebaldism with a range of phenotypes.<sup>[2]</sup> In a study of 26 unrelated patients with a piebaldism-like depigmentation, 17 patients had classic lesions, five had atypical clinical features or family histories, and four had other disorders. Pathologic mutations or deletions of the *kit* gene were found in 10 (59%) of the typical patients and in two (40%) of the atypical patients. None of the patients without *c-kit* mutations had apparent abnormalities of the steel factor gene.<sup>[3]</sup>

Clinical manifestations and phenotypic severity of piebaldism strongly correlate with the site of the mutation within the *c-kit* gene. Dominant negative missense mutations of the intracellular tyrosine kinase domain appear to yield the most severe phenotypes, while mutations in the amino terminal extracellular ligand-binding domain result in haplo insufficiency and are associated with the mildest forms of piebaldism.<sup>[2]</sup> Intermediate phenotypes are seen with mutations near the transmembrane region. The classic type of static piebaldism is due to *c-kit* gene mutations in the vicinity of codon 620.

The incidence of piebaldism is estimated to be less than 1:20000. Both males and females are equally affected, and no race is spared.<sup>[4]</sup> Affected individuals present at birth with a

relatively stable and persistent depigmentation of the hair and skin, although in a number of patients, repigmentation may occur spontaneously, either partially or completely, especially after injury.<sup>[5]</sup> A white forelock of hair arising from a triangular, elongated or diamond-shaped, midline, depigmented macule on the forehead may be the only manifestation in 80-90% of cases.<sup>[6]</sup> Eyebrows and eyelashes may also be affected. The characteristic distribution of depigmented macules includes central macule on forehead with white forelock, anterior abdomen extending to the chest, the lateral trunk sparing the dorsal spine, the mid-arms and legs sparing the hands, and feet.<sup>[4]</sup> Depigmented macules are rectangular, rhomboid or irregular in shape and usually have a symmetrical distribution. Typically, islands of hyperpigmentation are present within and at the border of depigmented areas.<sup>[4]</sup>

Melanocytes are absent or considerably reduced in depigmented patches histologically and ultrastructurally. They are normal in number in the hyperpigmented areas. Other conditions characterized by depigmentation of hair and skin need to be considered, in particular albinism and vitiligo, which may be congenital [Table 1]. Albinism is another congenital genetically inherited disorder, but is characterized by partial or complete absence of melanin production in the skin, hair and eyes. Vitiligo may rarely be present at birth, but is usually acquired later in life, is unstable and is not genetically inherited, although it may

run in some families. The appearance of depigmented macules since birth, presence of white forelock in the frontal region, typical distribution of depigmented macules, their relative stability since the time of appearance and presence of a similar pattern of depigmented macules in other family members make the diagnosis of piebaldism easier.

Pigmentary anomalies in piebaldism are typically restricted to the hair and skin. However, rare associations have been reported with piebaldism, in particular Hirschprung's disease or aganglionic megacolon, supporting evidence of a network of interacting genes and proteins for the regulation of melanocytes and enteric plexus neurons during their development at the time of embryogenesis.<sup>[7]</sup> Neurofibromatosis Type I was associated with piebaldism on a few occasions.<sup>[8,9]</sup> A piebald patient with congenital dyserythropoietic anemia Type II (HEMPAS) and a patient with Diamond-Blackfan anemia have been reported.<sup>[10,11]</sup> Grover's Disease or transient acantholytic dermatosis limited to the depigmented macules in a piebaldism patient has been described.<sup>[12]</sup>

A number of syndromes associate piebald-like hypopigmentation of the skin and hair with other anomalies, but are not associated with anomalies of the kit gene. Waardenburg's syndrome, an autosomal dominant disorder is characterized by a congenital white forelock, lateral displacement of the medial canthi, a

**Table 1: Comparative features of Piebaldism, Vitiligo, Albinism and Waardenburg's syndrome**

	<b>Piebaldism</b>	<b>Vitiligo</b>	<b>Albinism</b>	<b>Waardenburg's syndrome</b>
Age of onset	Birth	Acquired at any age; rarely congenital	Birth	Birth
Course	Chronic, stable	Chronic, usually progressive	Chronic, stable	Chronic, stable
Color	Milk-white	Milk-white	Hypopigmentation to Milk-white	Milk-white
Size/shape	Few to several centimeters, irregular	Millimeter to centimeters; round, scalloped margins	Diffuse hypo/depigmentation	Few to several centimeters
Distribution	Central forehead with white forelock, mid-trunk sparing dorsal spine, mid-arms/legs sparing hands/feet	Symmetrical, periorificial, extensor limbs/digits, periungual	Generalized	Face, neck, trunk, dorsal limbs
Special features	Hyperpigmented macules in white macules	Trichrome pattern; segmental distribution	May develop nevi, freckles, lentigenes	None
Other skin changes	Poliosis	Scattered poliosis, halo nevi, alopecia areata	White hair	White forelock, eyebrow hyperplasia
Extracutaneous	None	Hypo/hyperthyroidism, diabetes mellitus	Nystagmus, iris translucency, foveal hypoplasia, reduced visual acuity	Heterochromic irides, broad nasal root, deafness
Histology of white macule	Melanocytes absent, spherical melanosomes in hyperpigmented macules	Melanocytes absent, lymphocytes in active lesions	Normal number and structure of melanocytes; genetic abnormality of melanin synthesis	Melanocytes absent
Major diagnostic clues	White forelock, autosomal dominance, typical pattern	Acquired nature, typical patterns	Characteristic changes in the development and function of eye and optic nerve with diffuse hypopigmentation; autosomal recessive	Cluster or partial cluster of typical features in patient with poliosis, deafness and a positive family history

hypertrophic nasal root, partial or total heterochromia of the iris and sensorineural deafness [Table 1]. All anomalies of Waardenburg's syndrome involve the neural crest from which are derived not only melanocytes, but also gut enteric plexus ganglion cells and other neural tissue as well as connective tissue of the head and neck.<sup>[13,14]</sup> Ziprkowski and Margolis in 1962 described an X-linked recessive disorder characterized by hypomelanosis, deafness and mutism in a Jewish Israeli family of Sephardic origin.<sup>[15]</sup> It has now been included in the albinism-deafness syndrome (ADFN) and the gene has been localized to Xq24-q26 but not identified.<sup>[16]</sup> Woolf first reported piebaldism, in association with congenital deafness, in 1965 in two Hopi Indian brothers in Arizona.<sup>[17]</sup> The Tietz syndrome was first described as a congenital generalized depigmentation and profound congenital sensorineural deafness, transmitted as an autosomal dominant trait with full penetrance, and attributed to a mutation in the microphthalmia-associated transcription factor (MITF) gene in descendants of the same family.<sup>[18]</sup>

Treatment is a challenge. A combination of dermabrasion and grafting of pigmented skin into depigmented areas, with or without phototherapy, may be worthwhile in selected patients. Depigmented areas may be treated with thin split-thickness grafts and minigrafting or with *in vitro* cultured epidermis and suction epidermal grafting with additional minigrafting.<sup>[19]</sup> All patients with piebaldism had excellent repigmentation with transplantation. Grafts of epidermal sheets were found to be technically easier and to yield the best results, except on the elbow and arms. Phototherapy alone has little effect, but is helpful after transplantation. Recently, transplant of autologous melanocytes obtained through the culture of melanocytes or of melanocytes and keratinocytes has been described as a safe and effective treatment for patients with piebaldism.<sup>[20,21]</sup> This induced scarless repigmentation using a small donor site. After these procedures, phototherapy can be used.

## REFERENCES

1. Spritz RA. Molecular basis of human piebaldism. *J Invest Dermatol* 1994;103(Suppl 5):137S-40S.
2. Richards KA, Fukai K, Oiso N, Paller AS. A novel KIT mutation results in piebaldism with progressive depigmentation. *J Am Acad Dermatol* 2001;44:288-92.
3. Ezoe K, Holmes SA, Ho L, Bennett CP, Bologna JL, Brueton L, *et al.* Novel mutation and deletions of the KIT (steel factor receptor) gene in human piebaldism. *Am J Hum Genet* 1995;56:58-66.
4. Ortonne JP, Bahaderan P, Fitzpatrick TB, Mosher DB, Hori Y. Hypomelanosis and Hypermelanosis. In: Fitzpatrick TB, Freedberg IM, Eisen AZ, Wolff K, Austen KF, Goldsmith LA, *et al.* editors. *Dermatology in General Medicine* 6<sup>th</sup> ed. New York; McGraw-Hill; 2003. p. 836-81.
5. Fukai K, Hamada T, Ishii M, Kitajima J, Terao Y. Acquired pigmented macules in human piebald lesions. Ultrastructure of melanocytes in hypomelanotic skin. *Acta Derm Venereol* 1989;69:524-7.
6. Ward KA, Moss C, Sanders DS. Human piebaldism: Relationship between phenotype and site of kit gene mutation. *Br J Dermatol* 1995;132:929-35.
7. Mahakrishnan A, Srinivasan MS. Piebaldism with Hirschsprung's disease. *Arch Dermatol* 1980;116:1102.
8. Angelo C, Cianchini G, Grosso MG, Zambruno G, Cavaliere R, Paradisi M. Association of piebaldism and neurofibromatosis type I in a girl. *Pediatr Dermatol* 2001;18:490-3.
9. Duarte AF, Mota A, Baudrier T, Morais P, Santos A, Cerqueira R *et al.* Piebaldism and neurofibromatosis type I: family report. *Dermatol Online J* 2010;16:11.
10. Koklu S, Ertugrul D, Onat AM, Karakus S, Hazhedaroque IC, Buegukasik Y, *et al.* Piebaldism associated with congenital dyserythropoietic anemia type II (HEMPAS). *Am J Hematol* 2002;69:210-3.
11. Costa LD, Fixler J, Berets O, Leblanc T, Williq TN, Mohandas N, *et al.* Piebaldism in Diamond-Blackfan anaemia: A new phenotype? *Br J Haematol* 2002;119:572.
12. Kiwan RA, Mutasim DF. Grover disease (transient acantholytic dermatosis) and piebaldism. *Cutis* 2002;69:451-3.
13. Janjua S, Khachemoune A, Guldbakke KK. Piebaldism: A case report and a concise review of the literature. *Cutis* 2007;80:411-4.
14. Read AP, Newton VE. Waardenburg's syndrome. *J Med Genet* 1997;34:656-665.
15. Ziprkowski L, Krakowski A, Adam A, Costeff H, Sade J. Partial albinism and deaf-mutism due to a recessive sex-linked gene. *Arch Dermatol* 1962;86:530-9.
16. Shiloh Y, Litvak G, Ziv Y, Lehner T, Sandkuyl L, Hildesheimer M, *et al.* Genetic mapping of X-linked albinism-deafness syndrome (ADFN) to Xq26.3-Q27.1. *Am J Hum Genet* 1990;47:20-7.
17. Woolf C. Albinism among Indians in Arizona and New Mexico. *Am J Hum Genet* 1965;17:23-5.
18. Smith SD, Kelley PM, Kenyon JB, Hoover D. Tietz syndrome (hypopigmentation/deafness) caused by mutations of MITF. *J Med Genet* 2000;37:446-8.
19. Njoo MD, Nieuweboer-Krobotova L, Westerhof W. Repigmentation of leucodermic defects in piebaldism by dermabrasion and thin split-thickness grafting in combination with minigrafting. *Br J Dermatol* 1998;139:829-33.
20. Neves DR, Régis Júnior JR, Oliveira PJ, Zac RI, Silveira Kde S. Melanocyte transplant in piebaldism: Case report. *An Bras Dermatol* 2010;85:384-8.
21. Van Geel N, Wallaey E, Goh BK, De Mil M, Lambert J. Long-term results of noncultured epidermal cellular grafting in vitiligo, halo naevi, piebaldism and naevus depigmentosus. *Br J Dermatol* 2010;163:1186-93.

**Cite this article as:** Agarwal S, Ojha A. Piebaldism: A brief report and review of the literature. *Indian Dermatol Online J* 2012;3:144-7.

**Source of Support:** Nil, **Conflict of Interest:** None declared.