

Asymmetric pattern in generalized myasthenia gravis

A case report

Thiago Pereira de Carvalho, MD^{a,b}, Clara Louise Vianna, MD^a, Felipe Freitas Andrade, BS^b, Rafaela Abreu Alvarenga, BS^b, Liz de Oliveira Moura Sales, BS^b, Rosana Souza Rodrigues, MD, PhD^{c,d}, Paulo Henrique Rosado-de-Castro, MD, PhD^{c,*}

Abstract

Rationale: Myasthenia gravis (MG) is an uncommon autoimmune disease mediated by antibodies that attack the postsynaptic acetylcholine receptors (AChRs) at the neuromuscular junction, causing fluctuating muscle weakness, aggravated with use, and relieved with rest.

Patient concerns: A 32-year-old woman with a diagnosis of MG based on clinical findings, electroneuromyography, and brain magnetic resonance imaging (MRI) was admitted to our hospital with dysphagia, dysphonia, diplopia, and intense weakness, associated with a 2-day viral gastroenteritis.

Diagnoses: Physical examination revealed globally reduced deep tendon reflexes, and tetraparesis, with muscle strength grade 4 in the left limbs and grade 2 in the right limbs. Autoantibody dosing against AChR was elevated and computed tomography scan of the thorax revealed a thymic remnant.

Interventions: Pyridostigmine and human immunoglobulin were infused.

Outcomes: After 7 days of the reintroduction of pyridostigmine and human immunoglobulin infusion, the patient developed complete resolution of symptoms, being discharged from the hospital. Her symptoms are still well controlled 6 months later. The patient was evaluated by a thoracic surgeon and is awaiting elective thymectomy.

Lessons: Although our patient presented all the diagnostic criteria of MG, the markedly asymmetric limb weakness presented in previous history and clinical examination of admission was an unusual and unexpected presentation, especially considering the pathophysiology of the disease. MRI of brain without abnormalities was fundamental to rule out another associated etiology. Our review of the literature revealed just 1 case report of MG with similar presentation. This clinical manifestation becomes valuable because it contributes to the list of unexpected presentation that should motivate its suspicion.

Abbreviations: AChR = acetylcholine receptor, anti-AChR = antibodies that attack the postsynaptic acetylcholine receptor, anti-MusK = antibody against the muscle-specific receptor tyrosine kinase, CT = computed tomography, MG = Myasthenia Gravis, MRI = magnetic resonance imaging, NMJ = neuromuscular junction.

Keywords: autoimmune disease, myasthenia gravis, neurologic disease

1. Introduction

Myasthenia gravis (MG) is an uncommon autoimmune disease mediated by antibodies that attack the postsynaptic acetylcholine

Editor: N/A.

A written informed consent was given by the patient for publication of this study and any accompanying images.

The authors have no funding and conflicts of interest to disclose.

^aAlcides Carneiro Hospital, ^bPetrópolis School of Medicine/ Arthur Sá Earp Neto Faculty, Petrópolis, ^cFederal University of Rio de Janeiro, ^dD'Or Institute for Research and Education, Rio de Janeiro, Brazil.

* Correspondence: Paulo Henrique Rosado-de-Castro, Avenida Carlos Chagas Filho 373, Ilha do Fundão. Rio de Janeiro, CEP 21941-902, Brazil (e-mail: phrosadodecastro@ufrj.br).

Copyright © 2018 the Author(s). Published by Wolters Kluwer Health, Inc. This is an open access article distributed under the terms of the Creative Commons Attribution-Non Commercial-No Derivatives License 4.0 (CCBY-NC-ND), where it is permissible to download and share the work provided it is properly cited. The work cannot be changed in any way or used commercially without permission from the journal.

Medicine (2018) 97:49(e13460)

Received: 30 July 2018 / Accepted: 5 November 2018

<http://dx.doi.org/10.1097/MD.0000000000013460>

receptors (AChRs) at the neuromuscular junction (NMJ), causing fluctuating muscle weakness aggravated with use and relieved with rest. Its 2 main forms are ocular, which is restricted to the eyelid and extraocular musculature and may be asymmetrical, and the generalized form, in which there is also involvement of the bulbar, respiratory muscles, and limbs in varying degrees, but maintains the symmetry of the affected site.^[1] In this report, we describe a patient that was admitted with generalized reduction of force, but with an exuberant asymmetry between the body sides, being predominant in the left. The clinical history and the complementary examinations allowed the diagnostic confirmation of MG and an adequate therapeutic management.

2. Case report

A 32-year-old woman presented with dysphagia, dysphonia, diplopia, and intense weakness, most evident in the left side of the body, concomitant with noninflammatory diarrhea, nausea, and vomiting, without fever or abdominal pain. She reported a diagnosis 1 year before of MG based on clinical history (dysphagia, dysphonia, diplopia, and palpebral ptosis, more intense throughout the day and always with an exuberant predominance in left arm and leg), electroneuromyography




Figure 1. Accessory (A), right ulnar (B), left median (C), and left tibial (D) repetitive nerve stimulation show a reduction >10% of the muscular action potential with the repetition of the stimulus.

(Fig. 1), and normal magnetic resonance imaging (MRI) of the brain. She denied any other comorbidity. The symptoms were controlled with pyridostigmine and prednisone.

Physical examination revealed right palpebral ptosis with isochoric and photoreactive pupils, globally reduced deep tendon reflexes, and tetraparesis, with muscle strength grade 4 in the left limbs and grade 2 in the right limbs. The rest of the clinical examination was unchanged.

Levels of serum anti-acetylcholine receptors (anti-AChRs) were increased (>20 nmol/L), while levels of thyroid hormone and muscle enzymes showed no abnormalities. A chest computed tomography (CT) showed a thymic remnant (Fig. 2). After reviewing previous examinations, evaluating the clinical history, and hospitalization examinations, we doubled the dose of pyridostigmine via nasogastric catheter and administered human immunoglobulin for 5 days. After 72 hours of treatment, the patient presented significant improvement, being discharged 7 days later with significant symptoms improvement (Fig. 3) with pyridostigmine 600 mg/d, prednisone 10 mg/d, and azathioprine 100 mg/d, and was referred for ambulatory follow-up. Her symptoms are still well controlled 6 months later. The patient was

evaluated by a thoracic surgeon and is awaiting elective thymectomy.

3. Discussion

We report an uncommon presentation of MG, an autoimmune disease associated with impairment of neuromuscular transmission, due to an immunomediated reaction against postsynaptic membrane proteins of the NMJ. Clinically, it may present as ocular MG, restricted to ocular and extraocular musculature, and generalized, affecting other muscle groups. In both forms, there is a marked fluctuation of skeletal muscle strength, which can lead to fatigue of muscle groups, which is reflected in the clinical manifestation: diplopia and palpebral ptosis (ocular), dysarthria, dysphagia and weak mastication (bulb), and involvement of proximal musculature, with greater expression in the hands (limbs).^[1]

The diagnosis of MG is based on clinical history, physical examination, serologic examination, and electrophysiologic studies (study of repetitive nerve stimuli and single fiber electroneuromyography). The serologic test consists of the

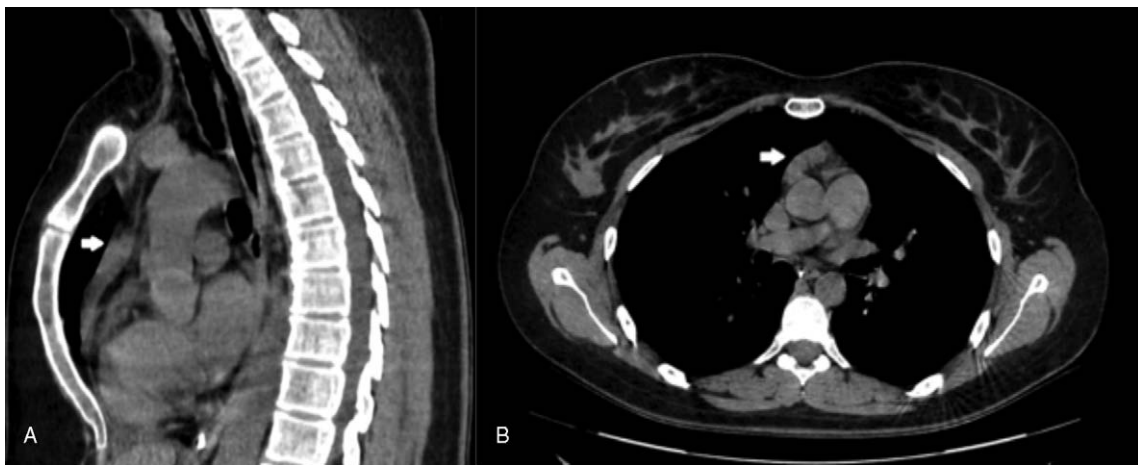


Figure 2. Axial (A) and sagittal (B) chest computed tomography with thymic remnant.

determination of the serum level of the anti-AChR and, especially when negative, of the antibody against the muscle-specific receptor tyrosine kinase (anti-MusK). In the ocular form, approximately 50% of the patients present negative anti-AChR dosages, while in the generalized form, 85% have high titles.^[1] On the contrary, anti-MusK is present in 38% to 50% of MG carriers with anti-AChR negative.^[2]

The last step in the diagnosis of MG is electrophysiologic studies. In the study of repetitive nerve stimulation, there is a reduction of the muscular action potential with the repetition of the stimulus. In the single fiber electroneuromyography, responsible for evaluating the action potential in 2 distinct but innervated muscles by the same neuron, there is an increase in the

time variation between the action potentials of the muscles, reflecting a weak transmission.^[3]

The MG therapy includes acetylcholinesterase inhibitors (i.e., pyridostigmine), immunomodulators such as glucocorticoids and immunosuppressants (i.e., azathioprine, mycophenolate mofetil, and cyclosporine), rapid immunomodulation (i.e., plasmapheresis and intravenous immunoglobulin), and thymectomy in selected cases.^[4]

Our patient fulfilled all diagnostic criteria: clinical (worsening of symptoms throughout the day, in the presence of inflammatory interurrences, and with significant improvement with acetylcholinesterase inhibitors), laboratory (presence of high levels of anti-AChR), and electroneuromyographic (decreased amplitude

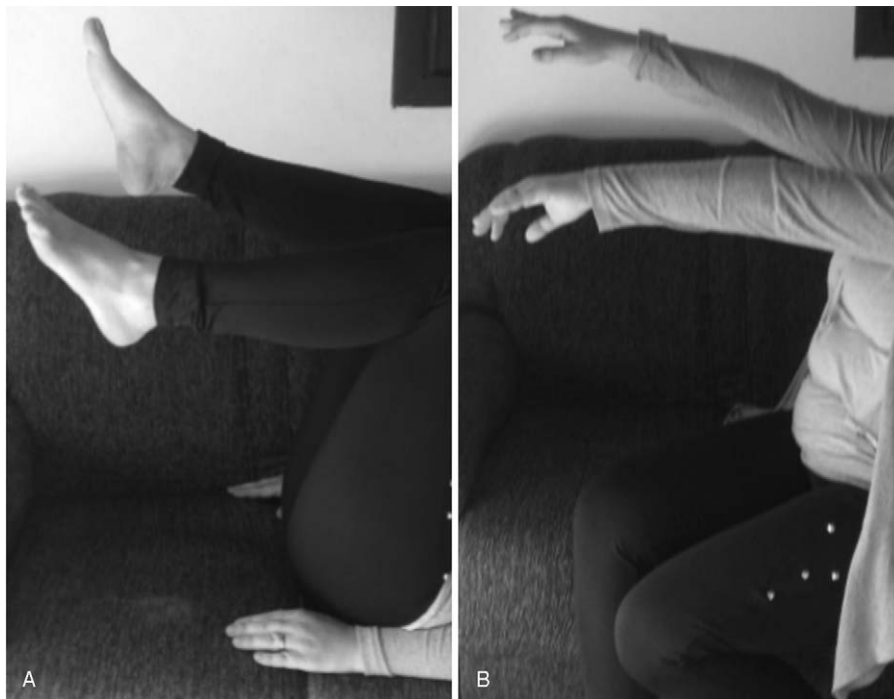

Figure 3. Mingazzini test on lower (A) and upper (B) limbs revealing evident asymmetry between right and left limbs even after recovery.

by more than 10% in electroneuromyography with repetitive stimuli). It is noteworthy that at admission, the patient presented severe symptoms of oropharyngeal involvement, which often precede the so-called myasthenic crisis, when there is a severe involvement of the respiratory muscles, implying the need for intubation for ventilatory support.^[5] The presence of thymic remnant in the chest CT caused the patient to be referred for further evaluation by a thoracic surgeon, aiming a better control of MG.^[4]

However, the markedly asymmetric limb weakness presented in previous history and clinical examination of admission was an unusual and unexpected presentation, especially considering the pathophysiology of the disease. MRI of brain without abnormalities was fundamental to rule out another associated etiology, such as ischemic insult, vasculitis, or demyelinating disease.

Our review of the literature^[6–18] on unusual forms of MG manifestation revealed just 1 case report of MG^[6] with a similar presentation even considering a large series of atypical case reports.^[7] This clinical manifestation becomes valuable because it contributes to the list of unexpected presentation that should motivate its suspicion.

Author contributions

Conceptualization: Thiago Pereira de Carvalho, Clara Louise Vianna, Felipe Freitas Andrade, Rafaela Abreu Alvarenga, Liz de Oliveira Moura Sales, Rosana Souza Rodrigues, Paulo Henrique Rosado-de-Castro

Data curation: Thiago Pereira de Carvalho, Rosana Souza Rodrigues, Paulo Henrique Rosado-de-Castro

Formal analysis: Thiago Pereira de Carvalho, Clara Louise Vianna, Felipe Freitas Andrade, Rafaela Abreu Alvarenga, Liz de Oliveira Moura Sales, Rosana Souza Rodrigues, Paulo Henrique Rosado-de-Castro

Investigation: Thiago Pereira de Carvalho, Clara Louise Vianna, Felipe Freitas Andrade, Rafaela Abreu Alvarenga, Liz de Oliveira Moura Sales, Rosana Souza Rodrigues, Paulo Henrique Rosado-de-Castro

Methodology: Thiago Pereira de Carvalho, Clara Louise Vianna, Felipe Freitas Andrade, Rafaela Abreu Alvarenga, Liz de Oliveira Moura Sales, Paulo Henrique Rosado-de-Castro

Project administration: Thiago Pereira de Carvalho, Clara Louise Vianna, Paulo Henrique Rosado-de-Castro

Resources: Thiago Pereira de Carvalho, Paulo Henrique Rosado-de-Castro

Supervision: Thiago Pereira de Carvalho, Clara Louise Vianna, Rafaela Abreu Alvarenga, Rosana Souza Rodrigues, Paulo Henrique Rosado-de-Castro

Validation: Thiago Pereira de Carvalho, Paulo Henrique Rosado-de-Castro

Visualization: Thiago Pereira de Carvalho, Rosana Souza Rodrigues, Paulo Henrique Rosado-de-Castro

Writing – original draft: Thiago Pereira de Carvalho, Clara Louise Vianna, Felipe Freitas Andrade, Rafaela Abreu Alvarenga, Liz de Oliveira Moura Sales, Paulo Henrique Rosado-de-Castro

Writing – review & editing: Thiago Pereira de Carvalho, Clara Louise Vianna, Felipe Freitas Andrade, Rafaela Abreu Alvarenga, Liz de Oliveira Moura Sales, Rosana Souza Rodrigues, Paulo Henrique Rosado-de-Castro

Conceptualization: Thiago Pereira de Carvalho, Clara Louise Vianna, Felipe Freitas Andrade, Rafaela Abreu Alvarenga,

Liz de Oliveira Moura Sales, Paulo Henrique Rosado de Castro.

Data curation: Thiago Pereira de Carvalho, Rosana Souza Rodrigues.

Formal analysis: Thiago Pereira de Carvalho, Clara Louise Vianna, Felipe Freitas Andrade, Rafaela Abreu Alvarenga, Liz de Oliveira Moura Sales, Rosana Souza Rodrigues, Paulo Henrique Rosado de Castro.

Investigation: Thiago Pereira de Carvalho, Clara Louise Vianna, Felipe Freitas Andrade, Rafaela Abreu Alvarenga, Liz de Oliveira Moura Sales, Rosana Souza Rodrigues, Paulo Henrique Rosado de Castro.

Methodology: Thiago Pereira de Carvalho, Clara Louise Vianna, Felipe Freitas Andrade, Rafaela Abreu Alvarenga, Liz de Oliveira Moura Sales, Paulo Henrique Rosado de Castro.

Project administration: Thiago Pereira de Carvalho, Clara Louise Vianna.

Resources: Thiago Pereira de Carvalho.

Supervision: Thiago Pereira de Carvalho, Clara Louise Vianna, Rosana Souza Rodrigues, Paulo Henrique Rosado de Castro.

Validation: Thiago Pereira de Carvalho.

Visualization: Thiago Pereira de Carvalho, Rosana Souza Rodrigues.

Writing – original draft: Thiago Pereira de Carvalho, Clara Louise Vianna, Felipe Freitas Andrade, Rafaela Abreu Alvarenga, Liz de Oliveira Moura Sales, Paulo Henrique Rosado de Castro.

Writing – review & editing: Thiago Pereira de Carvalho, Clara Louise Vianna, Felipe Freitas Andrade, Rafaela Abreu Alvarenga, Liz de Oliveira Moura Sales, Rosana Souza Rodrigues, Paulo Henrique Rosado de Castro.

Paulo Henrique Rosado de Castro orcid: 0000-0003-0091-9714.

References

- [1] Silvestri NJ, Wolfe GI. Myasthenia gravis. *Semin Neurol* 2012;32:215–26.
- [2] Deymeer F, Gungor-Tuncer O, Yilmaz V, et al. Clinical comparison of anti-MuSK- vs anti-AChR-positive and seronegative myasthenia gravis. *Neurology* 2007;68:609–11.
- [3] AAEM Quality Assurance Committee American Association of Electrodiagnostic Medicine. Literature review of the usefulness of repetitive nerve stimulation and single fiber EMG in the electrodiagnostic evaluation of patients with suspected myasthenia gravis or Lambert-Eaton myasthenic syndrome. *Muscle Nerve* 2001;24:1239–47.
- [4] Kim JY, Park KD, Richman DP. Treatment of myasthenia gravis based on its immunopathogenesis. *J Clin Neurol* 2011;7:173–83.
- [5] Bedlack RS, Sanders DB. On the concept of myasthenic crisis. *J Clin Neuromuscul Dis* 2002;4:40–2.
- [6] Ong BK, Chong PN. Acute hemiparesis with hemichorea and crossed hemiparesis; unusual presentation for myasthenia gravis. *Singapore Med J* 1993;34:60–1.
- [7] Rodolico C, Parisi D, Portaro S, et al. Myasthenia gravis: unusual presentations and diagnostic pitfalls. *J Neuromuscul Dis* 2016;3:413–38.
- [8] Feuer H, Jagoda A. Myasthenia gravis presenting as a unilateral abducensnerve palsy. *Am J Emerg Med* 2001;19:410–2.
- [9] Mandaliya R, Kulandaivel K, Nowotarski N, et al. A challenging diagnosis of fluctuating dyspnea: myasthenia gravis. *J Clin Diagn Res* 2015;9: OD06-8.
- [10] Sethi PK, Batra A, Sethi NK, et al. Vocal cord palsy: an uncommon presenting feature of myasthenia gravis. *Ann Indian Acad Neurol* 2011;14:42–3.
- [11] Khan KA, Bennett JD. Undiagnosed myasthenia gravis owing to a very unusual primary presentation. *Oral Surg Oral Med Oral Pathol Oral Radiol* 2014;118:e101–4.
- [12] Gullapalli D, Sharma TR. A 75-year-old Caucasian man with unusual presentation of myasthenia gravis. *J Am Geriatr Soc* 2010;58:2246–8.

- [13] Tremolizzo L, Giopato F, Piatti ML, et al. Myasthenia gravis mimicking stroke: a case series with sudden onset dysarthria. *Neurol Sci* 2015;36:895–8.
- [14] Ferreira S, Lage P, Claro I, et al. Dysphagia and dysarthria: unusual presentation of myasthenia gravis [in Portuguese]. *Acta Med Port* 2007;20:463–6.
- [15] Bailey C, Menon G, Saxena H. An unusual first presentation of myasthenia gravis. *Anaesthesia* 2004;59:515–6.
- [16] Wang JY, Pan J, Luo BY, et al. Temporal coincidence of myasthenia gravis and Guillain Barré syndrome associated with Hashimoto thyroiditis. *Neurol Sci* 2011;32:515–7.
- [17] Werner P, Kiechl S, Löscher W, et al. Distal myasthenia gravis – frequency and clinical course in a large prospective series. *Acta Neurol Scand* 2003;108:209–10.
- [18] Nations SP, Wolfe GI, Amato AA, et al. Distal myasthenia gravis. *Neurology* 1999;52:632–4.