

Fine-needle aspiration cytology as a useful diagnostic adjunct in the management of ameloblastoma: A report of four cases

ABSTRACT

Ameloblastoma is a locally aggressive common odontogenic tumor of the jaws. Although histopathological and radiological findings have been extensively studied for the diagnosis of ameloblastoma, usefulness of fine-needle aspiration cytology (FNAC) has not been explored much. Here, we have reported four cases of ameloblastomas diagnosed by FNAC and subsequently confirmed by histopathology.

Keywords: Ameloblastoma, cytology, odontogenic tumor

INTRODUCTION

Fine-needle aspiration cytology (FNAC) is a technique in which a lesion is penetrated with a fine needle to aspirate its contents for cytological diagnosis.^[1] Ameloblastoma is a common intrabony odontogenic tumor, comprising approximately 1% of all cysts and tumors of the jaws. The inherent property of this tumor is to cause expansion of the cortical bones, which makes the FNAC easy.^[2]

FNAC has been widely used for the diagnosis of lymph nodes, salivary glands, and thyroid and parathyroid gland diseases. Although FNAC is a simple, rapid, and minimally invasive procedure in contrast to biopsy, its use in the diagnosis of odontogenic tumors including ameloblastomas has not been explored much.^[1,3]

CASE REPORTS

Case 1

A 60-year-old male patient presented with a complaint of hard swelling involving anterior region of the mandible, measuring 4 cm × 5 cm for 1 year. Radiograph showed well-defined multilocular radiolucency in the anterior mandible.

Case 2

A 27-year-old female patient reported with painless firm swelling on the right posterior mandible for 5 years with a history of spontaneous exfoliation of right lower second and third molars. Orthopantomogram (OPG) showed multilocular radiolucent lesion involving right angle and ramus of the mandible.

Case 3

A 35-year-old female patient presented with a chief complaint of swelling of the left side of the mandible for 2 years. Swelling was firm, measuring 4 cm × 3 cm with buccal and lingual cortical bone expansion. She had a history of similar

**APRINA GUPTA, SURYA NARAYAN DAS¹,
SANGRAM PATRO², SUBHRAJIT RAUT³**

Departments of Oral Pathology and Microbiology and ²Oral and Maxillofacial Surgery, Hi-Tech Dental College and Hospital, Bhubaneswar, ¹Department of Oral Pathology and Microbiology, SCB Dental College, Cuttack, ³Department of Oral and Maxillofacial Surgery, Government of Odisha, Odisha, India

Address for correspondence: Dr. Aprna Gupta, Department of Oral Pathology and Microbiology, Hi-Tech Dental College and Hospital, Bhubaneswar - 751 010, Odisha, India. E-mail: draprna Gupta@gmail.com

Access this article online	
Website: www.njms.in	Quick Response Code 
DOI: 10.4103/njms.NJMS_51_17	

This is an open access journal, and articles are distributed under the terms of the Creative Commons Attribution-NonCommercial-ShareAlike 4.0 License, which allows others to remix, tweak, and build upon the work non-commercially, as long as appropriate credit is given and the new creations are licensed under the identical terms.

For reprints contact: reprints@medknow.com

How to cite this article: Gupta A, Das SN, Patro S, Raut S. Fine-needle aspiration cytology as a useful diagnostic adjunct in the management of ameloblastoma: A report of four cases. Natl J Maxillofac Surg 2018;9:103-5.

swelling operated 4 years back, and the diagnosis of that swelling could not be established as the patient did not produce the previous histopathological reports. Panoramic radiograph showed a well-defined multilocular radiolucency extending from the first premolar to third molar.

Case 4

A 22-year-old male patient presented with a painless swelling of the left posterior mandible for 1 year with buccal cortical bone expansion. OPG showed multilocular radiolucency extending from lateral incisor to the third molar.

The FNAC was performed in the labial/buccal sulcus area with the help of a 22-gauge needle after palpating for soft area of the lesion in corroboration of radiological findings, where the cortical bone was thinned out. Aspirates were scanty and hemorrhagic in nature. Three smears were prepared for each patient. Two were fixed in 95% alcohol and one was air-dried. Wet-fixed smears were stained by hematoxylin and eosin and Papanicolaou stains. Dry smears were stained by Leishman stain.

The smears were moderate-to-highly cellular in a hemorrhagic background with small basaloid cells in cohesive clusters or as pseudopapillary projections with focal peripheral palisading [Figure 1]. Cells had oval-to-round basophilic nuclei with finely distributed chromatin, inconspicuous nucleoli, and scanty-to-moderate amount of basophilic cytoplasm. Foci of loosely arranged, spindle-shaped cells with ovoid nuclei mimicking stellate reticulum-like cells were also seen [Figure 2]. On the basis of these cytological features, morphology, and pattern of arrangement of cells, diagnosis of ameloblastomas was given which were histologically confirmed. Out of the four smears, one showed squamous epithelial cells with abundant cytoplasm and central nucleus adjacent to the cluster of basaloid cells [Figure 3]. This was diagnosed as acanthomatous ameloblastoma which was also confirmed histologically [Figure 4]. No cellular atypia, necrosis, or mitotic figures were found.

DISCUSSION

The cytological findings in our cases revealed basaloid cells with focal palisaded arrangement in all the smears and keratinizing squamous cells which are cytological characteristics of ameloblastoma.^[1,2] Cytological diagnoses of ameloblastomas were given for all the four cases and were found to be correct histologically. Out of the four smears, one showed squamous epithelial cells with abundant cytoplasm and central nucleus adjacent

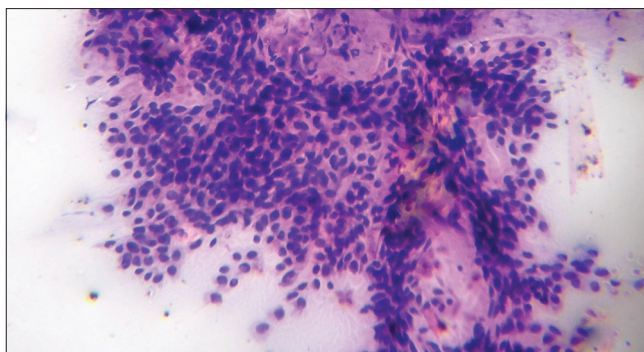


Figure 1: Fine-needle aspiration cytology smear shows cluster of basaloid cells with focal peripheral palisading of tumor cells (H and E, x100)

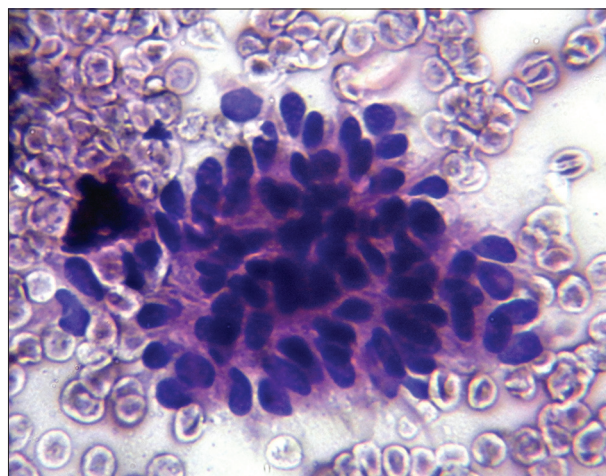


Figure 2: Cluster of basaloid cells with foci of spindle cells (H and E, x400)

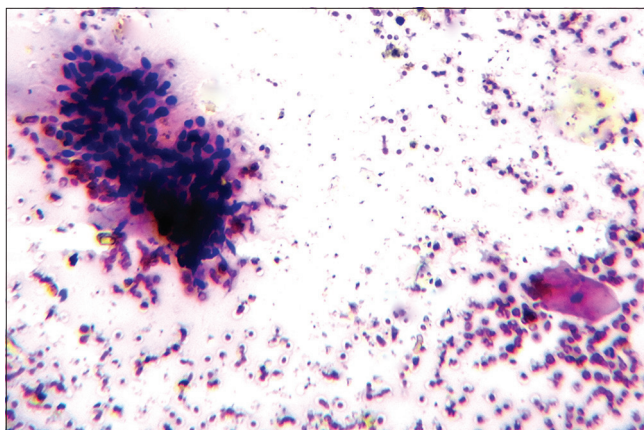


Figure 3: Squamous epithelial cell with cluster of basaloid cells (H and E, x100)

to the clusters of basaloid cells. This was diagnosed as acanthomatous ameloblastoma which was also confirmed histologically. Walke *et al.* also reported a case of acanthomatous ameloblastoma diagnosed on the basis of similar cytological features.^[4] Similarly, granular cell ameloblastoma was also diagnosed on the basis of cytological findings by Deshpande *et al.*^[5] Granular

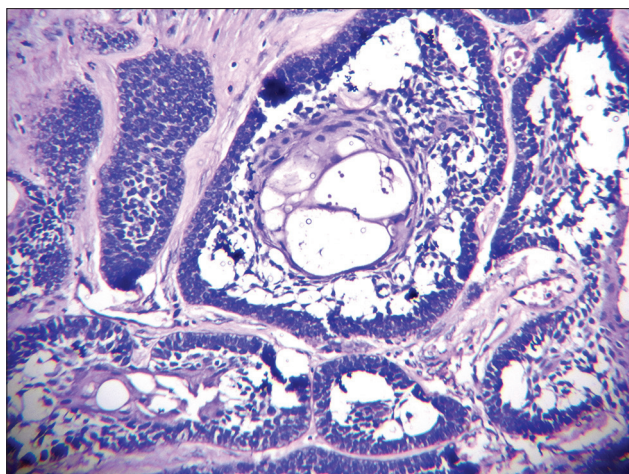


Figure 4: Follicular odontogenic epithelium demonstrating central squamous differentiation (H and E, ×400)

ameloblastoma being most aggressive variant needs maximum resection and fortunately can be diagnosed through cytological studies. Sometimes, aspiration from cystic ameloblastoma may have a paucity of characteristic basaloid cells; the presence of polymorphs and foamy macrophages which leads to difficulty in diagnosis. In this case, ameloblastoma should be differentiated from other benign cystic lesions of the jaw including odontogenic keratocyst and dentigerous cyst. Odontogenic keratocysts show anucleate and nucleate squamous cells having central pyknotic nuclei in keratinous background. Dentigerous cysts provide straw-colored fluid containing few squamous cells and foamy macrophages. The trimodal populations of basaloid, stellate, and squamous cells are characteristic to differentiate ameloblastomas from these cysts.^[4]

Several other intraosseous malignant lesions such as lymphoma, primary intraosseous squamous cell carcinoma, mucoepidermoid carcinoma, small cell carcinoma, and ameloblastic carcinoma showing features of basaloid cells should also be excluded. Lymphoma cells may also resemble the basaloid cells of ameloblastoma; however, lymphoglandular bodies are also seen, but not in ameloblastoma. Unlike ameloblastomas, primary intraosseous squamous cell carcinoma would have malignant features. Mucoepidermoid carcinoma shows mucous cells, intermediate cells, and epidermoid cells in a mucoid background. Unlike ameloblastoma, ameloblastic carcinoma shows high cellularity, nuclear pleomorphism, prominent nucleoli, abnormal mitoses, and necrosis.^[4,6]

Although FNAC is a simple, safe, inexpensive, and minimally invasive procedure, it has still attracted scant attention for its use in the diagnosis of very commonly occurring odontogenic tumor-like ameloblastomas.^[6]

CONCLUSION

FNAC is a simple, rapid, accurate, inexpensive, and minimally invasive procedure for the preoperative diagnosis of ameloblastomas in contrast to biopsy.

Declaration of patient consent

The authors certify that they have obtained all appropriate patient consent forms. In the form the patient(s) has/have given his/her/their consent for his/her/their images and other clinical information to be reported in the journal. The patients understand that their names and initials will not be published and due efforts will be made to conceal their identity, but anonymity cannot be guaranteed.

Acknowledgment

We would like to thank all the staffs of Department of Oral Pathology and Microbiology, SCB Dental College, for their support for this study.

Financial support and sponsorship

Nil.

Conflicts of interest

There are no conflicts of interest.

REFERENCES

1. Chandavarkar V, Uma K, Mishra M, Sangeetha R, Gupta R, Sharma R, et al. Ameloblastoma: Cytopathologic profile of 12 cases and literature review. *J Cytol* 2014;31:161-4.
2. Kaliamoorthy S, Venkatapathy R, Babu P, Veeran V. Practical significance of utilizing fine needle aspiration cytology as an adjunct diagnostic aid in the preoperative presumptive diagnosis of ameloblastoma. *J Cytol* 2013;30:247-51.
3. Singh S, Garg N, Gupta S, Marwah N, Kalra R, Singh V, et al. Fine needle aspiration cytology in lesions of oral and maxillofacial region: Diagnostic pitfalls. *J Cytol* 2011;28:93-7.
4. Walke VA, Munshi MM, Raut WK, Bobahate SK. Cytology diagnosis of acanthomatous ameloblastomas. *J Cytol* 2008;25:62-4.
5. Deshpande A, Umap P, Munshi M. Granular cell ameloblastoma of the jaw. A report of two cases with fine needle aspiration cytology. *Acta Cytol* 2000;44:81-5.
6. Anchinmane VT, Rupani AB, Shedge RT, Kavishwar VS. Diagnosis of ameloblastomas of mandible by fine needle aspiration cytology. *Bombay Hosp J* 2011;53:484-7.