

Localized Pretibial Varicose Vein Caused by an Intraosseous Venous Anomaly

Sangwook Chun, M.D., Joung Woo Son, M.D., Jae-Wook Ryu, M.D.

Department of Thoracic and Cardiovascular Surgery, Dankook University Hospital, Cheonan, Korea

ARTICLE INFO

Received November 13, 2019

Revised November 21, 2019

Accepted November 22, 2019

Corresponding author

Jae-Wook Ryu

Tel 82-41-550-6269

Fax 82-41-550-7655

E-mail j3thorax@chol.com

ORCID

<https://orcid.org/0000-0002-4595-1286>

A 36-year-old man presented to the hospital with protruding blood vessels in his left lower leg accompanied by cramping. An ultrasonographic examination of the leg revealed focal reflux without truncal vein reflux. During phlebectomy, the varix was found to be connected to the intraosseous vein through a tibial opening. Postoperative computed tomography and magnetic resonance imaging showed an osteolytic lesion in the tibial shaft and an intraosseous vascular anomaly. The patient was discharged without complications and scheduled for periodic follow-ups. This young man's varicose vein seemed to be from a tibial intraosseous vascular anomaly, which is extremely rare.

Keywords: Varicose veins, Vascular malformations, Vascular diseases

Case report

A 36-year-old man visited the outpatient department of a cardiothoracic and vascular surgery department and presented with protruding vessels on the left leg accompanied by cramping. Upon gross examination, the vessel was a ping-pong ball-sized varix that was localized on the pretibial area (Fig. 1). Ultrasonographic examination of the leg revealed distended veins with reflux, which was localized in the pretibial area without truncal venous reflux or a perforator.

Surgery was performed with the patient under spinal anesthesia. A skin incision of approximately 1 cm was made at the left pretibial area, and the vessel was divided with a mosquito clamp. During phlebectomy, the divided vein was observed to come from a tibial opening. The vein was ligated, and the opening of the tibia was covered by periosteum. The day following the operation, no varix was observed at the surgical site. The patient was discharged without any complications.

The patient returned several days after the operation for a further evaluation. Radiographs of the left leg showed a focal defect on the tibia (Fig. 2A). Computed tomography (CT) revealed that the intraosseous vein was communicating with the superficial vein through a 3-mm tibial opening (Fig. 2B, C). Additionally, the intraosseous vein origi-

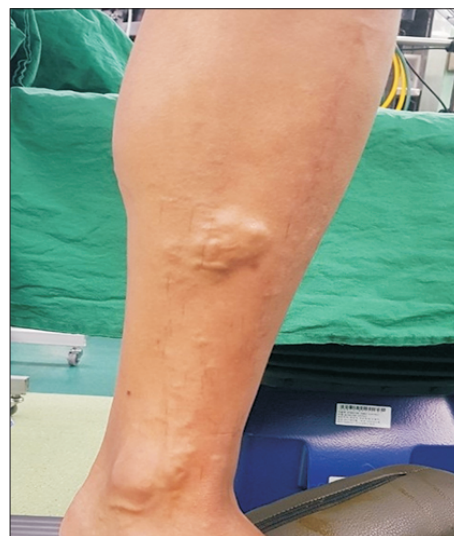

Fig. 1. Localized ping-pong ball-sized varix in the left pretibial area.

nated from the popliteal vein and drained into the marrow of the tibia through the Haversian canal, constituting a vascular anomaly. Magnetic resonance imaging (MRI) showed an intraosseous vascular structure that was suspicious for hemangioma, and there was no evidence of a malignancy or arteriovenous fistula (Fig. 3A, B). The patient's clinical course was excellent, with no complications or

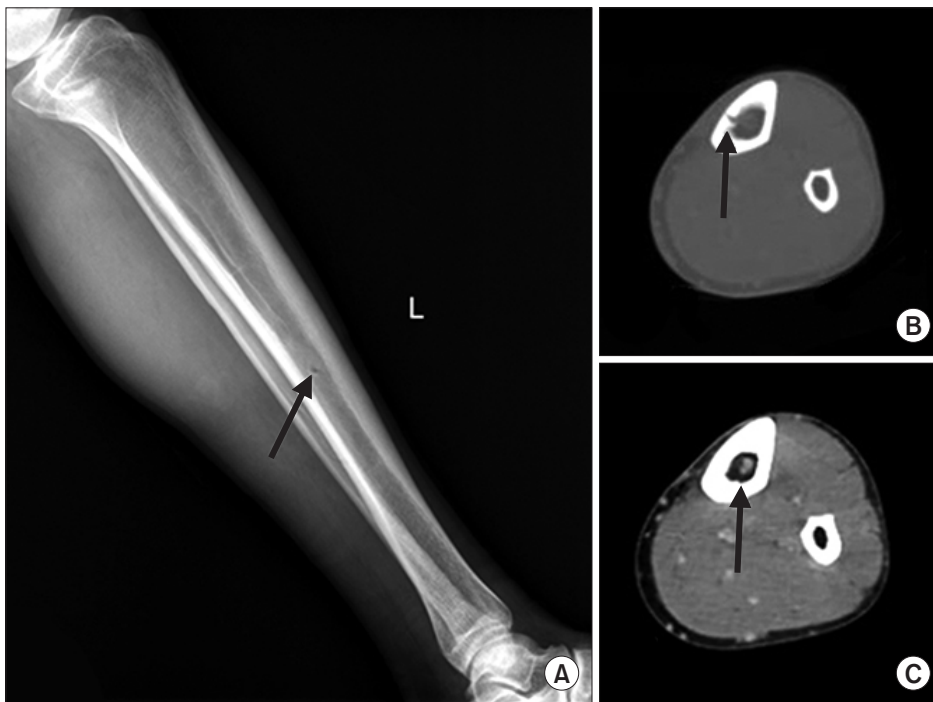

Fig. 2. (A) Simple radiography revealed a cortical bone defect in the tibia (arrow). (B, C) Computed tomography showed a tibial opening and an intraosseous vascular cluster (arrow).

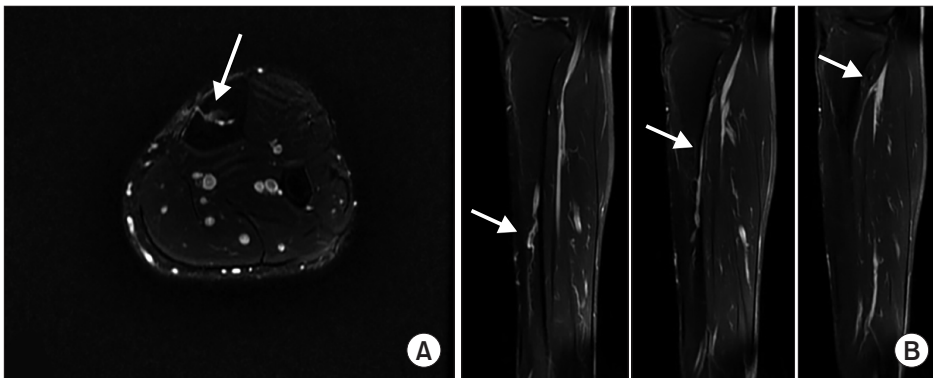


Fig. 3. Magnetic resonance imaging findings. (A) On an axial view, the intraosseous vascular structure was found to be communicating with the superficial vein (arrow). (B) On a sagittal view, the intraosseous vessel was shown to originate from the popliteal vein (arrows).

cramping. He was referred to the orthopedics department and scheduled for annual MRI follow-ups.

The study was approved by the Institutional Review Board and the requirement for informed consent was waived (IRB approval no., 2020-03-016).

Discussion

The incidence of varicose veins in the lower extremities is 10%–40% worldwide, and varicose veins are most common in individuals 30–70 years of age [1]. Varicose veins are related to conditions that cause abnormal venous flow, like pregnancy and immobility. In most cases of varicose veins, the vascular wall expands due to abnormalities of

venous endothelial tissues and smooth muscle cells, resulting in secondary venous valve regurgitation. In the lower extremities, varicose veins usually develop from vertical reflux from truncal valvular insufficiency, including the saphenofemoral junction or saphenopopliteal junction, or from horizontal reflux of perforators.

However, acquired valve regurgitation can occur for other reasons. Nonspecific causes of varicose veins include the following: vulvoperineal varicosity, round ligament varicosity, persistent sciatic vein incompetence, Klippel-Trenaunay syndrome, and portosystemic collateral pathways [2]. Additionally, as described above, an intraosseous drainage anomaly can cause varicose veins.

Since Boutin et al. [3] first reported an intraosseous ve-

nous drainage anomaly in 1997, such anomalies have rarely been reported [4]. They can be diagnosed by color Doppler ultrasonography showing venous flow in the varices through a cortical defect. However, because ultrasound waves cannot penetrate the bony cortex, it is not easy to identify an intraosseous communication. Thus, for further evaluation, CT scans and MRI are used for radiological confirmation and differential diagnosis from other vascular anomalies, such as arteriovenous malformations, arteriovenous fistulas, hemangiomas, and other mass lesions [5].

Because intraosseous venous drainage can cause venous valvular insufficiency by increasing venous pressure [6], caution is needed when evaluating pretibial varices even if there is definite truncal valvular insufficiency. Familiarity with the characteristic triad of these lesions will be helpful for the diagnosis: (1) symptom-producing pretibial varices, (2) a cortical defect in the anterior aspect of the mid-tibia, and (3) an enlarged intraosseous vein and nutrient canal [3].

Varices should be treated surgically to relieve venous pressure. There are many options for treating varices originating from intraosseous drainage anomalies, including phlebectomy, ligation, stripping, and percutaneous ablation. Sclerotherapy is not recommended because of communication with the intraosseous vascular structure. The management and prognosis of intraosseous vascular anomalies in the tibia remain unclear. In many studies, the authors recommended conservative treatment and periodic check-ups with imaging examinations as the initial management if the lesion is asymptomatic. However, if the lesion causes symptoms, surgical excision can be performed with or without a bone graft.

In conclusion, for most patients with varicose veins that surgeons encounter, reflux is limited in the truncal and

perforating veins. However, in recognition of the possibility of rare cases like the one presented herein, careful preoperative evaluation and management should be performed in patients presenting with varices in the pretibial area.

Conflict of interest

No potential conflict of interest relevant to this article was reported.

ORCID

Sangwook Chun: <https://orcid.org/0000-0003-1561-442X>

Joung Woo Son: <https://orcid.org/0000-0003-0704-6987>

Jae-Wook Ryu: <https://orcid.org/0000-0002-4595-1286>

References

1. Callam MJ. *Epidemiology of varicose veins*. Br J Surg 1994;81:167-73.
2. Golledge J, Quigley FG. *Pathogenesis of varicose veins*. Eur J Vasc Endovasc Surg 2003;25:319-24.
3. Boutin RD, Sartoris DJ, Rose SC, et al. *Intraosseous venous drainage anomaly in patients with pretibial varices: imaging findings*. Radiology 1997;202:751-7.
4. Kwee RM, Kavanagh EC, Adriaensen ME. *Intraosseous venous drainage of pretibial varices*. Skeletal Radiol 2013;42:843-7.
5. Flors L, Leiva-Salinas C, Maged IM, et al. *MR imaging of soft-tissue vascular malformations: diagnosis, classification, and therapy follow-up*. Radiographics 2011;31:1321-40.
6. Moraes FB, Camelo CP, Brandao ML, Favaro PI, Barbosa TA, Barbosa RC. *Intraosseous anomalous drainage: a rare case of pretibial varicose vein*. Rev Bras Ortop 2016;51:716-9.