

CASE REPORT

# A Case Report of Conservative Management for a Roller-Coaster-Related Vitreous Haemorrhage

Alexander James Brent · Abdul R. El-Khayat · Shamfa A. M. Peart · Somnath Banerjee

Received: February 1, 2018 / Published online: March 9, 2018  
© The Author(s) 2018. This article is an open access publication

## ABSTRACT

The purpose of this report is to describe the case and management of an unexplained vitreous haemorrhage that occurred after repeated roller-coaster riding. The authors inadvertently demonstrate the value of observation over immediate surgery in certain situations and review the literature on vitreoretinal and other ocular complications after roller-coaster riding. A 26-year-old male presented 12 h after riding high-velocity roller-coasters with a left vitreous haemorrhage. A hazy view of the retina and B-scan revealed a bullous area of superior-temporal retinal lifting. A diagnosis of a presumed macula-on retinal detachment was made and the patient was listed for a pars plana vitrectomy retinal detachment repair. An abnormal clotting result, which was subsequently found out to be erroneous, ultimately delayed the procedure. During this delay the vision and retinal view improved to an extent whereby the diagnosis of a retinoschisis with an intraretinal cyst was made and surgery was avoided. The

patient regained 6/6 vision, without the need to undergo surgery. Historically the management of an unexplained vitreous haemorrhage was observation with serial B-scans. The current evidence and practice for treating unexplained vitreous haemorrhage have since moved towards early surgical intervention. The authors highlight that despite the current trend, a place remains for conservative management for selected cases.

**Keywords:** Pars plana vitrectomy; Retinoschisis; Roller-coaster; Vitreous haemorrhage

## INTRODUCTION

Roller-coaster riding exerts a range of gravitational forces (g-forces) on riders repeatedly over short periods of time. These forces are significant enough to cause both systemic and ocular complications. The authors describe the management of the first reported case of roller-coaster-related vitreous haemorrhage and compare this to the current literature.

## CASE REPORT

A 26-year-old Asian male presented with a sudden onset of left painless visual loss, which he described as a 'veil' effect. This occurred 12 h

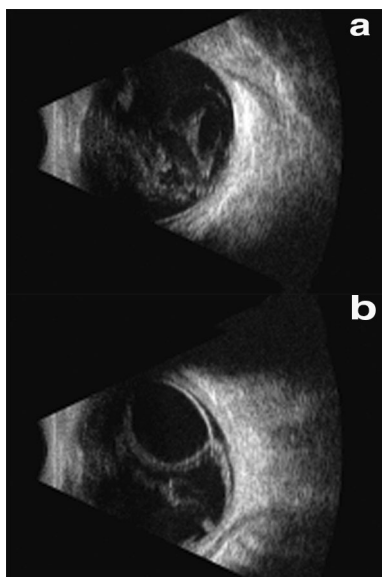
**Enhanced content** To view enhanced content for this article go to <https://doi.org/10.6084/m9.figshare.5932855>.

A. J. Brent (✉) · A. R. El-Khayat · S. A. M. Peart · S. Banerjee  
Ophthalmology Department, Leicester Royal Infirmary, Infirmary Square, Leicester, UK  
e-mail: [ajb101@doctors.org.uk](mailto:ajb101@doctors.org.uk)

after he had been on multiple high-speed roller-coasters at a theme park in the UK. There were no other preceding symptoms or history of trauma.

The patient had a prescription of  $-1.00$  dioptre sphere (DS) in each eye with no significant astigmatism. He denied any past ophthalmic or medical history.

On presentation the visual acuity (VA) was 6/9 unaided in the right eye and hand movements in the left eye. On examination the right eye was unremarkable. The left eye was phakic with  $+1$  red blood cells in the anterior chamber and a fundus-obscuring vitreous haemorrhage (VH). The patient was able to project light in all four quadrants in the left eye. A B-scan performed on the day of presentation, by the on-call ophthalmology registrar highlighted the vitreous haemorrhage (Fig. 1a). Superior-nasally there was a bullous area of retinal lifting with a cystic appearance (Fig. 1b), which spared the macular. This extended from 9 to 12 o'clock and had limited mobility. No retinal tears or evidence of vitreous detachment was detected. Although the B-scan was repeated by the vitreoretinal fellow the next day, there is no



**Fig. 1** A B-scan image of the left eye demonstrating **a** dense vitreous haemorrhage and **b** an area of superior-nasal bullous retinal lifting with a cystic appearance

dedicated ultrasound practitioner or standardised scanning protocol.

A vitreoretinal opinion was sought the next day. With the indirect ophthalmoscope a hazy view of the superior nasal retina appeared to show some non-specific elevation (Fig. 2b), but no retinal breaks or pigment in the vitreous was found. Given the findings and after a discussion with the patient on the risks versus the benefits of early surgical intervention, an urgent pars plana vitrectomy (PPV) for a presumed macular-on retinal detachment was scheduled for the next day.

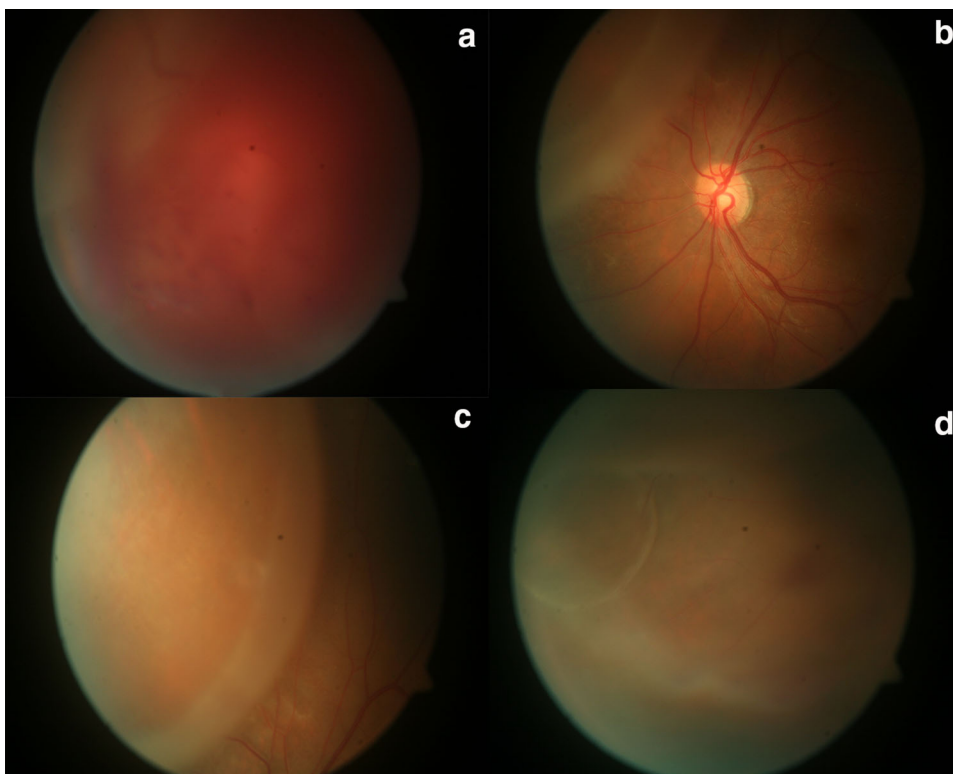
Unfortunately, or perhaps fortunately as it transpires, there was an abnormality with the patient's activated partial thromboplastin time (APTT) clotting result, meaning that the surgery had to be delayed. After further haematological investigations and consultation it transpired that this was a simple laboratory technical error and there was no underlying abnormality.

Limitations in terms of access to haematological investigations and emergency vitreoretinal theatre time meant that the surgery could not be rescheduled until 5 days later. On the day of surgery, the patient's vision was noted to have improved to 6/18 and the view of the retina had improved significantly. A superior-nasal retinoschisis became apparent with no evidence of rhegmatogenous retinal detachment. No breaks were found and the vitreous remained attached. Over the next 4 weeks the vision improved to 6/6 (aided) and the view cleared further, demonstrating a superior-nasal retinoschisis with an intraretinal cyst (Fig. 2b–d). This status remained the same after 3 months of follow-up.

Informed consent was obtained from the patient for being included in the study and for publication of the case and accompanying figures.

## DISCUSSION

Roller-coaster riding is well reported to exert various ranges of g-forces on riders, with our patient having been on multiple rides of up to 4.5 g each. These g-forces have been reported as significant enough to cause, without evidence



**Fig. 2** Colour fundus images of the left eye at **a** day 2 post presentation demonstrating a hazy area of retinal elevation through a vitreous haemorrhage and at **b–d** day 28 demonstrating a superior nasal retinoschisis with an intraretinal cyst

of direct trauma, serious systemic complications such as subarachnoid haemorrhages and carotid dissections.

A literature review (Medline, Embase, NHS evidence, UpToDate, Dynamed Plus) revealed two reported cases of retinal detachments occurring immediately after riding a roller-coaster [1]. In both cases the individuals had significant myopia and therefore were considered at-risk individuals [1]. To the best of the authors' knowledge there are no reports of isolated VHs or retinal tears occurring after roller-coaster riding.

Other ocular complications of roller-coaster riding, unrelated to direct trauma, have been reported. These include a reported case of a decompensated retinal macrovessel [2], three cases of retinal haemorrhages [3–5], a case of a subluxed IOL sporadically repositioning [6], a retinal artery occlusion with associated carotid and vertebral artery dissections and a case of glaucoma secondary to lens capsule rupture [7, 8].

These patients had underlying risk factors predisposing them to potential ocular complications.

The authors propose that the multidimensional g-forces to which our patient was exposed may have caused shearing forces at the vitreoretinal interface that resulted in a VH, similar to the acceleration-deceleration mechanism described in shaken baby syndrome. It is possible that the pre-existing retinoschisis had an area of abnormal vitreoretinal adhesion, predisposing the patient to such complications. However in the absence of an apparent PVD, it is possible that increased cerebral pressure and associated retinal venous pressure resulted in an incidental VH.

Theme parks usually advise that anyone who is pregnant or has a heart, neck or back condition should avoid such rides. Warnings about ocular conditions are not typically apparent.

Historically the management of unexplained VH has been close observation with serial ultrasound scans. In recent times early surgical

intervention has become increasingly popular. Sarrafizadeh et al. [9] demonstrated that with conservative management, 48% of unexplained VH patients under 80 years old developed an RD. Of these, half were complicated by proliferative vitreoretinopathy (PVR) and therefore the final mean VA of all patients was 6/18-1 [9]. Tan et al. [10] demonstrated that with acute surgical intervention 88% of eyes were found to have retinal tears. Furthermore, there was only a 5% rate of retinal detachment post-operatively and the mean average final vision was 6/7.5 [10]. Conservative management is usually only advocated in cases where there is either another clear attributable cause or the patient is over 80 years old. In patients older than 80, the VH is more likely to be secondary to wet age-related macular degeneration (AMD) or a macroaneurysm rather than a posterior vitreous detachment (PVD). In addition to this, Sandinha et al. [11] described that using a dedicated ophthalmic ultrasonographer and standardised scan protocol could significantly improve the sensitivity of identifying tears and detachments and increase the proportion of such patients who could be managed conservatively.

In a young patient with an attached vitreous, there is a risk that a rhegmatogenous RD may be induced by PPV surgery. Furthermore, phakic patients usually develop an early onset cataract induced by the PPV that requires surgery. Younger patients, such as ours, would therefore prematurely lose their ability to accommodate. Multiple surgeries carry all the usual risks and put a significant burden on the patient's life. Observing in such a case would carry the potential risk of a RD propagating and developing proliferative vitreoretinopathy in the interim, subsequently resulting in a lower visual potential.

Vitreoretinal disorders after roller-coaster riding are exceptionally rare in the literature, with this being the first reported case of isolated VH. A range of ocular complications has been described as individual cases, but they predominantly only occur in predisposed patients. The authors highlight that despite the current literature advocating early surgical intervention in cases of unexplained VH, there is still a place for conservative management.

## ACKNOWLEDGEMENTS

**Funding.** No funding or sponsorship was received for this study or publication of this article. The article processing charges were funded by the authors.

**Authorship.** All named authors meet the International Committee of Medical Journal Editors (ICMJE) criteria for authorship for this manuscript, take responsibility for the integrity of the work as a whole, and have given final approval for the version to be published.

**Disclosures.** Alexander J. Brent, Abdul R. El-Khayat, Shamfa A.M. Peart and Somnath Banerjee have nothing to disclose.

**Compliance with Ethics Guidelines.** Informed consent was obtained from the patient for being included in the study, for publication of the case and accompanying figures.

**Open Access.** This article is distributed under the terms of the Creative Commons Attribution-NonCommercial 4.0 International License (<http://creativecommons.org/licenses/by-nc/4.0/>), which permits any non-commercial use, distribution, and reproduction in any medium, provided you give appropriate credit to the original author(s) and the source, provide a link to the Creative Commons license, and indicate if changes were made.

## REFERENCES

1. Shaikh S. Roller coaster-associated retinal detachments. *Retin Cases Brief Rep.* 2011;5(2):128–9.
2. Beatty S, Goodall K, Radford R, Lavin MJ. Decompression of a congenital retinal macrovessel with arteriovenous communications induced by repetitive rollercoaster rides. *Am J Ophthalmol.* 2000;130(4):527–8.
3. Patel YP, Saraf SS, Desai A, Desai UR. Roller coaster retinopathy: case report of symptomatic bilateral intraretinal hemorrhages after shaking injury in an otherwise healthy adult. *Retin Cases Brief Rep.* 2016;10(3):259–62.

4. Guven D, Acar Z, Demir M, Sendul Y, Demir AG, Ergen E. Macular hemorrhage after roller coaster riding in a single-eyed patient with congenital glaucoma. *Arq Bras Oftalmol*. 2016;79(6):414–6.
5. Asefzadeh B, Connell N. Macular haemorrhage after repetitive roller coaster riding. *Clin Exp Optom*. 2009;92(5):447–8.
6. Bosch MM, Landau K, Thiel MA. Repositioning of a dislocated intraocular lens during a roller-coaster ride. *N Engl J Med*. 2003;349(11):1094–6.
7. Ozkan AY, Volpi J, Arat A, Klucznik R, Diaz O. Bilateral internal carotid artery and vertebral artery dissections with retinal artery occlusion after a roller coaster ride—case report and a review. *Ulus Travma Acil Cerrahi Derg*. 2011;17(1):75–8.
8. Andrews RM, Bell RW, Jayamanne DG, Basanquet RC, Cottrell DG. ‘Roller-coaster glaucoma’: an unusual complication of Marfan’s syndrome. *Eye (Lond)*. 1994;8:358–60.
9. Sarrafzadeh R, Hassan TS, Ruby AJ, et al. Incidence of retinal detachment and visual outcome in eyes presenting with posterior vitreous separation and dense fundus-obscuring vitreous hemorrhage. *Ophthalmology*. 2001;108(12):2273–8.
10. Tan HS, Mura M, Bijl HM. Early vitrectomy for vitreous hemorrhage associated with retinal tears. *Am J Ophthalmol*. 2010;150(4):529–33.
11. Sandinah MT, Kotagiri AK, Owen RI, Geenen C, Steel DH. Accuracy of B-scan ultrasonography in acute fundus obscuring vitreous hemorrhage using a standardized scanning protocol and a dedicated ophthalmic ultrasonographer. *Clin Ophthalmol*. 2017;11:1365–70.