



# Anaesthetic Management of a Patient with Brugada Syndrome in Total Knee Arthroplasty

Bahattin Tuncali<sup>1</sup> , Gizem Kökten<sup>1</sup> , Cihan Altun<sup>2</sup> 

<sup>1</sup>Department of Anaesthesiology and Reanimation, Başkent University Faculty of Medicine, Ankara, Turkey

<sup>2</sup>Department of Cardiology, Başkent University Faculty of Medicine, Ankara, Turkey

*Cite this article as:* Tuncali B, Kökten G, Altun C. Anaesthetic Management of a Patient with Brugada Syndrome in Total Knee Arthroplasty. Turk J Anaesthesiol Reanim 2021; 49(1): 70-3.

## Abstract

We report the case of a 52-year-old female diagnosed with Brugada syndrome (BrS) scheduled to undergo right total knee arthroplasty. General anaesthesia was induced and maintained with thiopental intravenous sodium + remifentanyl and sevoflurane + remifentanyl infusion, respectively. Rocuronium bromide was used as the muscle relaxant. The defibrillator was ready for use with the electrodes on the patient. Sugammadex was used for muscle relaxant antagonization. Postoperative analgesia was provided by intermittent morphine HCL via an epidural catheter, intravenous patient-controlled analgesia (Meperidine), and intravenous tenoxicam. The patient was discharged on the 6th day without any problem. Anaesthetic management of patients with BrS is challenging for anaesthesiologists, because fatal cardiac arrhythmias can be triggered by many drugs commonly used in the perioperative period such as bupivacaine, lidocaine, neostigmine, propofol, succinylcholine, ketamine, and tramadol. In these cases, a detailed preoperative evaluation including family history, avoidance of drugs triggering arrhythmia, taking precautions against arrhythmia, and using the agents that are reported to be safe are essential for patient safety.

**Keywords:** Anaesthesia, Brugada syndrome, ECG, knee arthroplasty

## Introduction

Brugada syndrome (BrS) is a rare genetic disorder characterized by specific changes in electrocardiography (ECG), including ST elevation with a successive negative T wave in the right precordial leads without any electrolyte imbalance, structural or ischemic heart diseases (1-3). Anaesthetic management of patients with BrS may be a challenge for anaesthesiologists, because many factors that interact with cardiac ion channels can provoke malignant ventricular arrhythmia in the perioperative period (4-6).

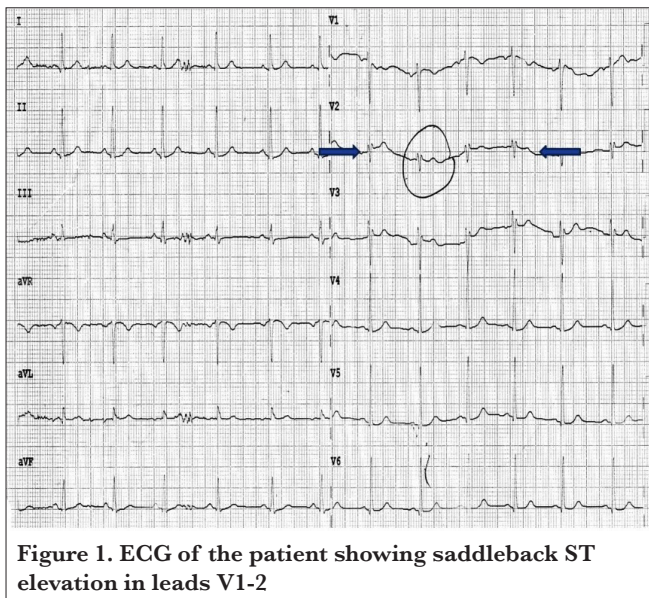
Herein, we presented the anaesthetic management of a patient with previously diagnosed BrS, who underwent elective knee arthroplasty for osteoarthritis. The patient provided written consent for publication of this report.

## Case Presentation

A 52-year-old female admitted for right total knee arthroplasty due to severe gonarthrosis. Medical history revealed Sjögren's syndrome, hypertension, vasospastic angina, and BrS (5 years ago), and her father passed away in sleep at the age of 49 years. She had been diagnosed with lumbar disc herniation (LDH) two years ago but was not operated, because she and her family displayed great anxiety for the fear of intraoperative death. Consequently, she had a drop foot. The drugs regularly used were trimetazidine dihydrochloride, diltiazem, isosorbide mononitrate, diclofenac sodium, mephenoxalone, and acetaminophen. Physical examination and laboratory findings were normal except for a drop foot. ECG showed a characteristic pattern of BrS type 2 with saddleback ST elevation in V1-2 leads and non-sustained ventricular tachycardia attacks were found in 24-hour rhythm holter monitoring (Figure 1,

2). Cardiology, rheumatology, and chest diseases departments evaluated the patient.

Following standard monitoring (ECG, blood pressure, SpO<sub>2</sub>, and body temperature) and intravenous (IV) cannulation, she was sedated with IV midazolam, and an epidural catheter was placed at L2-3 level without local anaesthetic. General anaesthesia was induced and maintained with IV thiopental sodium + remifentanyl and sevoflurane (2-2.5%) in an air-oxygen (50-50%) mixture+IV remifentanyl infusion, respectively. Endotracheal intubation was facilitated by rocuronium bromide. A foley catheter was also placed. The defibrillator was ready for use with the electrodes attached on the patient during the surgical procedure (Figure 3). Hemodynamic status was stable with no ventricular arrhythmia throughout the surgery. Sugammadex was used for the reversal of residual neuromuscular block. Postoperative analgesia was provided by intermittent morphine HCl injection via the epidural catheter, IV patient-controlled analgesia (Meperidine), and tenoxicam. She was discharged on the 6th day of admission without any problem.



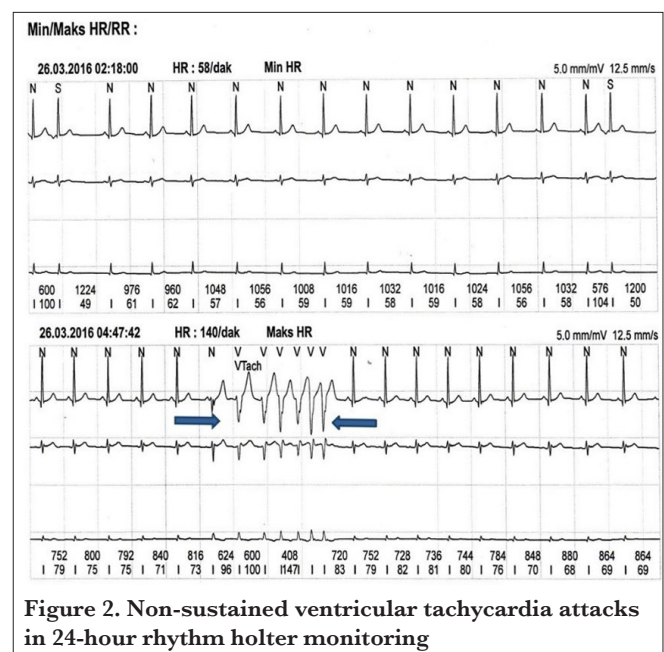
**Figure 1.** ECG of the patient showing saddleback ST elevation in leads V1-2

#### Main Points:

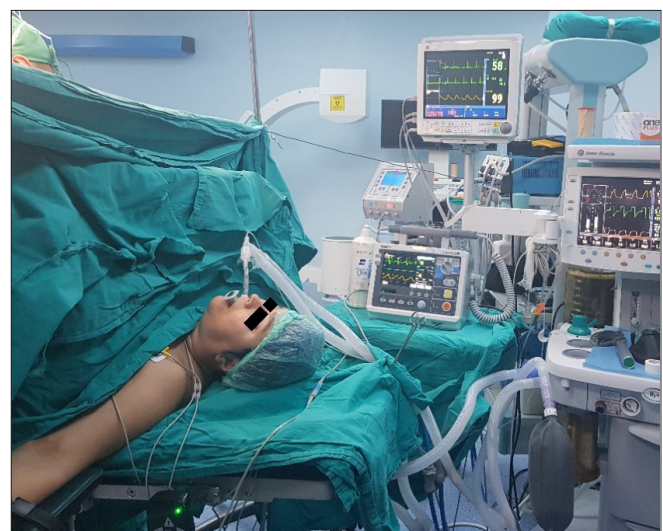- The case of a 52-year-old female diagnosed with BrS scheduled to undergo right total knee arthroplasty is reported.
- Anaesthetic management of patients with BrS is challenging, because fatal cardiac arrhythmias can be triggered by many drugs commonly used in the perioperative period.
- In BrS, a detailed preoperative evaluation and preparation, avoidance of drugs triggering arrhythmia, taking precautions against arrhythmia, and using the agents that are reported to be safe are essential for patient safety.

## Discussion

BrS is an autosomal dominant disease with a prevalence of 5/10000 in general population (1). It affects cardiac ion channels predisposing the patients to fatal malignant arrhythmia typically occurring at rest or sleep when vagal activity predominates. The most common genotype was found in the SCN5A gene (2). According to ECG changes, there are three types of BrS. Presence of BrS Type 1, family history of sudden cardiac death, inducible ventricular tachycardia (VT)/ventricular fibrillation (VF), and positive late potentials increase the risk of sudden cardiac death. In these patients, an implantable cardioverter/defibrillator is recommended (3,



**Figure 2.** Non-sustained ventricular tachycardia attacks in 24-hour rhythm holter monitoring



**Figure 3.** The defibrillator was ready for use during the procedure

4). Fortunately, our patient had the diagnosis of BrS Type 2. In contrast, she had a family history and had refused the implantable cardioverter, which puts her at increased risk.

Although successful use of both general and regional anaesthesia in patients with BrS has been reported, many factors may trigger malignant ventricular arrhythmias in the perioperative period (4, 5). Increased vagal tone, decreased sympathetic activity, and thermal changes are among the physiological conditions. Anaesthetic agents including bupivacaine, lidocaine, neostigmine, propofol, succinylcholine, ketamine, and tramadol may trigger fatal ventricular arrhythmias in BrS (6, 7). However, several case reports showed that midazolam, thiopental sodium, fentanyl, volatile agents, muscle relaxants, and sugammadex have been used without any complications (8). For our patient, we preferred general anaesthesia because there was a strong patient refusal for regional anaesthesia and also because general anaesthesia is recommended in patients who has been diagnosed with BrS (9, 10). Therefore, we avoided the use of local anaesthetics for both anaesthesia and postoperative analgesia because all local anaesthetics are sodium channel blockers. During the epidural catheter placement without local anaesthetic, we used moderate sedation in order to prevent any vagal reflexes.

Perioperative thermal changes can induce malignant ventricular arrhythmia in BrS and should be avoided (4, 11). In our patient, body temperature was monitored continuously, and normothermia was maintained using active and passive measures including warm blanket, forced air warming, and fluid warmers. Another important issue was to maintain adequate anaesthetic depth during the surgical procedure. Minimum alveolar concentration of sevoflurane was maintained in concentration of 2.0-2.2% throughout the surgery, and IV remifentanyl infusion was maintained at 0.25 mcg kg<sup>-1</sup> min<sup>-1</sup> because we were unable to use bispectral index monitoring. At the end of the surgery, we preferred sugammadex for reversal, because it is not a parasympathomimetic agent and its use was reported without complications in patients with BrS (4, 12).

Postoperative pain control was also critically important in our patient because pain can also induce vagal response. We used the combination of epidural intermittent morphine HCl injection, IV patient-controlled analgesia (Meperidine), and IV tenoxicam in postoperative analgesia. The visual analogue scores were ≤3 during the entire postoperative period, and patient satisfaction was sufficient. Despite all the measures, VF/VT may occur at any time throughout the perioperative period. A functioning defibrillator should be ready for use because urgent patient management is vital in this condition (9-12). In our patient, throughout the entire perioperative period until discharge, a defibrillator was set with its electrodes

attached on the patient for urgent access in case of ventricular arrhythmia.

## Conclusion

Anaesthetic management of a patient with BrS may be a challenge for the anaesthesiologist because an ideal anaesthetic technique has not been established yet. Preoperative evaluation should include a detailed family history and correction of electrolyte imbalances. Prevention of inadequate anaesthesia/analgesia, unintended hypothermia, postural and autonomic changes, avoidance of drugs affecting myocardial sodium channels, and conditions that may trigger fatal arrhythmia such as VF/VT, close ECG monitoring, taking precautions against arrhythmia, and using the agents that are reported to be safe in the literature are essential for patient safety.

**Informed Consent:** Written informed consent was obtained from patient who participated in this case.

**Peer-review:** Externally peer-reviewed.

**Author Contributions:** Concept – B.T.; Design – B.T.; Supervision – G.K., C.A.; Resources – B.T., G.K., C.A.; Materials – B.T., C.A.; Data Collection and/or Processing – B.T., G.K.; Analysis and/or Interpretation – B.T., G.K., C.A.; Literature Search – B.T., G.K., C.A.; Writing Manuscript – B.T.; Critical Review – B.T., G.K., C.A.; Other – B.T., G.K., C.A.

**Conflict of Interest:** The authors have no conflicts of interest to declare.

**Financial Disclosure:** The authors declared that this study has received no financial support.

## References

1. Sieira J, Brugada P. The definition of the Brugada syndrome. *Eur Heart J* 2017; 38: 3029-34. [\[Crossref\]](#)
2. Gourraud JB, Barc J, Thollet A, Le Marec H, Probst V. Brugada syndrome: Diagnosis, risk stratification and management. *Arch Cardiovasc Dis* 2017; 110: 188-95. [\[Crossref\]](#)
3. Juang JJ, Horie M. Genetics of Brugada syndrome. *J Arrhythm* 2016; 32: 418-25. [\[Crossref\]](#)
4. Alzahrani T. Near miss in a patient with undiagnosed Brugada syndrome: a case report and literature review. *J Clin Anesth* 2016; 35: 427-9. [\[Crossref\]](#)
5. Sheikh AS, Ranjan K. Brugada syndrome: a review of the literature. *Clin Med (Lond)* 2014; 14: 482-9. [\[Crossref\]](#)
6. Duque M, Santos L, Ribeiro S, Cattré D. Anesthesia and Brugada syndrome: a 12-year case series. *J Clin Anesth* 2017; 36: 168-73. [\[Crossref\]](#)
7. Sorajja D, Ramakrishna H, Poterack AK, Shen WK, Mookadam F. Brugada syndrome and its relevance in the perioperative period. *Ann Card Anaesth* 2015; 18: 403-13. [\[Crossref\]](#)

8. Staikou C, Chondrogiannis K, Mani A. Perioperative management of hereditary arrhythmogenic syndromes. *Br J Anaesth* 2012; 108: 730-44. [\[Crossref\]](#)
9. Gurbuz Aytuluk H. Cardiac arrest during spinal anaesthesia in a patient with undiagnosed Brugada syndrome. *Eur J Anaesthesiol* 2018; 35: 711-4. [\[Crossref\]](#)
10. Fujiwara Y, Shibata Y, Kurokawa S, Satou Y, Komatsu T. Ventricular tachycardia in a patient with Brugada syndrome during general anesthesia combined with thoracic paravertebral block. *Anesth Analg* 2006; 102: 1590-1. [\[Crossref\]](#)
11. Kloesel B, Ackerman MJ, Sprung J, Narr BJ, Weingarten TN. Anesthetic management of patients with Brugada syndrome: a case series and literature review. *Can J Anaesth* 2011; 58: 824-36. [\[Crossref\]](#)
12. Biricik E, Hatipoğlu Z, Küçükbingöz Ç. Sugammadex in a Patient with Brugada Syndrome. *Turk J Anaesthesiol Reanim.* 2016; 44: 99-101. [\[Crossref\]](#)