

Contents lists available at [ScienceDirect](http://www.sciencedirect.com)

## International Journal of Surgery Case Reports

journal homepage: [www.casereports.com](http://www.casereports.com)

# Oesophageal GIST—A rare breed case report and review of the literature



Kristof Nemeth<sup>a,\*</sup>, Christopher Williams<sup>b</sup>, Majid Rashid<sup>c</sup>, Mark Robinson<sup>b</sup>, Ashraf Rasheed<sup>a</sup>

<sup>a</sup> Department of General Surgery, Royal Gwent Hospital, Newport, United Kingdom

<sup>b</sup> Department of Radiology, Royal Gwent Hospital, Newport, United Kingdom

<sup>c</sup> Department of Pathology, Royal Gwent Hospital, Newport, United Kingdom

## ARTICLE INFO

### Article history:

Received 9 February 2015

Accepted 12 February 2015

Available online 17 February 2015

### Keywords:

Oesophagus

Gastrointestinal stromal tumours

GIST

Oesophagectomy

## ABSTRACT

**INTRODUCTION:** Gastrointestinal stromal tumours (GIST) account for only one percent of all gastrointestinal malignancies.

**PRESENTATION OF CASE:** A 53 year old lady presented to the gastroenterology clinic with iron deficiency anaemia. Oesophagogastroduodenoscopy (OGD) and computed tomography (CT) demonstrated a non-obstructing 7 cm submucosal oesophageal lesion. An oesophagectomy was performed and subsequent histology sections showed a well-circumscribed spindle cell tumour without any cellular atypia. Immunohistochemistry on the tumour was negative for S100 and positive for smooth muscle actin and desmin. C-kit (CD117) showed focal positivity in some of the tumour cells and the overall features were of a gastro-intestinal stromal tumour (GIST).

The patient has been fully compliant with the follow-up arrangements and is disease-free six years after her original operation.

**DISCUSSION:** GISTs are mesenchymal tumours of the gastrointestinal (GI) tract that express the KIT protein. The incidence rate for GIST is 15 cases to one million in the USA.

GISTs in the oesophagus are rare (5%) and their management is surrounded by some debate.

Once the diagnosis has been secured the patient should be evaluated for suitability for surgical resection.

Optimal surgical therapy should aim to achieve complete resection, if possible, without injury to the pseudocapsule surrounding the tumour. Meticulous atraumatic surgical technique is necessary and preoperative biopsies are best to be avoided as they might propagate seeding.

**CONCLUSIONS:** Oesophagectomy with clear resection margins should be the preferred method for surgical treatment combined with the use of novel TKI strategies.

© 2015 The Authors. Published by Elsevier Ltd. on behalf of Surgical Associates Ltd. This is an open access article under the CC BY-NC-ND license (<http://creativecommons.org/licenses/by-nc-nd/4.0/>).

## 1. Introduction

Gastrointestinal stromal tumours (GIST) account for only one percent of all gastrointestinal malignancies. The oesophageal location is considered to be a medical rarity and the gold standard treatment is surgical resection of the tumour.

\* Corresponding author at: St. George's Hospital, Blackshaw Road, SW17 0QT London, United Kingdom. Tel.: +44 742 756 9327.

E-mail address: [nemethkristof.private@gmail.com](mailto:nemethkristof.private@gmail.com) (K. Nemeth).

<http://dx.doi.org/10.1016/j.ijscr.2015.02.023>

2210-2612/© 2015 The Authors. Published by Elsevier Ltd. on behalf of Surgical Associates Ltd. This is an open access article under the CC BY-NC-ND license (<http://creativecommons.org/licenses/by-nc-nd/4.0/>).

## 2. Presentation of case

A 53 year old lady presented to our unit with iron deficiency anaemia. Oesophagogastroduodenoscopy demonstrated a non-obstructing 7 cm submucosal oesophageal lesion which was confirmed by a computed tomography (CT) scan. No other significant pathology was visualised within the thorax or the abdomen. On endoscopic ultrasound (EUS) a regular hypoechoic submucosal lesion was visualised with the likely diagnosis of a leiomyoma, and she was referred for a surgical treatment.

An oesophagectomy was performed via a vertical midline incision with bilateral subcostal extensions for the abdominal phase. A postero-lateral thoracotomy was carried out for the thoracic

phase. The stomach was tubularised and the oesophagectomy was completed via the trans-thoracic route. An end to side oesophago-gastroectomy was carried out. The patient made an unremarkable post-operative recovery.

The histology sections showed a well-circumscribed spindle cell tumour without any cellular atypia and there was no evidence of increased mitotic activity to suggest malignant change.

Immunohistochemistry on the tumour was negative for S100, epithelial markers and neuroendocrine markers.

The stains were tested positive for smooth muscle actin and desmin indicating a smooth muscle origin. There was also focal positivity for C-kit (CD117).

The overall features were consistent with a gastro-intestinal stromal tumour (GIST).

The surveillance protocol consisted of two 3 monthly CT scans followed by three 6 monthly scans and annual scans thereafter. The patient has been fully compliant with the follow-up arrangements and is disease-free six years after her original operation.

### 3. Discussion

GISTs are defined as pleomorphic mesenchymal tumours of the gastrointestinal (GI) tract that express the KIT protein (CD 117-protooncogene) and often also CD34 (human progenitor cell antigen) on immunohistochemistry [1,4].

The incidence rate for GIST is 15 cases to one million in the USA. Similar incidence rates have been reported in studies from Europe [1–3].

The stomach (50–60%) is most commonly affected followed by the small intestine (30–40%). The colon and rectum may be involved in 5–10% of the cases. GISTs in the oesophagus are rare (5%) and its management is surrounded by some debate (see Table 1) [1–3,13,19,20].

The clinical presentation of GIST is very variable and dependant on the size of the tumour and its localisation [1,2].

The symptoms are often unspecific. Dysphagia, obstruction (10–30%), gastrointestinal bleeding (about 50%) and abdominal pain (20–50%) are most common [2,3].

Twenty percent of tumours are incidental findings at endoscopy, radiological imaging or surgery for other reasons [1,2].

In our case the OGD was requested for iron deficiency anaemia.

In the further evaluation of GIST, both radiological and endoscopic imaging techniques have a central role.

Generally, CT is the most useful method of assessing gastrointestinal stromal tumours and is considered to be the reference diagnostic and staging modality. Alternatively magnetic resonance imaging (MRI) can be considered (Fig. 1).

GISTs can be incidental findings at endoscopy performed for other reasons [3,16].

EUS is a valuable adjunct to the diagnostic work-up of stromal tumours. The main aim is to define the mass and its relationship within the layers of the bowel wall [17].

The use of EUS with fine-needle aspiration biopsy is a controversial technique.

The general recommendation until now was against such a practice, and it has been recommended to minimise the risk of metastatic seeding by aiming for a R0 resection instead of taking biopsies of the tumour. The latest guideline update of the NCCN on the management of GIST (April 2010) states that biopsy is generally necessary when planning preoperative therapy for primary GIST.

This probably reflects the fact that GISTs are often diagnosed after image guided biopsy on patient with an abdominal mass of unknown origin [15,16].

In our approach of making the diagnosis, we utilised EUS for local staging but have refrained from taking biopsies in order to prevent tumour rupture and seeding.

Once biopsies have been taken or the GIST has been resected a definitive histological diagnosis can be made.

The histological classification is according to the predominant cell type, either spindle cell type (70–80%) or epithelioid type (20–30%) [1–3] Fig. 2.

GISTs are KIT-expressing (tyrosine kinase receptor – CD117) tumours. About 95% of the gastrointestinal stromal tumours, are characterised by the CD117 antigen, which is considered to be a marker with high sensitivity and specificity [2,3].

Pathohistology might also help with the risk stratification of patients although the biological behaviour of GISTs is difficult to predict.

An international consensus paper from 2002, suggested tumour size and mitotic index as the two most important prognostic features. Tumour necrosis, nuclear atypia and degree of staining for CD117 do not reliably indicate the malignant potential of GISTs [1,3,14].

Once the diagnosis has been secured the patient should be evaluated for suitability for surgical resection.

Even in the era of imatinib mesylate, a tyrosine kinase inhibitor, the preferred management of GIST is still surgical. In the absence of metastatic disease, complete surgical excision is the treatment of choice.

In order to provide optimal surgical management, the following characteristics of GISTs should be considered:

First, GISTs often metastasise to the liver and peritoneum. This is believed to be secondary to tumour rupture resulting in mesenteric seeding which is common and can also lead to hepatic or mesenteric recurrence after apparently complete resection [1,2].

Lymph node metastases on the other hand are rare, hence, lymphadenectomy is unnecessary and should not be carried out routinely.

Second, GISTs tend to grow towards the abdominal cavity, away from the intestinal lumen.

Third, GISTs do not tend to invade adjacent structures. These tumours tend to be discrete masses surrounded by a pseudocapsule.

Finally, GISTs are very fragile and rupture easily, making the risk of peritoneal dissemination high. Especially, large GISTs can have a necrotic centre, which makes the tumour prone to rupture during operative manipulation.

Optimal surgical therapy should acknowledge the above characteristics of GISTs and aim to achieve complete resection, if possible, without injury to the pseudocapsule surrounding the tumour. Meticulous atraumatic surgical technique is necessary, and preoperative biopsies are best to be avoided as they might propagate seeding.

Successful R0 resection has been shown to be a good prognostic indicator for the development of metastatic disease [2,3,19].

The last important aspect is the adequate symptoms control in a palliative situation. In palliative therapy for bleeding or pain an incomplete resection can be accepted [3,8,9,20].

The aim should be a maximum reduction of tumour mass, including liver metastases.

Our case was unique as the GIST was localised to the oesophagus and this brings a few challenges with it.

Most importantly the oesophagus lacks serosal covering, so the risk of breakage is extremely high, and oesophageal resection is a technique that involves high morbidity and mortality [19].

Blum et al. [20] analysed four cases, all in the distal oesophagus, arguing for the oesophagectomy alternative to enucleation for large

tumours and those close to the gastroesophageal junction (GEJ). Small tumours (<2 cm), confined to the oesophageal wall in patients at high risk, could be locally resected as long as negative resection margins are obtained.

Enucleation is not a therapeutic option except for groups with extensive experience.

Local resection of tumours <2 cm, provided that we can ensure an R0 resection, or a standard resection in tumours >2 cm [13].

Where curative surgery is not feasible, or in patients who develop recurrent metastatic disease, imatinib is now the first line treatment.

In 2010, the National Comprehensive Cancer Network (NCCN) updated their clinical practice guidelines on the management of patients with GIST. As there is now effective treatment for recurrent or metastatic GIST, the NCCN recommends CT scans of the abdomen and pelvis with IV contrast every 3–6 months during the first 2–5 postoperative years and yearly thereafter.

The ESMO Guidelines Working Group approved clinical guidelines for diagnosis, treatment and follow-up of GIST in 2006 and 2008. The guidelines were updated recently in 2010.

The published guidelines partly diverge in their recommendations, and country specific health regulations may interfere with their implementation.

#### 4. Conclusion

The management of GIST has significantly changed over the last few decades. The imatinib and other inhibitors of tyrosine kinases (TKI) have revolutionised the treatment of these mesenchymal tumours. Oesophagectomy with clear resection margins should be the preferred method for surgical treatment combined with the use of novel TKI strategies.

Preoperative biopsies can not be recommended as they increase the chances of mesenteric seeding.

Given the rarity of oesophageal disease establishing regional networks and regional or national registries should provide surgeons with better information on GIST.

#### Funding

No funding has been received.

#### Conflict of interest statement

The authors have no competing interest to declare.

#### Authors contribution

KN has written the case report.

CW has co-written the case report.

MR provided data analysis and support with the histology slides.

MRo has provided data analysis and support with interpretation of imaging.

AR has co-written the case report.

#### Consent

Written informed consent was obtained from the patient for publication of this case report and accompanying images. A copy of the written consent is available for review by the Editor-in-Chief of this journal on request.

#### Appendix A.

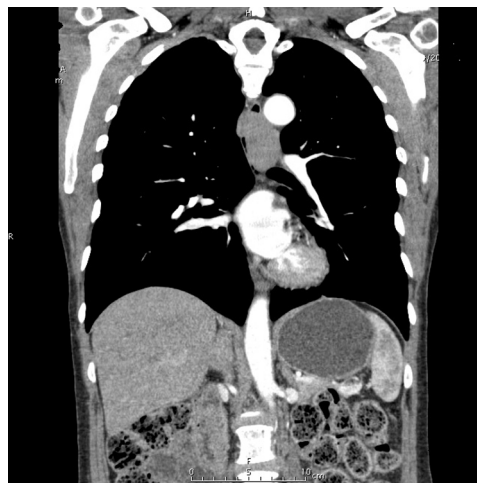
**Table 1**

Literature review of major case series (*n* > 50) has shown that oesophageal GISTs are rare.

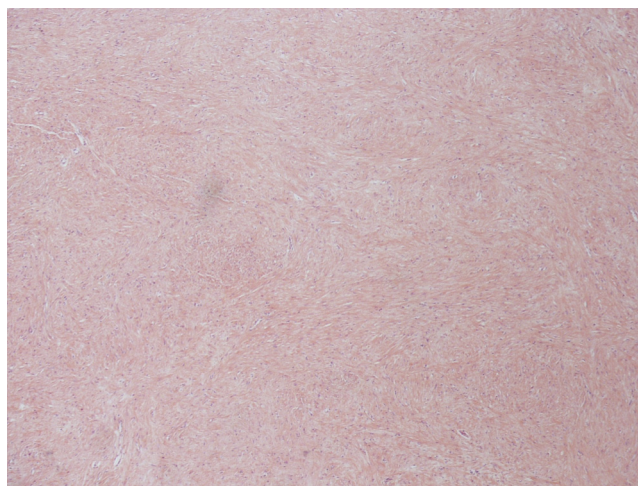Author	Year	<i>n</i>	Oe	F/U	DFS/S	Rc
Dematteo et al. [4]	2000	200	2	24	51/55	40%
Langer et al. [5]	2003	39	1	2.2 years	100/65 0/0	26%
Martin et al. [6]	2005	162	1	42	68/-	26%
Richter et al. [7]	2008	54	1	-	76/65	21%
Ahmed et al. [8]	2008	185	16	6.8 years	-/100 -/55	11%
Das et al. [9]	2009	50	1	-	100/100 45/58	-
Monges et al. [10]	2010	591	4	Registry	-/-	-/-
Bülbül Doğusoy [11]	2012	1161	5	Registry	-/-	-/-
Siu et al. [12]	2013	93	3	58	64/69	16%
Rutkowski et al. [13]	2013	161	5	104	65/95 DFS/DSS	23%

(*n* – numbers of patients, Oe – number of oesophageal cases within cohort, F/U – period, DFS – disease-free survival, S – survival, Rc – recurrence, DSS – disease-specific survival).

#### Appendix B.



**Fig. 1.** Coronal views of the staging CT showing significant thickening of the mid-oesophagus starting at the level of the aortic arch.



**Fig. 2.** Histopathologic image of the oesophageal gastrointestinal stromal tumor (GIST). H & E stain.

## References

- [1] M. Stamatakos, E. Douzinas, C. Stefanaki, P. Safioleas, E. Polyzou, G. Levidou, M. Safioleas, Gastrointestinal stromal tumor, *World J. Surg. Oncol.* 7 (1) (2009) 61, <http://dx.doi.org/10.1186/1477-7819-7-61>.
- [2] S. Dirnhofer, S. Leyvraz, Current standards and progress in understanding and treatment of GIST, *Swiss Med. Wkly.* 139 (February (7–8)) (2009) 90–102, doi: smw-12166.
- [3] K. Sandrasegaran, A. Rajesh, J. Rydberg, D.A. Rushing, F.M. Akisik, J.D. Henley, Gastrointestinal stromal tumors: clinical, radiologic, and pathologic features, *AJR Am. J. Roentgenol.* 184 (March (3)) (2005) 803–811.
- [4] R.P. DeMatteo, J.J. Lewis, D. Leung, S.S. Mudan, J.M. Woodruff, M.F. Brennan, Two hundred gastrointestinal stromal tumors: recurrence patterns and prognostic factors for survival, *Ann. Surg.* 231 (2000) 51–58.
- [5] C. Langer, B. Gunawan, P. Schüller, W. Huber, L. Füzesi, H. Becker, Prognostic factors influencing surgical management and outcome of gastrointestinal stromal tumours, *Br. J. Surg.* 90 (2003) 332–339.
- [6] J. Martín, A. Poveda, A. Llombart-Bosch, R. Ramos, J.A. López-Guerrero, J. García del Muro, Spanish Group for Sarcoma Research, et al., Deletions affecting codons 557–558 of the c-KIT gene indicate a poor prognosis in patients with completely resected gastrointestinal stromal tumors: a study by the Spanish Group for Sarcoma Research (GEIS), *J. Clin. Oncol.* 23 (2005) 6190–6198.
- [7] K.K. Richter, C. Schmid, M. Thompson-Fawcett, U. Settmacher, A. Altendorf-Hofmann, Long-term follow-up in 54 surgically treated patients with gastrointestinal stromal tumours, *Langenbecks Arch. Surg.* 393 (2008) 949–955.
- [8] I. Ahmed, N.T. Welch, S.L. Parsons, Gastrointestinal stromal tumours (GIST) – 17 years experience from Mid Trent Region (United Kingdom), *Eur. J. Surg. Oncol.* 34 (2008) 445–449.
- [9] A. Das, R. Wilson, A.V. Biankin, N.D. Merrett, Surgical therapy for gastrointestinal stromal tumours of the upper gastrointestinal tract, *J. Gastrointest. Surg.* 13 (2009) 1220–1225.
- [10] G. Monges, S. Bisot-Locard, J.Y. Blay, et al., The estimated incidence of gastrointestinal stromal tumors in France. Results of PROGIST study conducted among pathologists, *Bull. Cancer* 97 (March (3)) (2010) E16–E22, <http://dx.doi.org/10.1684/bdc.2010.1041>.
- [11] G. Bülbül Doğusoy, Turkish GIST Working Group. Gastrointestinal stromal tumors: a multicenter study of 1160 Turkish cases, *Turk. J. Gastroenterol.* 23 (June (3)) (2012) 203–211.
- [12] J. Siu, M. Lim, J. Fischer, et al., Ten-year review of gastrointestinal stromal tumours at a tertiary referral hospital in New Zealand, *ANZ J. Surg.* (2013), <http://dx.doi.org/10.1111/ans.12429>, December 11.
- [13] P. Rutkowski, A. Gronchi, P. Hohenberger, et al., Neoadjuvant imatinib in locally advanced gastrointestinal stromal tumors (GIST): the EORTC STBSG experience, *Ann. Surg. Oncol.* 20 (September (9)) (2013) 2937–2943, <http://dx.doi.org/10.1245/s10434-013-3013-7>, Epub 2013 June 13.
- [14] G.F. Samelis, K.A. Ekmektzoglou, G.C. Zografos, Gastrointestinal stromal tumours: clinical overview, surgery and recent advances in imatinib mesylate therapy, *Eur. J. Surg. Oncol.* 33 (October (8)) (2007) 942–950, Epub 2006 Dec 28.
- [15] A.D. Levy, H.E. Remotti, W.M. Thompson, L.H. Sobin, M. Miettinen, Gastrointestinal stromal tumors: radiologic features with pathologic correlation, *Radiographics* 23 (March–April (2)) (2003) 283–304, 456; Quiz 532.
- [16] D.T. Efron, K.D. Lillemoe, The current management of gastrointestinal stromal tumors, *Adv. Surg.* 39 (2005) 193–221.
- [17] A. Săftoiu, Endoscopic ultrasound-guided fine needle aspiration biopsy for the molecular diagnosis of gastrointestinal stromal tumors: shifting treatment options, *J. Gastrointest. Liver Dis.* 17 (June (2)) (2008) 131–133.
- [18] J.A. Fernández, M.E. Sánchez-Cánovas, P. Parrilla, Controversies in the surgical treatment of primary gastrointestinal stromal tumours (GIST), *Cir. Esp.* 88 (August (2)) (2010) 69–80, <http://dx.doi.org/10.1016/j.ciresp.2010.01.007>, Epub 2010 May 24.
- [19] M.G. Blum, K.Y. Bilimoria, J.D. Wayne, A.L. De Hoyos, M.S. Talamonti, B. Adley, Surgical considerations for the management and resection of esophageal gastrointestinal stromal tumors, *Ann. Thorac. Surg.* 84 (2007) 1717–1723.

## Open Access

This article is published Open Access at [sciedirect.com](http://sciedirect.com). It is distributed under the [IJSCR Supplemental terms and conditions](#), which permits unrestricted non commercial use, distribution, and reproduction in any medium, provided the original authors and source are credited.