



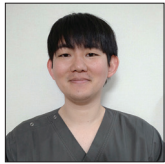Original Article

# Japanese herbal *Kampo* medicine, Keishibukuryogan, for chronic subdural hematoma – Prospective observational study

Masahito Katsuki, Shin Kawamura, Akihito Koh

Department of Neurosurgery, Itoigawa General Hospital, Itoigawa, Niigata, Japan.

E-mail: \*Masahito Katsuki - ktk1122nigt@gmail.com; Shin Kawamura - skmile31@gmail.com; Akihito Koh - vesper2017@yahoo.co.jp



**\*Corresponding author:**

Masahito Katsuki,  
Department of Neurosurgery,  
Itoigawa General Hospital,  
Itoigawa, Niigata, Japan.

ktk1122nigt@gmail.com

Received : 13 May 2022  
Accepted : 30 June 2022  
Published : 15 July 2022

DOI  
10.25259/SNI\_455\_2022

Quick Response Code:



## ABSTRACT

**Background:** Pharmacological treatment for chronic subdural hematoma (CSDH) recurrence prevention after surgery is under debate. CSDH may be related to *suidoku* (fluid disturbance) from the Japanese herbal *kampo* perspective. *Goreisan* (GRS) treats *suidoku* and is used to prevent a postoperative recurrence. However, not all CSDHs are liquid, and some have structures such as trabecula, hematoma, and clots, suggesting *oketsu* (blood stasis). Therefore, we prospectively investigated the *keishibukuryogan* (KBG) effectiveness, which treats *oketsu*, for CSDH recurrence prevention and hematoma resolution compared to GRS.

**Methods:** We prospectively prescribed KBG 7.5 g/day for 12 CSDH patients after burr-hole surgery. As a control cohort, we retrospectively collected 48 patients treated by GRS 7.5 g/day. The recurrence within 1 month and the hematoma thickness after 1 month were evaluated.

**Results:** The median age was 84 years old. All the patients' symptoms improved after surgery. The median preoperative midline shift and mean hematoma thicknesses were 6.0 mm and 23.75 mm. Those at 1 month were 2.0 mm and 11.43 mm. The recurrence rate was not significantly different between the KBG cohort (1 of 12) and the GRS cohort (4 of 48) ( $P = 0.999$ ). The KBG's noninferiority to GRS regarding the hematoma thickness at 1 month was statistically proven; KBG (12.26 mm) and GRS (11.20 mm).

**Conclusion:** The recurrence rate at 1 month was not different between the KBG and GRS cohorts. The hematoma thickness at 1 month in the KBG cohort was not statistically inferior to that in the GRS cohort.

**Keywords:** Chronic subdural hematoma, *Goreisan*, Japanese herbal *kampo* medicine, *Keishibukuryogan*, Recurrence

## INTRODUCTION

Chronic subdural hematoma (CSDH) is common among the aged population, with 13.1–20.6/100,000 individuals in the general population in Japan.<sup>[4]</sup> CSDH is, usually, associated with good recovery with burr-hole irrigation and postoperative drainage under local anesthesia. However, the postoperative recurrence rate is not low and has been reported as 8–22%.<sup>[9,12,15]</sup> In addition to devising a surgical technique,<sup>[1,6]</sup> various medication to prevent postoperative recurrence is reported.<sup>[19]</sup>

In Japan, Japanese herbal *kampo*, *goreisan* (GRS), is often used postoperatively to prevent CSDH recurrence<sup>[3,5]</sup> and headache.<sup>[7,8]</sup> GRS mainly acts as an aquaporin-4 inhibitor, improving

This is an open-access article distributed under the terms of the Creative Commons Attribution-Non Commercial-Share Alike 4.0 License, which allows others to remix, transform, and build upon the work non-commercially, as long as the author is credited and the new creations are licensed under the identical terms.

©2022 Published by Scientific Scholar on behalf of Surgical Neurology International

*suidoku* status from the *kampo* perspective. *Suidoku* status is defined as fluid disturbance such as edema, dehydration, and dislocation. CSDH is regarded as a disease related to *suidoku* status, because it is hypothesized that the role of the osmotic ingress of the cerebrospinal fluid into the cavity formed by the inner membrane of hematoma.<sup>[3]</sup> The CSDH is liquid, making it reasonable to assume that CSDH is related to *suidoku* status.

However, not all CSDHs are necessarily liquid, and some are separated or have structures such as trabecula, hematoma, and clots.<sup>[6]</sup> Another important status from the *kampo* perspective, *oketsu* status, is defined as blood stasis. *Oketsu* status is related to the multiple aspects of hemodynamic disorders brought on by quantitative and qualitative changes, such as stagnation, insufficient capillary circulation, and venous congestion.<sup>[17]</sup> *Oketsu* is also related to traumatic pain and hemorrhage.<sup>[13,18]</sup> CSDH can be regarded as a disease related to *oketsu* status due to the continuous inflammation and bleeding around the dural border cell layers and hematoma stagnation.<sup>[14]</sup> *Keishibukuryogan* (KBG) is one of the Japanese herbal *kampo* medicines, and it improves *oketsu* status.

We hypothesized that CSDH can be regarded as a disease related to *suidoku* and *oketsu* status and that KBG has a noninferior effect to that of GRS for postoperative CSDH resolution. Therefore, we prospectively prescribed KBG as postoperative medication for recurrence prevention and facilitating postoperative CSDH resolution and compared the efficacy of KBG and GRS.

## MATERIALS AND METHODS

### Study population and general management

From April 2021 to May 2022, we prospectively collected 12 consecutive CSDH patients who underwent burr-hole surgery under local anesthesia. The CSDH diagnosis was based on the clinical history and the presence of CSDH on computed tomography (CT) and its compression against the brain. Surgical intervention was performed when hematoma thickness was sufficient to compress the brain and when the neurological symptoms were obvious and due to the CSDH. In patients with bilateral hematomas, the operation was performed on both sides. However, when the hematoma on one side was much larger than that on the other side, and the neurological symptoms seemed to be due to the more massive hematoma, we performed burr-hole surgery unilaterally on the responsible side.

We performed single burr-hole surgery with irrigation using artificial cerebrospinal fluid and postoperative drainage under local anesthesia with sedation for all the patients. We made a burr hole on the part of the cranium, where the hematoma was the thickest. After irrigating the hematoma cavity, we inserted the drainage tube toward the frontal cranium. The

drainage was removed within 2 days after the operation. All 12 patients took the KBG 7.5 g/day postoperatively at least for a month. Antithrombotic drugs were not ceased during the perioperative period.

As a control cohort against the KBG cohort, we also retrospectively collected 48 consecutive CSDH patients treated by GRS in our hospital from April 2017 to March 2021. The surgical procedure and perioperative management were the same in those treated with KBG. The 48 patients took GRS 7.5 g/day postoperatively at least for a month.

Each patient provided written informed consent for their inclusion in this study, which was approved by the hospital's research ethics committee (approval number 2021–7). This prospective study was performed following the Declaration of Helsinki.

### Clinical variables and outcomes

We collected data regarding physiological symptoms and medical history on admission; age, sex, symptoms, laterality of the hematoma, presence of habitual drinking (150 g alcohol/week), platelet count, prothrombin time-international normalized ratio, activated partial thromboplastin time, the use of antithrombotic drugs, and the recurrence. We also investigated the hematoma density,<sup>[10]</sup> pre- and post-operative (after 1 month) midline shift, and pre- and post-operative hematoma thickness on the CT images. Hematoma thickness was measured on the coronal slice with the maximum value. Regardless of unilateral or bilateral hematoma, the midline shift was determined by measuring the distance from the midline on the axial CT scan to the midline structures, such as the falx or the third ventricle. In patients with bilateral hematoma, the left and right thicknesses were measured, and the average value was used in the statistical analysis.<sup>[6]</sup> We divided the hematoma characteristics into two classifications as fluid and hematoma types. We determined it, considering the intraoperative findings of the hematoma efflux and solidity during the irrigation procedure, absolutely based on whether the postoperative CT image did not show any rest of the hematoma, suggesting the completely replaced cavity by artificial CSF or showed the rest of the hematoma.

As outcomes, the recurrence within 1 month and the hematoma thickness after 1 month were evaluated. No patients recurred their CSDH after 1 month in the two cohorts.

### Statistical analysis

Results were presented as median (interquartile range) for the variables without normal distribution and mean  $\pm$  standard deviation for the variables with normal distribution. The Shapiro–Wilk test confirmed the normal distribution.

Levene's test confirmed the equal variance. We compared the KBG and GRS cohorts regarding recurrence rate within 1 month using Fisher's exact test. We also investigated the KBG's noninferiority to the GRS regarding the recurrence rate and the hematoma thickness at 1 month. We calculated the sample size needed to prove the KBG's noninferiority to GRS, using the true recurrence ratio and mean hematoma thickness difference between the KBG cohort and the GRS cohort, its mean standard deviation of the two cohorts, alpha error (0.05), and beta error (0.20). The margins were set as 10% regarding the recurrence rate and 5 mm regarding the hematoma thickness at 1 month. We conducted these analyses using version 28.0.0 of SPSS software (IBM, NY, USA). A one-sided  $P < 0.05$  was considered statistically significant.

## RESULTS

### General characteristics

Table 1 shows the characteristics of 60 CSDH patients (12 treated by KBG and 48 by GRS). Eighteen women and 42 men were included in the study. The median age was 84 (47–99) years old. Thirty-eight (63%) patients had

paresis, 11 (18%) had disturbance of consciousness, 2 (3%) had dementia, 7 (12%) had a headache, and 2 (3%) had convulsion as symptoms. Seven (12%) patients had bilateral CSDHs. The preoperative CT showed 18 (30%) low-density hematoma, 12 (20%) isodensity hematoma, 20 (22%) high-density hematoma, and 10 (17%) mixed density hematoma. The median preoperative midline shift and hematoma thickness were 6 (1.0–23.0) mm and  $23.75 \pm 5.69$  mm. The postoperative (1 month) midline shift and hematoma thickness were 2.0 (0.1–32.1) mm and  $11.43 \pm 5.73$  mm. The fluid CSDHs were observed in 37 (62%) patients. The recurrences within 1 month were confirmed in five patients.

### Statistical analysis of the recurrence rate and the hematoma thickness at 1 month

The recurrence rate was not significantly different between the KBG cohort (1 of 12, 8%) and the GRS cohort (4 of 48, 8%) ( $P = 0.999$  by Fisher's exact test). The noninferiority of KBG regarding recurrence rate to GRS could not be proven, because the needed sample number was 99 individuals in each cohort.

The mean hematoma thickness at 1 month was not significantly different between the KBG cohort ( $12.26 \pm 6.35$ )

**Table 1:** Characteristics of the patients and dataset.

Variables	Total (n=60)	KBG (n=12)	GRS (n=48)
Age	84 (47–99)	77 (56–99)	86 (47–97)
Women: Men (%Women)	18:42 (30%)	1:11 (9%)	17:31 (55%)
Symptoms			
Paresis	38 (63%)	6 (50%)	32 (67%)
Disturbance of consciousness	11 (18%)	2 (17%)	9 (19%)
Dementia	2 (3%)	2 (17%)	0
Headache	7 (12%)	2 (17%)	5 (10%)
Convulsion	2 (3%)	0	2 (4%)
Left: Right: Bilateral	30:23:7 (50%:38%:12%)	4:5:3 (33%:42%:25%)	26:18:4 (54%:38%:8%)
Habitual drinking (150 g alcohol/week)	23 (39%)	8 (13%)	15 (25%)
Platelet count ( $\times 10^5/\mu\text{L}$ )	22.2 (10.1–42.4)	21.9 (10.1–42.4)	22.2 (14.6–31.0)
Prothrombin time-international normalized ratio	1.02 (0.87–3.05)	1.05 (0.92–2.24)	1.02 (0.87–3.05)
Activated partial thromboplastin time (sec)	28.6 (23.3–53.2)	28.6 (23.3–53.2)	29.4 (24.5–33.6)
Use of antiplatelet	16 (27%)	3 (25%)	13 (27%)
Use of anticoagulant	6 (10%)	1 (8%)	5 (10%)
Computed tomography findings			
Low density	18 (30%)	3 (25%)	15 (31%)
Iso density	12 (20%)	2 (17%)	10 (21%)
High density	20 (33%)	7 (58%)	13 (27%)
Mixed density	10 (17%)	0	10 (21%)
Preoperative mid line shift (mm)	6.0 (1.0–23.0)	9.0 (1.0–21.0)	6.0 (1.0–23.0)
Preoperative hematoma thickness (mm)	$23.75 \pm 5.69$	$23.35 \pm 7.75$	$23.66 \pm 5.15$
Hematoma characteristics, fluid: hematoma (%fluid)	37:23 (62%)	8:4 (66%)	29:19 (60%)
1-month mid line shift (mm)	2.0 (0.1–32.1)	2.9 (0.1–32.1)	2.0 (0.1–6.5)
1-month hematoma thickness (mm)	$11.43 \pm 5.73$	$12.26 \pm 6.35$	$11.20 \pm 5.62$
Recurrence within 1 month	5 (8%)	1 (8%)	4 (8%)

The results are shown with the number (%) or the median (interquartile range). GRS: *Goreisan*, KBG: *Keishibukuryogan*

and the GRS cohort ( $11.20 \pm 5.62$ ) ( $P = 0.613$  by  $t$ -test). The noninferiority of KBG regarding recurrence rate to GRS was proven, because the needed sample number was 12 individuals in each cohort (the true difference was 1.06 mm and the mean standard deviation was 5.73 mm) [Figure 1].

## DISCUSSION

We, herein, suggest the equivalent efficacy of KBG for postoperative CSDH resolution compared to GRS. The recurrence rate at 1 month was not different between KBG and GRS cohorts. The hematoma thickness at 1 month in KBG cohorts was not inferior to that in GRS cohorts. Our results suggest the possibility of KBG as postoperative medication for recurrence prevention comparable to GRS.

### Medication for CSDH

CSDH is hypothesized to be induced by trauma in dural border cells. The sustained inflammation around dural border cells in CSDH results in outer membrane growth and fluid accumulation. This is one of the most convincing hypotheses regarding the pathogenesis of CSDH. Especially, the outer membrane, which contains layers of fibroblasts and collagen fibers with inflammatory cells, is considered important for driving CSDH growth.<sup>[11]</sup>

From this context of CSDH pathogenesis, several medications have been used as preventive medicine for CSDH recurrence. Atorvastatin, dexamethasone, and tranexamic acid<sup>[21]</sup> were used. CSDH recurs from the theories of inflammation, angiogenesis, exudates, recurrent microbleeds, and local coagulopathy, which are shown by pathologically<sup>[6,14]</sup> and

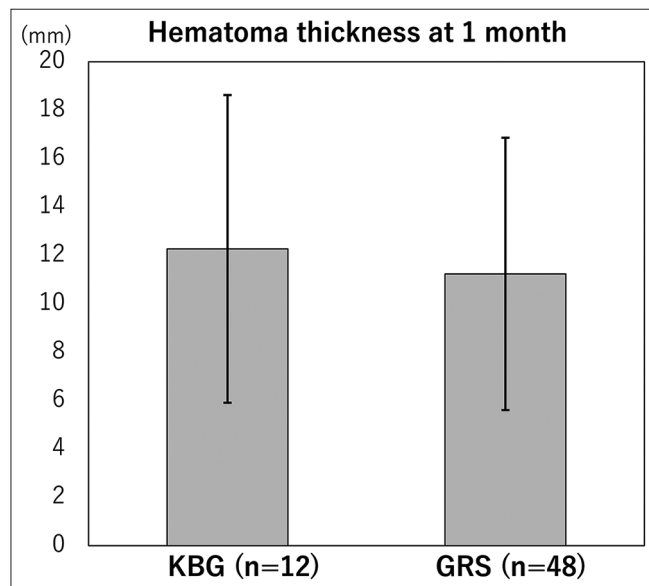
basically.<sup>[19]</sup> Therefore, these medications may have effects from these pathophysiological perspectives. Many previous clinical trials of drugs have been performed on CSDH patients after surgery to improve the recurrence rate. However, few drugs have shown effectiveness, and optimal drug interventions are still being debated.

GRS is often used after burr-hole surgery in Japan, expecting its hydrogogue effect to solve *suidoku* status. Katayama *et al.*<sup>[5]</sup> conducted a prospective randomized trial for 180 CSDH patients over 60 years and evaluated the GRS effect for recurrence prevention. No beneficial effect for overall participants was observed, but their subanalysis revealed that GRS lowered the recurrence rate in patients aged 60–74 years. Fujisawa *et al.*<sup>[3]</sup> could not show the effectiveness of postoperative GRS treatment in their 208 prospectively collected CSDH cohort. However, their subanalysis showed the preventive effect of GRS in 145 patients with homogeneous and separated findings on CT. Yamada and Natori<sup>[20]</sup> could not show the effectiveness of GRS from their 206 prospectively collected CSDH patients. Therefore, it may be difficult to consider CSDH related to only *suidoku* status.

Therefore, from the pathophysiology of CSDH, such as inflammation, microbleeds, and coagulopathy, we consider CSDH not only *suidoku* but also *oketsu* status from the *kampo* perspective. Of course, CSDH cannot be considered as only *oketsu* status-related diseases, but our result of noninferiority of KBG to GRS suggests its possibility. Further studies on the classification of CSDH from the *kampo* perspective are needed.

### Oketsu status and KBG

Previously, two reports on *oketsu* status and KBG treatment regarding neurosurgical diseases have been reported. Osawa *et al.*<sup>[16]</sup> used KBG for 21 intracerebral hemorrhage (ICH) patients and investigated the hematoma resolution speed compared to the 32 nonKBG control cohort. The hematoma clearance rate at 1 and 2 weeks was better in the KBG cohort than those in the nonKBG cohort. They hypothesized that KBG has effects of anti-inflammation, capillary dilatation, free radical production prohibition, and endothelial function improvement, which led to early hematoma clearance. Fujii *et al.*<sup>[2]</sup> used KBG and sennoside for 6 ICH patients and investigated the residual hematoma volume at 1 week. They emphasized the theory that congested blood, including ICH, related to *oketsu* status is finally resolved and drained through the gastrointestinal tract from the *kampo* perspective. Therefore, they used sennoside in addition to KBG and showed that the earlier improvement of bowel movement tended to show a smaller hematoma residual ratio. KBG is also empirically used for subcutaneous hematoma due to head injury.



**Figure 1:** Hematoma thickness at 1 month. The noninferiority of *keishibukuryogan* (KBG) to *goreisan* (GRS) was statistically proved.

KBG ameliorates endothelial function induced by oxidative stress, coagulopathy, hyperviscosity from anti-platelet aggregation, lipid metabolism, regulation of systemic leptin level and lipid metabolism, inflammatory factors, macrophage infiltration, hyperplasia, tissue fibrosis, and sclerosis caused by TGF- $\beta$ 1 and fibronectin, dysfunction of regulated cell deaths, and ovarian hormone imbalance. Clinically, KBG is often used for deep venous thrombosis, rheumatoid arthritis, atopic dermatitis, endometriosis, and hot flash.<sup>[17]</sup> Considering that these diseases are related to coagulopathy and inflammation, KBG would be effective for CSDH from the described pathophysiology, inflammation, bleeding, and coagulopathy. Further, basic and clinical research on KBG is needed.

### Limitation

Although statistical noninferiority was proven about hematoma thickness at 1 month, our study's sample size was small. We hoped to show the noninferiority of recurrence rate between KBG and GRS cohorts, but the needed sample number was 100 in each cohort. Furthermore, the hematoma type, such as fluid, and solid, with some structures, should be investigated to consider, whether the CSDH is related to *suidoku* or *oketsu* status. Finally, we did not collect the species of the outer membrane for pathological analysis. Besides, we did not perform the tongue diagnosis which is very useful to diagnose *oketsu* from the *kampo* perspective.<sup>[13]</sup> Therefore, further study on CSDH from the *kampo* perspective is needed.

### CONCLUSION

The recurrence rate at 1 month was not different between KBG and GRS cohorts. In addition, the hematoma thickness at 1 month in KBG cohorts was not inferior to that in GRS cohorts.

### Declaration of patient consent

The authors certify that they have obtained all appropriate patient consent.

### Financial support and sponsorship

Nil.

### Conflicts of interest

There are no conflicts of interest.

### REFERENCES

1. Di Cristofori A, Remida P, Patassini M, Piergallini L, Buonanno R, Bruno R, *et al.* Middle meningeal artery

embolization for chronic subdural hematomas. A systematic review of the literature focused on indications, technical aspects, and future possible perspectives. *Surg Neurol Int* 2022;13:94.

2. Fujii S, Kiyokawa J, Tamada N, Yoshimura M, Hirota S, Yamamoto S, *et al.* Administration of keishibukuryogan in combination with sennoside may accelerate absorption of intracerebral hematomas: Evaluation of six cases (Japanese). *J Neurosurg Kampo Med* 2017;3:41-7.
3. Fujisawa N, Oya S, Yoshida S, Tsuchiya T, Nakamura T, Indo M, *et al.* A prospective randomized study on the preventive effect of Japanese Herbal Kampo medicine *goreisan* for recurrence of chronic subdural hematoma. *Neurol Med Chir (Tokyo)* 2021;61:12-20.
4. Karibe H, Kameyama M, Kawase M, Hirano T, Kawaguchi T, Tominaga T. Epidemiology of chronic subdural hematomas. *No Shinkei Geka* 2011;39:1149-53.
5. Katayama K, Matsuda N, Kakuta K, Naraoka M, Takemura A, Hasegawa S, *et al.* The effect of *Goreisan* on the prevention of chronic subdural hematoma recurrence: Multi-center randomized controlled study. *J Neurotrauma* 2018;35:1537-42.
6. Katsuki M, Kakizawa Y, Wada N, Yamamoto Y, Uchiyama T, Nakamura T, *et al.* Endoscopically observed outer membrane color of chronic subdural hematoma and histopathological staging: White as a risk factor for recurrence. *Neurol Med Chir (Tokyo)* 2020;60:126-35.
7. Katsuki M, Kawamura S, Kashiwagi K, Koh A. Medication overuse headache successfully treated by three types of Japanese Herbal Kampo medicine. *Cureus* 2021;13:e16800.
8. Katsuki M, Narita N, Matsumori Y, Ishida N, Watanabe O, Cai S, *et al.* Kampo (Japanese herbal) medicine for primary headache as an acute treatment -a retrospective investigation in Kesenuma City Hospital during five years. *J Neurosurg Kampo Med* 2022;7:In press.
9. Katsuki M, Yasuda I, Narita N, Ozaki D, Sato Y, Kato Y, *et al.* Chronic subdural hematoma in patients over 65 years old: Results of using a postoperative cognitive evaluation to determine whether to permit return to driving. *Surg Neurol Int* 2021;12:212.
10. Lanksch W, Kazner E, Grumme T. *Computed Tomography in Head Injuries*. Berlin, Heidelberg: Springer; 1979.
11. Lee KS. History of chronic subdural hematoma. *Korean J Neurotrauma* 2015;11:27-34.
12. Mori K, Maeda M. Surgical treatment of chronic subdural hematoma in 500 consecutive cases: Clinical characteristics, surgical outcome, complications, and recurrence rate. *Neurol Med Chir (Tokyo)* 2001;41:371-81.
13. Morita A, Murakami A, Noguchi K, Watanabe Y, Nakaguchi T, Ochi S, *et al.* Combination image analysis of tongue color and sublingual vein improves the diagnostic accuracy of *Oketsu* (Blood Stasis) in Kampo Medicine. *Front Med (Lausanne)* 2021;8:790542.
14. Nagahori T, Nishijima M, Takaku A. Histological study of the outer membrane of chronic subdural hematoma: Possible mechanism for expansion of hematoma cavity. *Neurol Surg* 1993;21:697-701.
15. Nakaguchi H, Tanishima T, Yoshimasu N. Relationship between drainage catheter location and postoperative recurrence of

- chronic subdural hematoma after burr-hole irrigation and closed-system drainage. *J Neurosurg* 2000;93:791-5.
16. Osawa SI, Endo H, Kawamura T, Tominaga T. Safety and efficacy of Keishi-Bukuryo-Gan in patients with spontaneous intracerebral hemorrhage during the acute period: CT image-based analysis of the clearance of hematoma. *No Shinkei Geka* 2018;46:763-70.
  17. Tanaka K, Chiba K, Nara K. A review on the mechanism and application of keishibukuryogan. *Front Nutr* 2021;8:760918.
  18. Terasawa K. Evidence-based reconstruction of kampo medicine: Part II-The concept of sho. *Evid Based Complement Alternat Med* 2004;1:119-23.
  19. Wang X, Song J, He Q, You C. Pharmacological treatment in the management of chronic subdural hematoma. *Front Aging Neurosci* 2021;13:684501.
  20. Yamada T, Natori Y. Prospective study on the efficacy of orally administered tranexamic acid and Goreisan for the prevention of recurrence after chronic subdural hematoma burr hole surgery. *World Neurosurg* 2020;134:e549-53.
  21. Yu W, Chen W, Jiang Y, Ma M, Zhang W, Zhang X, *et al.* Effectiveness comparisons of drug therapy on chronic subdural hematoma recurrence: A Bayesian network meta-analysis and systematic review. *Front Pharmacol* 2022;13:845386.

**How to cite this article:** Katsuki M, Kawamura S, Koh A. Japanese herbal *Kampo* medicine, Keishibukuryogan, for chronic subdural hematoma – Prospective observational study. *Surg Neurol Int* 2022;13:307.