



Chronic exertional compartment syndrome of the forearm: a systematic review

Francesco Smeraglia¹

Federico Tamborini²

Leonardo Garutti²

Andrea Minini²

Morena A. Basso¹

Mario Cherubino²

- The aim of this systematic review is to understand which surgical procedure provides better results in terms of pain relief and function in the treatment of chronic exertional compartment syndrome (CECS) of the forearm.
- We searched Medline (PubMed), Web of Science, Embase and Scopus databases on 8 July 2020. Twelve studies were included in this review.
- We assessed the quality of the studies using the Coleman Methodological Score.
- Data on demographic features, operative readings, diagnostic methods, follow-up periods, type and rates of complications, survivorship of the procedure, return to sport activity, and outcome measures were recorded.
- In conclusion, compared to the other techniques, endoscopic fasciotomy delivers similar success rates and lower incidence of complications.

Keywords: chronic; compartment; exertional; forearm

Cite this article: *EFORT Open Rev* 2021;6:101–106.

DOI: 10.1302/2058-5241.6.200107

Introduction

The aetiology of chronic exertional compartment syndrome (CECS) remains debated. Today, the most accredited theory reports that a non-compliant fascia stiffens the compartment that fails to adapt to increased blood flow and muscle volume during exercise.¹ CECS of the lower limb is well reported;² whereas CECS of the forearm is a rare condition in the general population, but can be observed in motorcycling racers, climbers, and rowers.³

Clinically, the symptomatology is characterized by forearm pain, stiffness, decreased muscle strength, and

paraesthesias. Symptoms disappear when the exercise is stopped. CECS has been described to occur bilaterally in 70% to 100% of patients.³ Conservative treatment is effective but mainly consists of suspending the trigger activity, which is generally rejected by patients.²

Four compartments are usually described in the forearm: superficial volar compartment, deep volar compartment, lateral compartment, and dorsal compartment.⁴ Open fasciotomy has been considered the gold standard for its ability to release all the compartments. However, the invasive nature of open procedures affects high-level athletes with lengthy periods away from competition. It is for this reason that mini-open techniques were proposed to allow for faster recovery and reduce secondary scar formation. More recently, endoscopic techniques have been proposed by different authors,⁵ which guarantee continuous visual control during the surgical procedure.

This is a comprehensive review of studies published on the management of patients with CECS, which aims to investigate which surgical techniques provide better outcomes, with fewer serious or major side effects and faster return to sport.

Methods

A systematic review of the literature was performed according to the Preferred Reporting Items for Systematic Reviews and Meta-Analyses (PRISMA).⁶ The combination of keywords “compartment chronic forearm” OR “exertional compartment forearm” OR “exertional forearm” were used for the search, with no limits for year of publication. Medline (PubMed), Web of Science, Embase and Scopus were accessed on 8 July 2020, and articles in English were identified. All prospective or retrospective clinical studies reporting data of patients affected by chronic exertional compartment syndrome were considered. Only

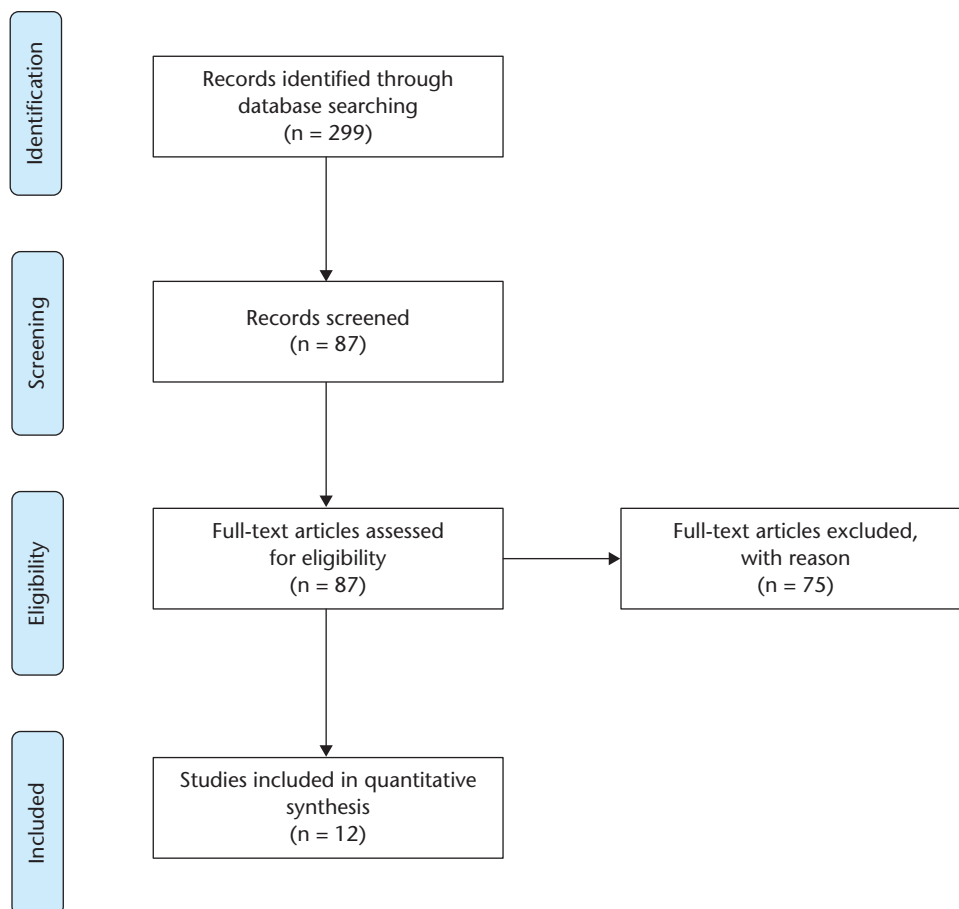


Fig. 1 PRISMA flowchart. A total of 299 studies were identified at the first search and 87 studies were selected based on the abstract. Finally, 12 articles were included in our systematic review.

studies published in a peer-reviewed fashion were eligible. Biomechanical studies, studies on animals or cadavers, technical notes, letters to the editor, reviews, and instructional courses were excluded. Two authors independently assessed the abstract of each publication. When the study could not be included or excluded based on the abstract, a full-text version of the article was downloaded. If the full text was not available, the article was excluded from the study. In addition, the reference list of each selected article was searched manually to identify any additional studies missed during the electronic search.

The two investigators assessed each study according to the Coleman Methodological Score (CMS); a score ranging from 0 to 100.⁷ Both investigators performed the CMS assessment twice, with an interval of 10 days, and they discussed the scores until consensus was reached when more than a two-point difference was present. Data on demographic features, surgical procedures, diagnostic methods, follow-up periods, type and rates of complications, return to sport, recurrence, and outcome measures were recorded.

Results

A total of 299 studies were identified after the first search. Thereafter, 87 studies were selected on the basis of the abstract, 75 were excluded after the full text had been read, and 12 publications relevant to the topic were included (Fig. 1). All included studies were published between 2005 and 2020. The total number of patients was 336: 98.5% (331) were male and 1.5% (5) female. The total number of forearms treated was 605, with 80% of patients (269/336) receiving a bilateral fasciotomy (Table 1). The mean age of the patients at the time of treatment was 25.1 years (range 16.8–34.0 years), one study did not report data on age,⁸ and the mean follow-up time was 56.7 months (range 3.0–97.2 months).

Quality assessment

All the Coleman scores are given in Table 1. A score of > 85 is considered excellent, 70 to 84 is good, 50–69 is moderate, and < 50 is poor. The mean CMS was 55.3 (range 39.0–74.0).

Table 1. Characteristics, surgical techniques and quality of the studies

Study	N of patients	Surgical technique	N of compartments treated	Follow-up (m)	Sport activity	Coleman Methodological Score
Zandi 2005 ¹⁰	6	Open	1 patient 2 compartments 5 patients 1 compartment	60	1 wheelchair sprinter 1 motorcycle rider 1 manual worker 1 mountain climber 2 water-skiers	39
Croutzet 2009 ¹⁷	8	Mini-open	8 patients 4 compartments	27	motorcycle rider	60
Brown 2011	12	Open	6 patients 3 compartments 5 patients 2 compartments 1 patient 1 compartment	97	5 motorcycle rider 1 crane driver/golf, 1 manual worker/martial art 1 martial art/box 2 manual worker 2 rowers	45
Winkes 2012 ¹²	24	Open	24 patients 1 compartments	60	motorcycle rider	46
García-Mata 2013 ⁹	5	Open	2 patients 2 compartments 3 patients 2 compartments	72	motorcycle rider	45
Harrison 2013 ⁸	6	Open	6 patients 4 compartments	3	Rowers	51
Barrera-Ochoa 2016	34	Open vs. mini-open	34 patients 4 compartments	46 43	motorcycle rider motorcycle rider	74
Jans 2015	154	Endoscopic	154 patients 1 compartment	6	motorcycle rider	64
Pegoli 2016	3	Endoscopic	3 patients 1 compartment	46	motorcycle rider	45
Gondolini 2019	54	Mini-open	54 patients 3 compartments	70	motorcycle rider	70
Schiavi 2020	9	Mini-open	9 patients 3 compartments	92	motorcycle rider	63
Ruyer 2020 ¹⁶	21	Endoscopic	20 forearms 1 compartment 16 forearms 2 compartment	59	17 motorcycle 2 quad racing 1 mountain biking 1 water skiing	62

Diagnosis

The diagnosis was clinical in all the studies. Intra-compartment pressure was measured in ten studies.^{3,8–16} Magnetic resonance imaging (MRI) was performed in three studies.^{5,14,15}

Surgical techniques

Five studies^{8–12} involved an open fasciotomy. Three studies^{14,15,17} involved a mini-open fasciotomy. An endoscopic fasciotomy was performed in three studies.^{5,13,16} One study³ compared two techniques: open vs. mini-open. The number of compartments released in each study is indicated in Table 1.

Outcomes

Patient satisfaction was reported in five studies.^{3,11,12,16,17} Pain relief (visual analogue scale [VAS] score) was reported in six studies.^{3,5,12–15} Functional scale (the Disabilities of the Arm, Shoulder and Hand (DASH) and QuickDASH) were reported in four studies.^{3,13–15} Outcomes are reported in Table 2.

Return to sports

Return to sport is reported in Table 3. The average time before return to sport for open, mini-open and endoscopic fasciotomies was 5.3 weeks, 3.8 weeks and 4.4 weeks, respectively. The overall average time before return to sport was 5 weeks (range 2.7–9.0 weeks).

Complications

The complications are reported in Table 3. Three studies did not report any complications.^{12,13,15}

Recurrence

Seven revision procedures were reported. They are displayed in Table 3.

Discussion

The CMS allowed for the detection of several areas with deficiencies. All the studies, except one,³ were case studies. Ideally, study design would follow a randomized control trial design, but this is difficult to achieve in clinical practice.

Motorcycle racers (93.7%, 315/336) represented the most affected population in this systematic review. This could be attributed to the way these athletes grasp the bike handlebars with continuous bimanual grip.

Clinical assessment remains the gold standard for diagnosis of CECS. Intra-compartment pressure measurement is widely used;^{3,8–16} however, there are differences regarding the timing of measurements: six studies^{3,8–13} measured intra-compartment pressure during exercise or immediately after cessation, while in six studies^{3,10–14} the pressure was measured from 1 to 5 minutes after exercise. It is interesting that none of the studies measured the intra-compartment pressure after the surgical procedure.

Table 2. Subjective outcomes

Study	Satisfaction	Pre-op VAS	Post-op VAS	Pre-op DASH/QuickDASH	Post-op DASH/QuickDASH
Zandi 2005 ¹⁰ Open	N\A	N\A	N\A	N\A	N\A
Croutzet 2009 ¹⁷ Mini-open	100% satisfied	N\A	N\A	N\A	N\A
Brown 2011 Open	11/12 very satisfied	N\A	N\A	N\A	N\A
Winkes 2012 ¹² Open	83% very satisfied 12% fairly satisfied 5% not satisfied	5.3	0.7	N\A	N\A
García-Mata 2013 ⁹ Open	N\A	N\A	N\A	N\A	N\A
Harrison 2013 ⁸ Open	N\A	N\A	N\A	N\A	N\A
Barrera-Ochoa 2016 Open vs. mini-open	32/34 patients very satisfied 2 fairly satisfied (1 MOF, 1 OF) 1 non satisfied (MOF)	7.8 7.8	1.5 1.7	84 86	15 12
Jans 2015 Endoscopic	N\A	7.4	1.7	N\A	N\A
Pegoli 2016 Endoscopic	N\A	4.5	0.7	21.7	5.4
Gondolini 2019 Mini-open	N\A	6.8	2.4	84	12
Schiavi 2020 Mini-open	N\A	6.9	2.6	79	17
Ruyer 2020 ¹⁶ Endoscopic	78% very satisfied 17% satisfied 1% moderately satisfied	N\A	N\A	23	1

Note. Visual Analogue Scale (VAS) ; the Disabilities of the Arm, Shoulder and Hand (DASH); mini-open fasciotomy (MOF); open fasciotomy (OF) .

Table 3. Number of procedures, complications, revisions and return to sport/work

Study	Surgical technique	N of patients	Complications	Revision procedure	Return to sport\work (weeks) average
Zandi 2005 ¹⁰	Open	6	1 haematoma 3 scar problems	None	6
Croutzet 2009 ¹⁷	Mini-open	8	1 scar problem	None	6
Brown 2011	Open	12	1 haematoma 1 recurrence	1	9
Winkes 2012 ¹²	Open	24	none	1	4
García-Mata 2013 ⁹	Open	5	3 scar problems 1 paraesthesia	None	6
Harrison 2013 ⁸	Open	6	1 paraesthesia	None	4
Barrera-Ochoa 2016 vs. mini-open	Open vs. mini-open	34	Open: 2 haematomas 1 cutaneous problem 1 superficial infection Mini-open: 4 haematomas 1 skin problem 2 superficial infections	None 1	Open 3 Mini-open 3
Jans 2015	Endoscopic	154	5 haematomas	None	6
Pegoli 2016	Endoscopic	3	none	None	3
Gondolini 2019	Mini-open	54	3 scar problem	2	3
Schiavi 2020	Mini-open	9	none	None	3
Ruyer 2020 ¹⁶	Endoscopic	21	2 haematomas 3 hypoesthesia	2	4

MRI is a valid diagnostic alternative, with the advantage of being less invasive but at the same time more expensive.¹⁸ We believe that MRI can be useful as an alternative for measuring hydrostatic pressure, but it would be redundant to use both methods.

We categorized the surgical fasciotomy techniques into three groups: open, mini-open, and endoscopic. Among these categories there was no uniformity, as indicated in

Table 1; in fact the number of compartments released can be variable independently from the technique. Furthermore, there are four studies^{9–11,16} where the number of compartments released changes depending on the surgeon’s clinical judgment.

The reported outcomes revealed that fasciotomy is an effective technique in terms of patient satisfaction, pain relief (VAS) and functional scores (DASH and QuickDASH).

Studies^{5,13,16} which involved limited fasciotomy of the superficial volar compartment reported outcomes in terms of satisfaction and remission of symptoms that were at least equal to studies which involved open fasciotomy. For this reason we agree with the hypothesis of Chan et al,⁴ that forearm compartments are interconnected and there is a balance of the pressure level, especially through the interosseous membrane.

Haematoma was the most common complication (4.5%, 15/336), with no differences in terms of percentage among the techniques. We can assume that the theoretical advantage of better bleeding control afforded by the open technique compared to the endoscopic does not find credence. When we compared time to return to sport, we noticed that mini-open and endoscopic techniques required a shorter recovery time compared to the open technique. This result was expected because the two techniques are less invasive and require less surgical exposure. Some authors^{16,19} report late onset of lateral epicondylitis; they hypothesize that this is due to the remission of CECS which allows the athletes to train at higher intensities.

Our study has several limitations. Firstly, the number of studies included in our review is limited; furthermore, some studies have a small group of patients and there is just one study which compared mini fasciotomy to open fasciotomy. Secondly, fasciotomy was categorized into three groups (open, mini-open, and endoscopic) but there were differences among the studies in terms of compartments released, and these were not categorized. Thirdly, the different methods of assessing and presenting results did not allow for statistical analysis.

Conclusions

In comparison to the other techniques, endoscopic fasciotomy delivers similar success rates and lower incidence of complications. Furthermore, because this procedure is minimally invasive, it has the advantage of a faster return to sport and less impact on cosmetic appearance. Further comparative studies are needed to support these conclusions. In fact we included a small number of studies with limited number of patients.

AUTHOR INFORMATION

¹Department of Public Health, Division of Orthopaedic Surgery, 'Federico II' University, Naples, Italy.

²Department of Biotechnology and Life Sciences, Division of Plastic and Reconstructive Surgery, University of Insubria, Varese, Italy.

Correspondence should be sent to: Francesco Smeraglia, Department of Orthopaedic Surgery, 'Federico II' University, Via S. Pansini 5, bd. 12, 80131, Napoli, Italy.

Email: francesco.smeraglia@gmail.com

ICMJE CONFLICT OF INTEREST STATEMENT

The authors declare no conflict of interest relevant to this work.

FUNDING STATEMENT

No benefits in any form have been received or will be received from a commercial party related directly or indirectly to the subject of this article.

OPEN ACCESS

© 2021 The author(s)

This article is distributed under the terms of the Creative Commons Attribution-Non Commercial 4.0 International (CC BY-NC 4.0) licence (<https://creativecommons.org/licenses/by-nc/4.0/>) which permits non-commercial use, reproduction and distribution of the work without further permission provided the original work is attributed.

REFERENCES

- Martens MA, Moeyersoons JP.** Acute and recurrent effort-related compartment syndrome in sports. *Sports Med* 1990;9:62–68.
- Hutchinson MR, Ireland ML.** Common compartment syndromes in athletes: treatment and rehabilitation. *Sports Med* 1994;17:200–208.
- Barrera-Ochoa S, Haddad S, Correa-Vázquez E, et al.** Surgical decompression of exertional compartment syndrome of the forearm in professional motorcycling racers: comparative long-term results of wide-open versus mini-open fasciotomy. *Clin J Sport Med* 2016;26:108–114.
- Chan PS, Steinberg DR, Pepe MD, Beredjikian PK.** The significance of the three volar spaces in forearm compartment syndrome: a clinical and cadaveric correlation. *J Hand Surg Am* 1998;23:1077–1081.
- Jans C, Peersman G, Peersman B, Van Den Langenberg T, Valk J, Richart T.** Endoscopic decompression for chronic compartment syndrome of the forearm in motocross racers. *Knee Surg Sports Traumatol Arthrosc* 2015;23:2522–2527.
- Liberati A, Altman DG, Tetzlaff J, et al.** The PRISMA statement for reporting systematic reviews and meta-analyses of studies that evaluate healthcare interventions: explanation and elaboration. *BMJ* 2009;339:b2700.
- Coleman BD, Khan KM, Maffulli N, Cook JL, Wark JD; Victorian Institute of Sport Tendon Study Group.** Studies of surgical outcome after patellar tendinopathy: clinical significance of methodological deficiencies and guidelines for future studies. *Scand J Med Sci Sports* 2000;10:2–11.
- Harrison JWK, Thomas P, Aster A, Wilkes G, Hayton MJ.** Chronic exertional compartment syndrome of the forearm in elite rowers: a technique for mini-open fasciotomy and a report of six cases. *Hand (N Y)* 2013;8:450–453.
- García-Mata S.** Chronic exertional compartment syndrome of the forearm in adolescents. *J Pediatr Orthop* 2013;33:832–837.
- Zandi H, Bell S.** Results of compartment decompression in chronic forearm compartment syndrome: six case presentations. *Br J Sports Med* 2005;39:e35.
- Brown JS, Wheeler PC, Boyd KT, Barnes MR, Allen MJ.** Chronic exertional compartment syndrome of the forearm: a case series of 12 patients treated with fasciotomy. *J Hand Surg Eur Vol* 2011;36:413–419.
- Winkes MB, Luiten EJ, van Zoest WJ, Sala HA, Hoogveen AR, Scheltinga MR.** Long-term results of surgical decompression of chronic exertional compartment syndrome of the forearm in motocross racers. *Am J Sports Med* 2012;40:452–458.
- Pegoli L, Pozzi A, Pivato G.** Endoscopic single approach forearm fasciotomy for chronic exertional compartment syndrome: long term follow-up. *J Hand Surg Asian Pac* 2016;21:8–12.

- 14. Gondolini G, Schiavi P, Pogliacomini F, Ceccarelli F, Antonetti T, Zasa M.** Long-term outcome of mini-open surgical decompression for chronic exertional compartment syndrome of the forearm in professional motorcycling riders. *Clin J Sport Med* 2019;29:476–481.
- 15. Schiavi P, Gondolini G, Gandolfi CE, Guardoli L, Vaienti E, Zasa M.** Mini-open surgical fasciotomy for chronic exertional compartment syndrome of the forearm in professional motorcycling adolescents. *Clin J Sport Med* 2020;30:e225–e230.
- 16. Ruyer J, Rutka V, Garret J, Rizzo C, Guigal V.** Endoscopic fasciotomy for chronic exertional compartment syndrome of the forearm: clinical results of a new technique using an endoscopic carpal tunnel release device. *Hand Surg Rehabil* 2020;39:154–158.
- 17. Croutzet P, Chassat R, Masmajeau EH.** Mini-invasive surgery for chronic exertional compartment syndrome of the forearm: a new technique. *Tech Hand Up Extrem Surg* 2009;13:137–140.
- 18. Gielen JL, Peersman B, Peersman G, et al.** Chronic exertional compartment syndrome of the forearm in motocross racers: findings on MRI. *Skeletal Radiol* 2009;38:1153–1161.
- 19. Fontes D, Clement R, Roure P.** [Endoscopic aponeurotomy for chronic exertional compartmental syndrome of the forearm: report of 41 cases]. *Chir Main* 2003;22:186–196.