

CASE REPORT

Role of exploratory laparoscopy in haemodynamically stable patient with a penetrating abdominal trauma

Emira Nur Shafina Muhammad-Sharizan and Valerio V. DiNicola*

Department of Surgery, Noble's Hospital, Douglas, Isle of Man

*Correspondence address. E-mail: valerio.dinicola@gov.im

Abstract

A young lady presented to the hospital following a penetrating abdominal trauma. She was haemodynamically stable during the initial assessment. Despite fruitless finding from blood test, plain radiograph and computed tomographic scanning, a bowel contusion was found during an explorative laparoscopy. Here, we highlight the need for laparoscopy as a diagnostic and therapeutic tool in haemodynamically stable patient with a penetrating abdominal trauma.

INTRODUCTION

A penetrating abdominal trauma could present in various mechanisms and presentations. It is important to identify the relevant investigations for timely repair and prevention of serious morbidity. We report a case of a 23-year-old female who had sustained a penetrating trauma following a fall on sharp metal spike, but presented without any positive clinical finding. Between the options of conservative management or explorative laparoscopy, the latter was opted and it was proved to be life-saving.

CASE REPORT

A 23-year-old female tourist from the Isle of Man admitted as an emergency case 2 h after having a fall from 12-feet height onto a sharp metal spike of a lamp. She was haemodynamically stable with a total Noble's early warning score of 0. On examination, there was 2 × 1 cm triangular penetrating wound on the left iliac fossa, some rebound tenderness and silent bowel. There are bruises but no evidence of head, neck, chest or limb injury. Her blood tests (i.e. haemoglobin, haematocrit, C-reactive protein and white cell counts) were normal; chest and abdominal radiography did not show any evidence of perforation.

A computed tomographic (CT) scan of the abdomen and pelvis was arranged, which showed soft tissue injury on the left

abdominal wall but no sign of penetration to the peritoneal cavity nor free fluid nor free gas in the abdominal cavity. Explorative laparoscopy was consented for and there were 30 cc free blood in the Douglas pouch (Fig. 1) and a contusive lesion of the descending colon (Fig. 2). The lesion appeared ischaemic and involved in the serosa and muscle layer of the colon (Fig. 2). The colonic lesion was sutured, and the wound was debrided and also sutured. A drain was left *in situ*. She recovered well and discharged as soon as bowel function recovered, which was on the fourth day postoperatively.

DISCUSSION

The incidence of penetrating abdominal trauma differs from hospital to hospital and management depends on patient's haemodynamic stability. It is clearly stated in many literatures that the gold standard management of patient who presented with haemodynamic instability is an urgent laparotomy [1]. However, the grey area still persists when it comes to which investigation is most useful to evaluate the patient who presents haemodynamically stable or with no clinical findings such as peritonitis or viscous perforation. An effective and efficient algorithm has yet been formed.

When assessing a patient with penetrating injury, the main aim of the assessment is to identify injuries that might require

Received: April 29, 2015. Accepted: June 1, 2015

Published by Oxford University Press and JSCR Publishing Ltd. All rights reserved. © The Author 2015.

This is an Open Access article distributed under the terms of the Creative Commons Attribution Non-Commercial License (<http://creativecommons.org/licenses/by-nc/4.0/>), which permits non-commercial re-use, distribution, and reproduction in any medium, provided the original work is properly cited. For commercial re-use, please contact journals.permissions@oup.com

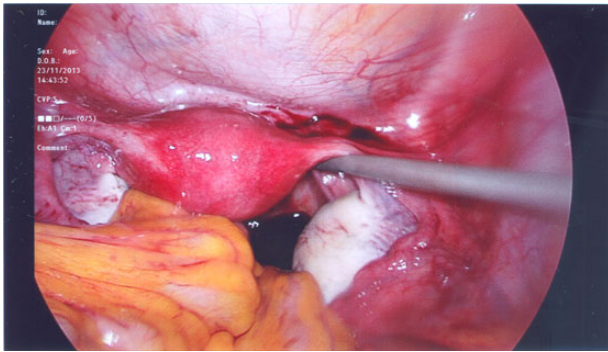


Figure 1: Laparoscopic capture showing 30 ml free blood in the Douglas pouch.

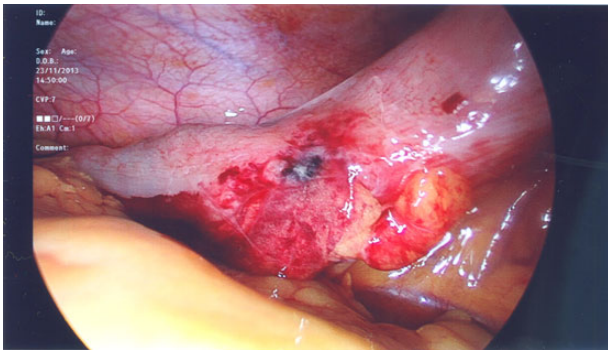


Figure 2: Laparoscopic capture showing the contusion and ischaemic appearance of the descending colon.

urgent repair to avoid deterioration of the damage, thus avoiding an unnecessary laparotomy. Routine investigation such as blood test and plain radiographs could give a prognostic picture of a patient [2]. In this case, her plain abdominal and chest radiographs clearly indicated that no perforation of the bowel had occurred. Given that her vital signs were stable and normal haematocrit, this indicated that no major haemorrhage has occurred.

A CT scan has become a useful investigation adjunct in evaluating penetrating abdominal injury. It gives a good picture of any peritoneal injuries including the best view of the retroperitoneal structures. This imaging has sensitivity and specificity of 94.9 and 95%, respectively [2]. Despite being statistically effective, the CT scan could give a pitfall in evaluating a patient, whereas

in this case it fails to detect minor injury such as bowel contusion [3].

Exploratory laparoscopy uses minimal access to explore the peritoneal cavity. Although requiring general anaesthesia and experienced laparoscopist, it could achieve 90–100% sensitivity in evaluating abdominal trauma, shorter hospital stay and cost-effective [4, 5]. In this case, therapeutic laparoscopy was also carried out and this had saved the patient from the possibility of delayed perforation of the bowel and late formation of stricture [6].

In conclusion, a penetrating bowel trauma requires a systematic approach. The main objective in the algorithm is to evaluate if urgent laparotomy is required. In haemodynamically stable patient, investigation tools may provide a prognostic value. A CT scan is highly sensitive and specific, however, poor at detecting a bowel contusion. Exploratory laparoscopy is a necessary adjunct in the diagnosis and management of penetrating bowel trauma.

CONFLICT OF INTEREST STATEMENT

None declared.

REFERENCES

1. Numanoglu A. Laparoscopy in abdominal trauma: the use of laparoscopy is well established in paediatric abdominal trauma. *CME* 2010;28:119–21.
2. Mama N, Jemni H, Achour NA, Sidiya OC, Kadri K, Gaha M, et al. Abdominal trauma imaging. In: Derbel PF, ed. *Abdominal Trauma Imaging, Abdominal Surgery*. InTech, 2012. Available from: <http://www.intechopen.com/books/abdominal-surgery/abdominal-trauma-imaging> (22 June 2015, date last accessed).
3. Brody JM, Leighton DB, Murphy BL, Abbott GF, Vaccaro JP, Jagminas L, et al. CT of blunt trauma bowel and mesenteric injury: typical findings and pitfalls in diagnosis. *RadioGraphics* 2000;20:1525–36.
4. Miles EJ, Dunn E, Howard D, Mangram A. The role of laparoscopy in penetrating abdominal trauma. *JLS* 2004;8:304–9.
5. Uranues S, Popa DE, Diasconescu B, Scrittewieser R. Laparoscopy in penetrating abdominal trauma. *World J Surg* 2014; 39:1381–88.
6. Paterson-Brown S, Francis N, Whawell S, Cooper GJ, Dudley HA. Prediction of the delayed complications of intestinal and mesenteric injuries following experimental blunt abdominal trauma. *Br J Surg* 1990;77:648–51.