


Contents lists available at [ScienceDirect](#)

## Acta Orthopaedica et Traumatologica Turcica

journal homepage: <https://www.elsevier.com/locate/aott>

## Evaluation of thoracic vertebrae rotation in patients with pectus excavatum



Ryszard Tomaszewski, Łukasz Wiktor\*, Ludwina Machała

Silesian Medical University, Katowice, Poland

## ARTICLE INFO

*Article history:*

Received 14 September 2015

Received in revised form

19 November 2016

Accepted 31 January 2017

Available online 16 June 2017

*Keywords:*

Adolescent idiopathic scoliosis

Pectus excavatum

Haller index

Vertebrae rotation

## ABSTRACT

**Purpose:** The aim of our study was to evaluate thoracic vertebrae rotation in patients with pectus excavatum. Moreover, we wanted to assess the prevalence, the severity and relationship between pectus excavatum and adolescent idiopathic scoliosis (AIS).

**Methods:** We performed retrospective analysis of 82 preoperative chest CT in children with pectus excavatum performed between January 2008 and December 2011. For each patient Haller Index and Cobb angle was measured. To evaluate the severity of thoracic scoliosis we measured vertebral rotation for Th8 and for vertebra at the level of highest chest deformation using Aaro-Dahlborn method.

**Results:** From the group of 54 patients with pectus excavatum enrolled in the study AIS was diagnosed in 8 patients (14,81%). In patients with symmetric deformation, Th8 rotation was found in 21 patients; the rotation of the apical vertebra was found in 20 patients. In patients with asymmetric deformation Th8 rotation was found in 10 patients; the rotation of the apical vertebra was found in 8 patients.

**Conclusions:** **1.** We have confirmed the higher prevalence of pectus excavatum in boys; **2.** We have found a significant relationship between pectus excavatum and adolescent idiopathic scoliosis; **3.** We have shown that deformation of the anterior chest wall enforces rotation of the thoracic spine; **4.** We haven't found the relationship between the severity of the chest deformity (HI measured) and severity of AIS (Cobb angle measured); **5.** We have shown a significant association between HI measured and rotation of thoracic vertebra at the level of highest chest deformation (apical vertebra) in symmetric pectus excavatum.

**Level of evidence:** Level IV, Diagnostic study.

© 2017 Turkish Association of Orthopaedics and Traumatology. Publishing services by Elsevier B.V. This is an open access article under the CC BY-NC-ND license (<http://creativecommons.org/licenses/by-nc-nd/4.0/>).

### Introduction

Pectus excavatum is the most common anterior wall chest deformity with incidence of 1–3 per 1000.<sup>1</sup> It occurs more frequently in boys than girls by a 4:1 ratio.<sup>1,2</sup> This deformity involves lower part of sternum (body of the sternum), which is displaced posteriorly into the chest. The cause of pectus excavatum has not been established. As a possible causes of this deformation suggests: disturbed growth of the sternum and the costal arches; biomechanical factors; connective tissue disorders and other musculoskeletal abnormalities. It is worth mentioning that there is a genetic predisposition in patients with family history of pectus

excavatum. In most cases pectus excavatum is a cosmetic defect with no physiological consequences. In severe deformities, the decrease in thoracic volume is seen. This may lead to decreased pulmonary function and affect the function of the right ventricle). Funnel chest defects may lead to chest pain, shortness of breath, decreased cardiac output and decreased exercise capacity depending of the depth of the deformity. Adolescent idiopathic scoliosis (AIS) is a common deformity affecting 0.2–3% of the general population. The prevalence of AIS among patients with pectus excavatum is significantly higher than in the general population and ranges from 17,61 to 25,58% according to various authors.<sup>1,3</sup>

The aim of our study was to evaluate thoracic vertebrae rotation in patients with pectus excavatum. Moreover, we wanted to assess the prevalence, severity and relationship between pectus excavatum and thoracic vertebral rotation as well as adolescent idiopathic scoliosis.

\* Corresponding author.

E-mail address: [wiktor.ort@gmail.com](mailto:wiktor.ort@gmail.com) (Ł. Wiktor).

Peer review under responsibility of Turkish Association of Orthopaedics and Traumatology.

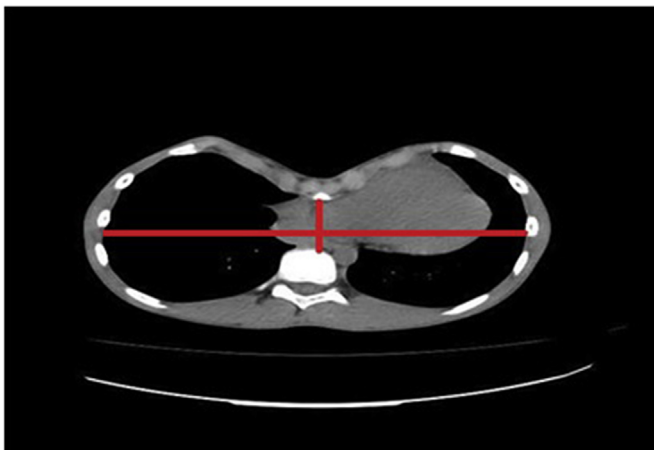
**Material and methods**

We performed retrospective analysis of 82 preoperative CT in children with pectus excavatum performed between January 2008 and December 2011. Examination was done using the Toshiba Aquilion with 5 mm slices and Siemens Somaton Plus 4 with 8 mm slices. For the image evaluation we use program Onis 2.4, Digital-Core Co. Ltd.

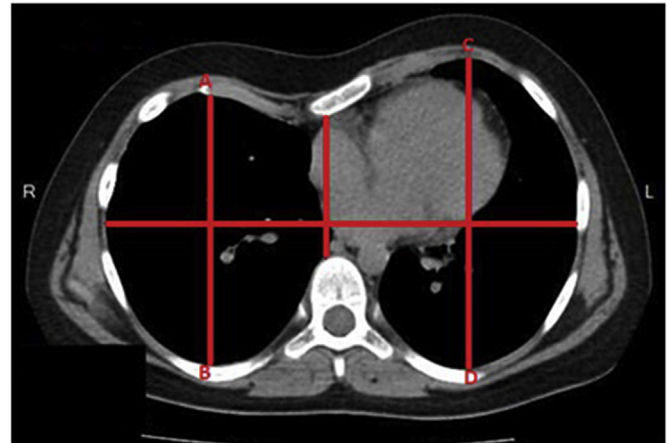
After the reviewing of the collected material, we qualified 54 patients with pectus excavatum for the purpose of the study. Patients with incomplete medical documentation (most commonly lack of radiological data) were excluded from the analysis. Patients with congenital deformities of the spine, connective tissue disorders and other musculoskeletal abnormalities also were excluded from the study.

All chest CT were performed in patients who were diagnosed clinically accepted for surgical correction of the deformity with the use the Nuss procedure. In order to assess the severity of chest deformity for each patient we measured Haller Index on axial CT scans (transverse diameter of chest divided by the anteroposterior diameter at the deepest portion of defect – Fig. 1). Our study group was divided into two groups depending on the chest deformation. The first group consisted of patients with symmetric pectus excavatum (symmetry was defined as difference less then 10 mm between left and right chest cavity vertical distance). The second group included patients with asymmetric pectus excavatum (asymmetry was defined as difference more then 10 mm between left and right chest cavity vertical distance – Fig. 2). There were 35 patients in the first group (7 girls, 28 boys) with mean age 12,57 (4–17) and 19 patients in the second group (4 girls, 15 boys) with mean age 14 (10–17). An overview of the study group is presented in Table 1. To identify and determine the severity of scoliosis we evaluated the classical radiograms (Figs. 3–4) by measuring the Cobb angle on the anteroposterior radiogram. Moreover, on axial CT scans we evaluated the rotation of the thoracic vertebral bodies, every time at two levels, for Th8 vertebra and for apical vertebra (vertebra at the level of highest chest deformation) to indicate rotation severity.

We chose Th 8 vertebra as a reference point for our analysis. Vertebral rotation angle was measured according to Aaro-Dahlborn method (vertebral rotation angle is an angle between anterior midline of body and the line through the dorsal central aspect of vertebral foramen Fig. 5).<sup>4</sup>



**Fig. 1.** Haller Index – ratio of the internal ribcage distance and distance between sternum and vertebrae.



**Fig. 2.** Asymmetric pectus excavatum. Difference between AB and CD is more than 10 mm.

*Statistical analysis*

Tools of statistical analysis:

Due to the large differences in the assessed variables, Spearman's rank correlation coefficient and nonparametric Mann–Whitney *U* test were used to analyze the correlation. To analyze the significance of differences between the incidence of pectus excavatum in girls and boys we tested the significance of the difference between two means.

Statistical analysis was done using STATISTICA 12.5 system.

For all analysis we assumed the significance level equal to 0,05.

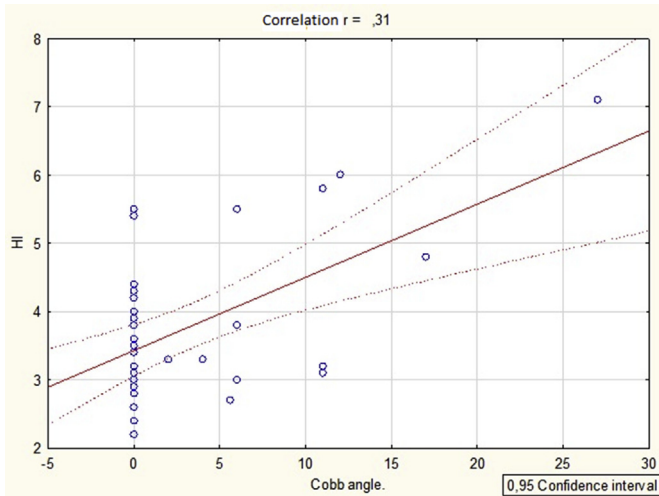
**Tables**

Statistical analysis.

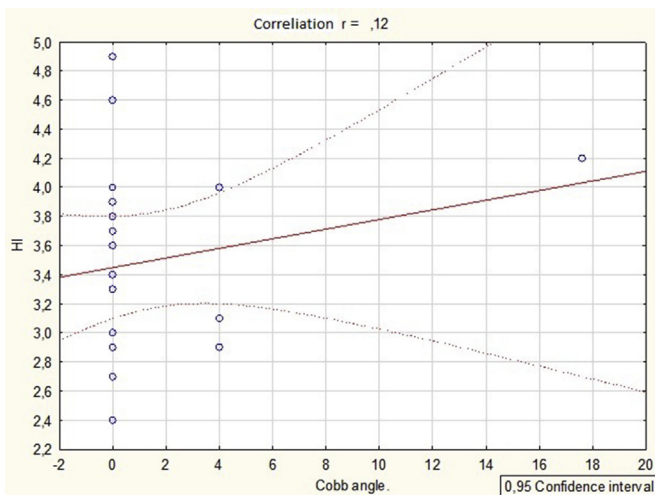
Variable	Pectus excavatum (all patients)			
	Number	Mean	Median	Standard deviation
Age	54	13,07	14,00	3,02
HI	54	3,68	3,40	1,00
TH8 – rotation	54	3,58	3,01	5,01
Apical vertebra rotation	54	3,10	1,85	3,73
Cobb angle	54	2,74	0,00	5,55

Variable	Symmetric pectus excavatum			
	Number	Mean	Median	Standard deviation
Age	35	12,57	13,0000	3,43
HI	35	3,79	3,40	1,14
TH8 – rotation	35	4,24	3,50	5,88
Apical vertebra rotation	35	3,9140	4,07	4,15
Cobb angle	35	3,38	0,00	6,14

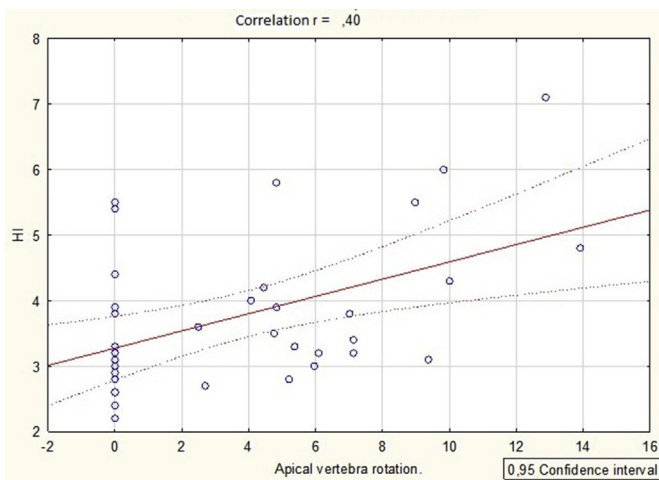
Variable	Asymmetric pectus excavatum			
	Number	Mean	Median	Standard deviation
Age	19	14,00	14,00	1,82
HI	19	3,50	3,40	0,67
TH8 – rotation	19	2,37	2,60	2,51
Apical vertebra rotation	19	1,60	0,00	2,17
Cobb angle	19	1,55	0,00	4,16



**Diagram 1.** The relationship between Haller Index (HI) and Cobb angle. (symmetric pectus excavatum).



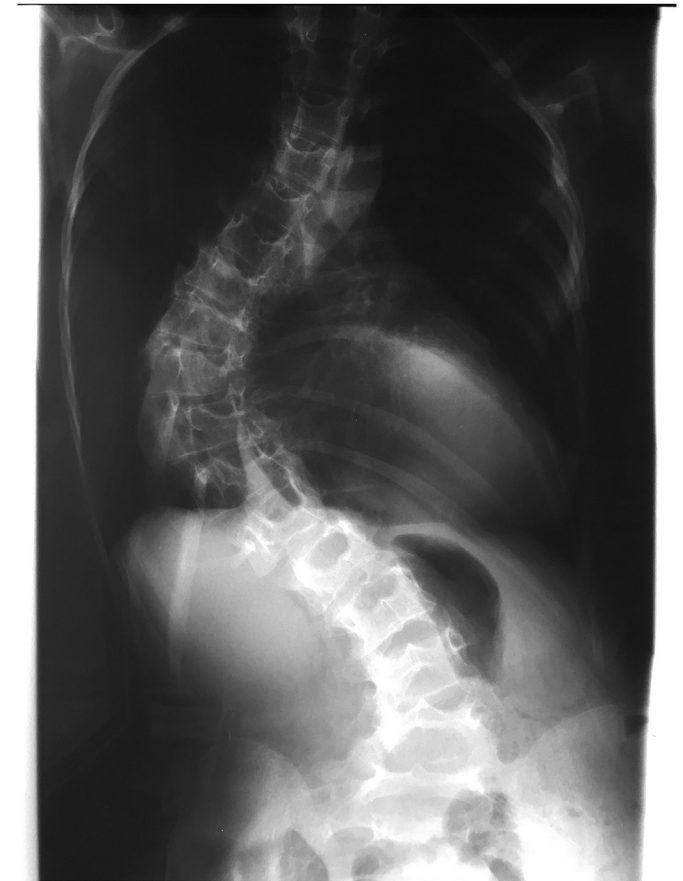**Diagram 2.** The relationship between Haller Index (HI) and Cobb angle. (asymmetric pectus excavatum).



**Diagram 3.** The relationship between Haller Index (HI) and apical vertebra rotation. (symmetric pectus excavatum).

**Table 1**  
Overview of the study group.

	Asymmetric pectus excavatum	Symmetric pectus excavatum
Number	19	35
Presence of Th8 rotation	10/19 (52,63%)	21/35 (60%)
Presence of apical vertebra rotation	8/19 (42,1%)	20/35 (57,14%)
Cobb angle >10°	1/19 (5,26%)	7/35 (20%)
Sex (F:M)	4:15	7:35



**Fig. 3.** Radiogram of 16 year old female patient with pectus excavatum and scoliosis, ap view.

**Results**

In the group of 54 patients with pectus excavatum, AIS was diagnosed in 8 patients (14,81%; 7 patients with symmetric and 1 patient with asymmetric deformation) [Table 2](#). The majority was type 1 by Lenke Classification System (7 patients); one patient presented with type 3 AIS. We found a higher prevalence of pectus excavatum in male patients (79,62%).

In our study group AIS was seen more often in male patients (62,5%).

In the group of patients with symmetric deformation Th8 rotation was found in 21 patients with mean rotation angle of 4,24 (2,40–10,61) degrees; rotation of apical vertebra was found in 20 patients, with mean rotation angle of 3,91 (2,49–13,91) degrees. The average Haller index for this group was 3,79 (2,2–7,1).

In the second group, containing patients with asymmetric deformation, Th8 rotation was found in 10 patients with the mean

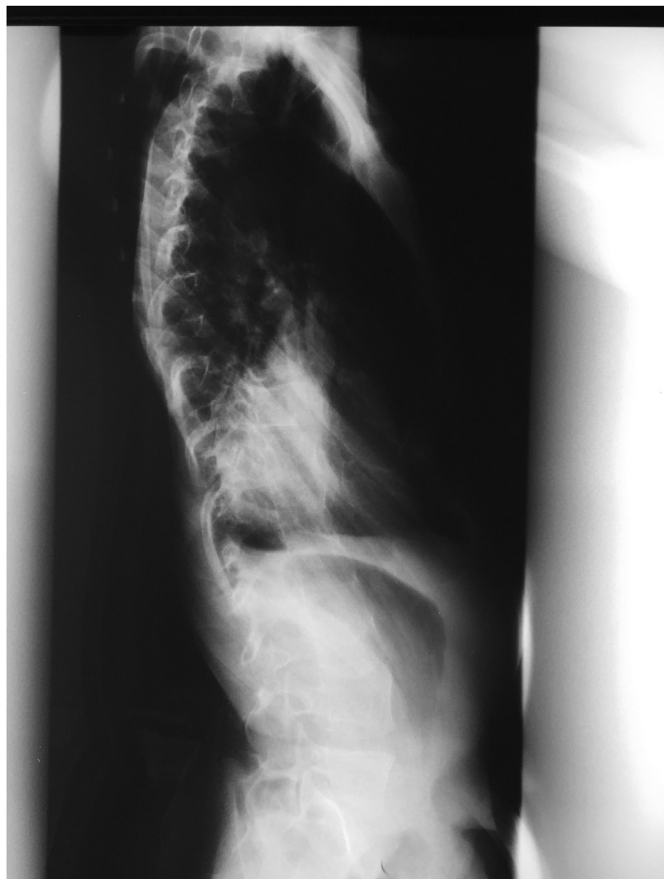

Fig. 4. Radiogram of 16 year old female patient with pectus excavatum and scoliosis, lateral view.

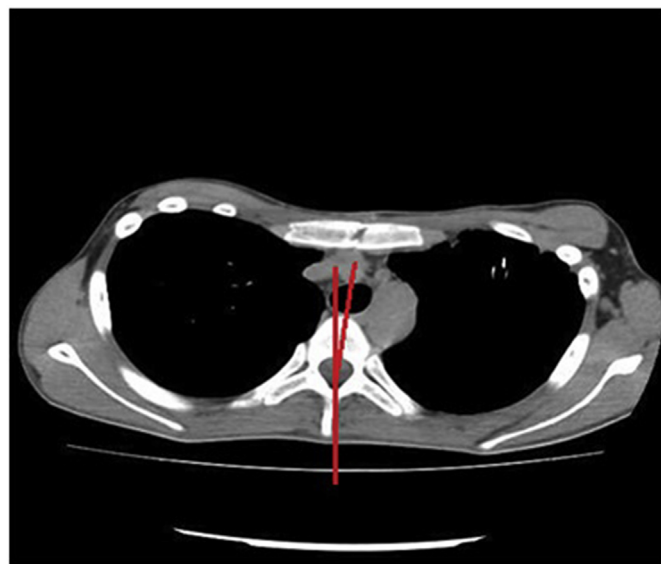


Fig. 5. Vertebral rotation angle according to Aaro-Dahlborn method.

rotation angle of 2,37 (2,60–6,84) degrees; rotation of apical vertebra was found in 8 patients with mean rotation angle 1,60 (1,66–6,20) degrees. The average Haller index for this group was 3,5 (2,4–4,9).

Table 2  
Details of scoliotic patients.

No.	Sex	Age	HI	TH8 – rotation	Apical vertebra rotation.	Cobb angle.	
1.	F	11	7,1	32	12,88	27	SYM
2.	M	16	3,2	9,07	7,13	10,5	SYM
3.	M	12	5,8	4,50	4,82	11	SYM
4.	M	12	4,8	10,61	13,91	17	SYM
5.	M	15	6,0	8,69	9,83	12	SYM
6.	M	13	3,1	6,34	9,37	13	SYM
7.	M	17	5,5	9,43	8,97	11	SYM
8.	F	13	4,2	8,7	11,5	17,6	ASYM

In the group with asymmetric pectus excavatum, the convex deformation was more common on the left site – 17 patients (89,47%). In the symmetric deformation group, the patient with the **largest chest** deformation (HI - 7.1; Cobb angle - 27°) had 32° Th8 rotation and 12.88° apical vertebra rotation. The patient with the **largest asymmetric chest** deformation (HI - 4.9; Cobb angle <10°) had 4.51° Th8 rotation and 4.57° apical vertebra rotation.

Discussion

Adolescent idiopathic scoliosis (AIS) is a three dimensional spinal deformity including lateral and rotational components. The prevalence of AIS among patients with pectus excavatum is significantly higher than in the general population. The Cobb angle is the fundamental parameter which allows the radiological diagnosis of AIS. This is measured on anteroposterior spinal radiogram. AIS is diagnosed in patients with the Cobb angle greater than 10°.

The evaluation of AIS severity requires not only the assessment of lateral curvature but also the assessment of the vertebral rotation (axial plane). Juxtaposition of vertebral rotation and lateral motion could provide better understanding of AIS as a three dimensional issue. Moreover, the estimation of vertebral rotation is an indicator of curve progression and also helps determine the correct insertion of pedicle screws in preoperative planning.<sup>3,4</sup>

The Cobb method was the first method which allowed the approximate measurement of vertebral rotation on classic radiogram.<sup>4,5</sup> Its assumption was to divide the vertebral body into six sections. The region in which the spinous process was aligned determined the grade of vertebral rotation. Other methods like: Nash-Moe, Perdriolle, Stokes were subsequently developed. Currently, various methods are used to assess vertebral rotation, including real time ultrasound, AUSCAN system and MRI. These techniques avoid patient exposure to X-ray radiation.

The development of computed tomography allowed a precise assessment of vertebral rotation on axial scans and in our opinion it is most accurate method. We used Aaro-Dahlborn method, which is most popular and gives better measurement accuracy even when measuring vertebrae tilted in the sagittal and coronal planes.<sup>4,5</sup>

Similarly to other authors, our study confirmed the higher prevalence of pectus excavatum in boys (79,62%), p = 0,0002. In process of the statistical analysis of correlation between pectus excavatum and AIS for the reference value we assumed the upper range of AIS occurrence in general population (3%). In our study group prevalence of AIS among patients with pectus excavatum was 14,81% (8 from 54 patients). This was lower compared to the results of other authors.<sup>1,3</sup> Regardless of this, the aforementioned chest deformation significantly increased risk of AIS (p = 0,0066). This agrees with reports of other authors on coexistence of pectus excavatum and scoliosis.<sup>1,6,7</sup> It should be noted that the estimation of Cobb angle in our study was made in supine position, which is required in a CT examination. It may cause decrease of Cobb angle

and rotation angle of vertebrae (underestimation of the real vertebrae rotation).<sup>8,9</sup>

Contrary to Hong et al,<sup>1</sup> who reported a higher frequency of scoliosis in females with pectus excavatum, we observed AIS more often in boys (62,5%). In our opinion, this could reflect the fact that the vast majority of our study group (approximately 80%) were male. Similarly to other authors,<sup>1–3</sup> in our study we noted higher value of Haller Index and Cobb angle among girls (Charts 1 and 2). Presence of vertebral rotation in our group was more common than scoliosis (related to Cobb angle larger than 10°) – Table 1. This indicates that the deformation of the anterior chest wall may enforce rotation of the thoracic spine, but only in some patients the rotation is large enough to fulfill the criteria for the diagnosis of scoliosis. Despite such assumptions, similarly to other authors, we haven't found the direct relationship between the severity of the chest deformity (HI measured) and the severity of AIS (measured by Cobb angle;  $p > 0,05$ ). Contrary to Hong et al,<sup>1</sup> in our study group scoliosis occurred more often in patients with symmetric deformity. The analysis of the study group showed a significant association between HI measured and apical vertebra rotation ( $p < 0,05$ ). This correlation is present only for symmetric deformation and shows upward trend (with the increase in apical vertebra rotation HI increases too). There is no such correlation between HI and TH8-rotation ( $p > 0,05$ ). Furthermore, we have not found the evidence that vertebral rotation at the level of highest chest deformation was the maximal rotation found in the thoracic spine. Therefore, we can

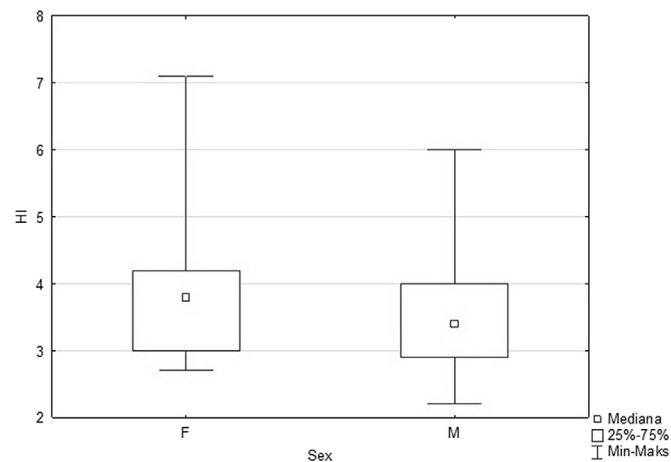


Chart 1. The relationship between the Haller Index (HI) and sex.

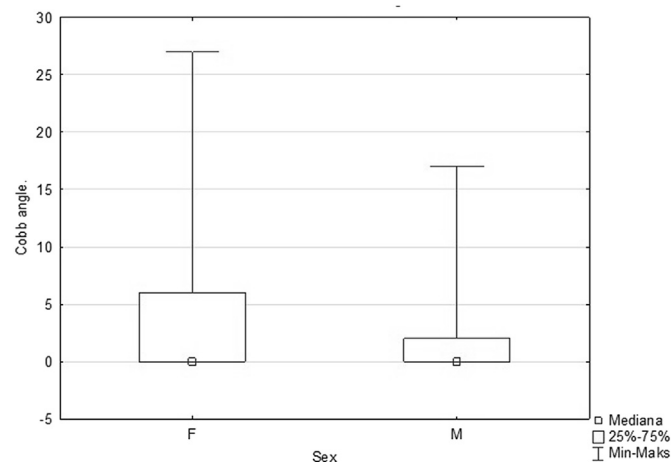


Chart 2. The relationship between the Cobb angle and sex.

merely conclude that the symmetric deformation of the anterior chest wall forces larger deformation of the thoracic spine. Our literature review did not find similar reports. Moreover, in papers evaluating the interdependence of AIS and pectus excavatum there were no statistically significant arguments to explain this correlation.

It is worth emphasizing that the analysis of vertebral rotation in the normal, non-scoliotic spine made by Janssen et al<sup>8</sup> showed that the mid and lower thoracic spine was rotated to the right side at the adolescent age. The authors suggested that the direction of the developing curve in AIS was determined by a rotational pattern already present in the spine before the spine started to develop the deformity. Similarly, we have found that in 25 (80,64%) patients with Th8 – rotation angle different from 0, thoracic vertebrae were rotated to the right side. Yuncang et al<sup>3</sup> found that in 80% of patients with scoliosis at Th6 to Th10 level, thoracic vertebrae were bent to the right, therefore in our analysis we adopted Th8 level as the reference point. In our opinion, vertebral rotation to the right is also associated with more frequent convex deformity of the left site in patients with asymmetric pectus excavatum (89,47% in our study). Furthermore, we think that mechanical factor plays an important role in the coexistence of pectus excavatum and thoracic scoliosis. Our opinion is supported by Yuncang et al<sup>3</sup> who speculated that anterior chest deformity pushed the heart to the left and counterforce generated by the heart pushed the thoracic vertebrae to the right. We believe there is a correlation between the deformation of anterior chest wall and the rotation of thoracic spine, however it is more complex than we anticipated. The pathological mechanism of coexistence between AIS and pectus excavatum certainly requires further analysis. In our study we haven't evaluated outcomes after surgical treatment of the pectus excavatum, although there are reported cases of acquired scoliosis and exacerbation of deformity of the spine in asymmetric thorax following minimally invasive repair of pectus excavatum.<sup>9,10</sup> The weak point of Our work is evaluation of vertebral rotation in the supine position/forced in CT/which reduce the rotation of the vertebrae.

## Conclusion

1. We have confirmed higher prevalence of pectus excavatum in boys.
2. We have found a significant relationship between pectus excavatum and adolescent idiopathic scoliosis (AIS).
3. We have shown that deformation of the anterior chest wall enforces rotation of the thoracic spine.
4. We haven't found the relationship between the severity of the chest deformity (HI measured) and the severity of AIS (Cobb angle measured).
5. We have shown a significant association between HI measured and rotation of thoracic vertebra at the level of highest chest deformation (apical vertebra) in symmetric pectus excavatum.

## References

1. Hong Jae-Young, Suh Seung-Woo, Park Hyung-Joo, Kim Young-Hwan, Park Jung-Ho, Park Si-Young. Correlations of adolescent idiopathic scoliosis and pectus excavatum. *J Pediatr Orthop*. 2011;31(8):870–874.
2. Kelly RE, Nuss D. Pectus excavatum. In: Parikh DH, Crabbe D, Auldist A, Rothenberg S, eds. *Pediatric Thoracic Surgery*. Berlin: Springer; 2009.
3. Wang Yuncang, Chen Gang, Xie Liang, et al. Mechanical factors play an important role in pectus excavatum with thoracic scoliosis. *J Cardiothorac Surg*. 2012;7(1):118.
4. Lam Gabrielle C, Hill Doug L, Le Lawrence H, Raso Jim V, Lou Edmond H. Vertebral rotation measurement: a summary and comparison of common radiographic and CT methods. *Scoliosis*. 2008;3(1):16.
5. Chi Wei-Min, Cheng Ching-Wei, Yeh Wei-Cheng, Chuang Shih-Chang, Chang Ti-Sheng, Chen Jian-Horng. Vertebral axial rotation measurement method. *Comput Methods Programs Biomed*. 2006;81(1):8–17.

6. Aaro S, Dahlborn M, Svensson L. Estimation of vertebral rotation in structural scoliosis by computer tomography. *Acta Radiol Diagn.* 1978;19(6):990–992.
7. Yazici M, Acaroglu E, Alanay A, Deviren V, Cila A, Surat A. Measurement of vertebral rotation in standing versus supine position in adolescent idiopathic scoliosis. *J Pediatr Orthop.* 2001;21(2):252–256.
8. Janssen M, Kouwenhoven J, Schlosser T, et al. Analysis of preexistent vertebral rotation in normal infantile, juvenile and adolescent spine. *Spine.* 2011;36(7):486–491.
9. Westphal FL, Lima LC, Lima JC, Chaves AR, Santos VL, Ferreira BL. Prevalence of pectus carinatum and pectus excavatum in students in the city of Manaus. *Braz J Bras Pneumol.* 2009;35(3):221–226.
10. Niedbala A, Adams M, Boswell WC, Considine JM. Acquired thoracic scoliosis following minimally invasive repair of pectus excavatum. *Am Surg.* 2003;69(6):530–533.