


CASE REPORT

Open Access



# Multiple attacks of transient monocular visual loss in a previously healthy man: a possible complication after COVID-19 vaccination?

Leonardo Provetti Cunha<sup>1,2,3\*</sup> , Ângelo Atalla<sup>2</sup>, José de Melo Costa-Neto<sup>3</sup>,  
Luciana Virgínia Ferreira Costa-Cunha<sup>3</sup>, Rony Carlos Preti<sup>4</sup>, Leandro Cabral Zacharias<sup>4</sup> and  
Mário Luiz Ribeiro Monteiro<sup>4</sup>

## Abstract

**Background:** The present case aims to describe a previously healthy man who presented multiple attacks of transient monocular visual loss after Pfizer-BioNTech COVID-19 vaccination and to discuss the possible mechanisms related to occurrence of this condition.

**Case presentation:** We report a case of multiple attacks of transient monocular visual loss in a previously healthy middle-aged man two weeks after Pfizer-BioNTech COVID-19 vaccination. TVL attacks were described as sudden and painless complete visual loss, lasting about one minute, followed by a full recovery. He presented several non-simultaneous attacks in both eyes, 16 in the right eye, and 2 in the left eye on the same day, fifteen days after receiving the second dose of the Pfizer-BioNTech COVID-19 vaccine. The brain's magnetic resonance angiography, echocardiogram, and doppler ultrasound imaging of the carotid and vertebral arteries were non-revealing. The complete blood exam revealed a slightly elevated C-reactive protein test. We assessed fundus examination during the transient visual loss attack and revealed diffuse vascular narrowing for both arterial and venous branches, notably in the emergence of the optic disc in right eye. In addition, the circumpapillary optical coherence tomography angiography (OCTA) vessel density map was reduced. Oral verapamil hydrochloride 60 mg twice daily was initiated, and the attacks of transient visual loss improved after two days.

**Conclusions:** To date, and the best of our knowledge, this is the first case report of multiple transient monocular visual loss attacks due to retinal vasospasm in a previously healthy middle-aged man documented by fundus retinography and OCTA. We discuss in this article the possible association of retinal vasospasm and Pfizer-BioNTech COVID-19 vaccination, probably related to vaccine-induced inflammation.

**Keywords:** Retinal vasospasm, Amaurosis fugax, Transient monocular visual loss, COVID-19 vaccine, Pfizer-BioNTech, Optical coherence tomography angiography

## Background

The COVID-19 pandemic, started in December 2019, led to sanitary, social, and economic impact at the global level, resulting in massive morbidity and mortality rates. Since then, a great search for treatments and vaccines

\*Correspondence: [leonardo\\_provetti@yahoo.com.br](mailto:leonardo_provetti@yahoo.com.br)

<sup>3</sup> Juiz de Fora Eye Hospital, Av. Rio Branco, 4051, Bom Pastor, Juiz de Fora, MG 36021-660, Brazil

Full list of author information is available at the end of the article



© The Author(s) 2022. **Open Access** This article is licensed under a Creative Commons Attribution 4.0 International License, which permits use, sharing, adaptation, distribution and reproduction in any medium or format, as long as you give appropriate credit to the original author(s) and the source, provide a link to the Creative Commons licence, and indicate if changes were made. The images or other third party material in this article are included in the article's Creative Commons licence, unless indicated otherwise in a credit line to the material. If material is not included in the article's Creative Commons licence and your intended use is not permitted by statutory regulation or exceeds the permitted use, you will need to obtain permission directly from the copyright holder. To view a copy of this licence, visit <http://creativecommons.org/licenses/by/4.0/>. The Creative Commons Public Domain Dedication waiver (<http://creativecommons.org/publicdomain/zero/1.0/>) applies to the data made available in this article, unless otherwise stated in a credit line to the data.

against the virus began, with unprecedented efforts in the history of humankind. As a result, large-scale vaccination significantly impacted the number of hospitalizations and deaths and represents a successful strategy against the COVID-19 pandemic [1]. On the other hand, this mass vaccination brought many complications, some mild and transient, such as local pain, myalgia, fever, and weakness and, others potentially serious, such as myelitis, myocarditis, infarction, stroke, and thrombosis [2–4]. Many visual complications related to COVID-19 vaccination have been reported, such as diplopia, acute macular neuroretinopathy, central serous retinopathy, retinal vein thrombosis, papilledema, optic neuritis, uveitis, multiple evanescent white dot syndrome, Vogt-Koyanagi-Harada disease and Graves' disease [5–9].

The present case aims to describe a previously healthy man who presented multiple attacks of transient monocular visual loss after Pfizer-BioNTech COVID-19 vaccination and to discuss the possible mechanisms related to occurrence of this condition.

### Case presentation

A 50 years-old previously healthy white man, with no migraine history, presented multiple episodes of monocular transient visual loss (TVL). TVL attacks were described as sudden and painless complete visual loss, lasting about one minute, followed by a full recovery without any prodromal signs or other visual or systemic symptoms. He described several non-simultaneous attacks in both eyes (OU), 16 in the right eye (OD) and 2 in the left eye on the same day. Fifteen days before, the patient received the second dose of the Pfizer-BioNTech COVID-19 vaccine, without any side effects, only a mild arm sore at the injection site. There is no previous history of COVID-19 infection, systemic arterial hypertension, or any other previous medical condition. In addition, the patient denied the use of any medication. He was referred to the emergence department, and the stroke fast track investigation protocol was proceeded. Neurological examination was unremarkable. Magnetic resonance angiography of the brain, echocardiogram, and doppler ultrasound imaging of the carotid and vertebral arteries were non-revealing. Complete blood count, Westergren erythrocyte sedimentation rate, D-dimer level, Antithrombin III, fibrinogen and protein C and S tests; serum electrophoresis, C3 and C4, anti-dsDNA, anti-Ro, anti-Sm, circulating immune complexes, indirect immunofluorescence for anti-nuclear antibodies on HEP-2 cells, anticardiolipine-IgM and IgG tests were normal. Serological tests for infectious diseases such as HIV, syphilis, toxoplasmosis, *Bartonella henselae*, cytomegalovirus, herpes simplex were negative. The C-reactive protein test was slightly elevated (8,3 mg/dl, reference value

up to 6,0 mg/dl). The next day, the patient was referred for ophthalmic evaluation. The best-corrected visual acuity was 20/20 in OU. External eye examination, ocular motility, and anterior segment were normal. The pupils were equal in size, with no afferent pupillary defect. On the fundus exam, no emboli or other abnormalities were found.

Optical coherence tomography (OCT) and OCT angiography (OCTA) scanning of both optic disc and macular area were within normal limits. Automated visual field testing was also normal. However, the patient reported another episode of sudden visual loss in OD while in the waiting room. Fundus photography during the attack, revealed diffuse vascular narrowing for both arterial and venous branches, notably in the emergence of the optic disc. In addition, the circumpapillary OCTA vessel density map was reduced. Figure 1 shows both fundus and OCTA images before and during the attack. So, the retinal vasospasm diagnosis was made. Oral verapamil hydrochloride 60 mg twice daily was initiated, and the attacks of TVL disappeared after two days.

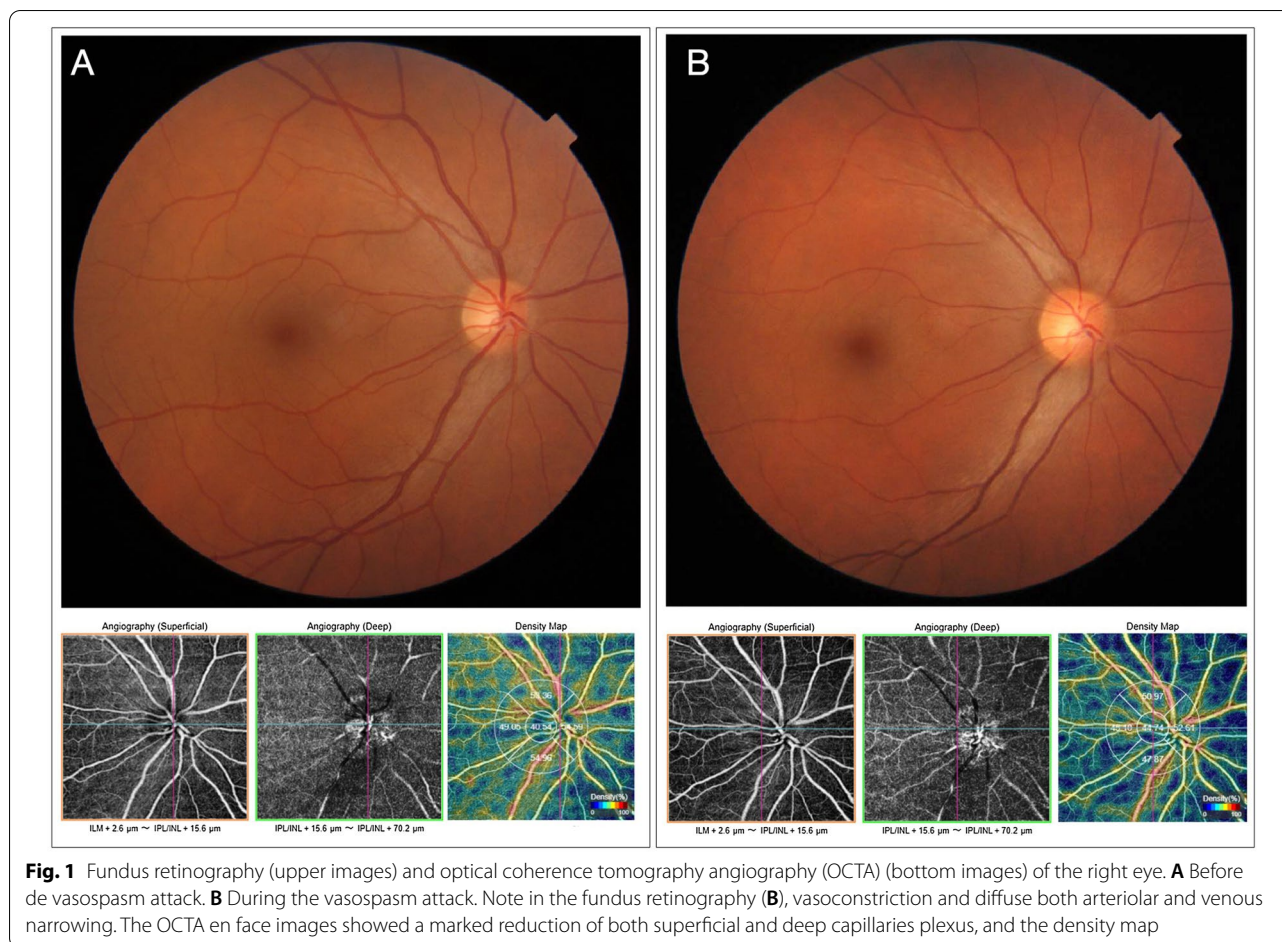
### Discussion and conclusions

Transient monocular visual loss, or amaurosis fugax, is caused by an abrupt and temporary reduction of blood flow to the optic disc, choroid, and retina [10]. There are several causes related to this condition, and thromboembolism, is one of the leading causes. However, extensive investigation ruled out any emboli source. Furthermore, fundus photography during the event clearly showed that retinal vasospasm was the mechanism in our case, as suggested in several previous studies [11, 12].

Ocular vasospasm in conditions where the inflammatory mechanism may play an important role had been well established, such as giant cell arteritis, systemic lupus erythematosus, infectious diseases, antiphospholipid antibody syndrome, Bechet's disease, and rheumatoid arthritis [10, 13].

Most of these conditions can lead to vasospasm by increasing intravascular concentration of endothelin-1, a peptide produced and released by vascular endothelial cells. In addition, interleukin-1, a peptide involved in the inflammatory process, can increase the production of endothelin-1. Therefore, the combination of these events may justify the vasospasm secondary to an inflammatory process [10].

The occurrence of inflammatory events related to COVID-19 vaccination has already been described in previous studies, such as myocarditis, Guillain-Barré syndrome, transverse myelitis, neuromyelitis optica, optic neuritis, and others intraocular inflammatory processes [4–6, 14].



A recently published case reported a bilateral transient visual field defect experienced by a 42-year-old Thai ophthalmologist after the COVID-19 vaccination (CoronaVac, Sinovac Biotech Ltd). He presented left congruous hemianopia with respect to the vertical midline in the visual field test. The authors hypothesized that the possible mechanism was acute vasospasm of the posterior visual pathway, triggered by the CoronaVac vaccine [15]. As in our case, the authors did not find any other condition that could be associated with vasospasm.

In a previous report, Santovito and Pinna described a case of acute visual acuity and visual field loss after the second dose of the Pfizer-BioNTech COVID-19 vaccine [16]. In this case, the patient reported several visual and systemic symptoms suggestive of migraine, possibly triggered by COVID-19 vaccination. This report, like ours, reinforces the possibility of vasospasm events triggered after the Pfizer-BioNTech COVID-19 vaccine.

In accordance with vascular and inflammatory theory, other studies have reported several ocular inflammatory conditions related to COVID-19 vaccination. For example, Valenzuela et al. reported a case of acute macular

neuroretinopathy immediately following the Pfizer-BioNTech COVID-19 vaccine administration [17]. Another article reported several inflammatory ocular events after COVID-19 vaccination, including the Oxford-AstraZeneca, ModernaTX, Janssen Johnson & Johnson, and Pfizer-BioNTech vaccines [18].

Although multiple attacks of transient visual loss due to retinal vasospasm possibly triggered by vaccine-related inflammatory events seem reasonable, we cannot assume that these events are directly related. It is possible that the retinal vasospasm could have occurred by chance or secondary to an underlying condition.

In conclusion, to date, and the best of our knowledge, this is the first case report of multiple transient monocular visual loss attacks due to retinal vasospasm after the Pfizer-BioNTech COVID-19 vaccination documented by fundus retinography and OCT angiography. The probably related mechanism was vaccine-induced inflammation. Although mass vaccination is considered an important tool in the fight against the COVID-19 pandemic, our case serves to emphasize that, we must be aware of its potential side effects to diagnose and treat appropriately.

**Acknowledgements**

Not applicable.

**Author contributions**

LPC: Substantial contribution to conception and design, acquisition of data, drafting of the manuscript; critical revision of the manuscript. AA: analyzed and interpreted the patient data regarding the hematological disease; critical revision of the manuscript. JMCN: ophthalmological evaluation, acquisition of data. LVFCC: acquisition of data, critical revision of the manuscript. RCP: drafting of the manuscript; critical revision of the manuscript. LCZ: drafting of the manuscript; critical revision of the manuscript. MLRM: drafting of the manuscript; critical revision of the manuscript. All authors read and approved the final manuscript.

**Authors' information**

LPC: Associate Professor at the Faculty of Medicine of the Federal University of Juiz de Fora; AA: Associate Professor at the Federal University of Juiz de Fora; JCMN: Physician at the Hospital de Olhos Juiz de Fora; LVFCC: Physician at the Hospital de Olhos Juiz de Fora; RCP: Professor of the Postgraduate Program in Ophthalmology at the University of São Paulo; LCZ: Professor at the Postgraduate Program in Ophthalmology at the University of São Paulo; MLRM: Associate Professor at the University of São Paulo School of Medicine.

**Funding**

There has been no significant financial support for this work that could have influenced its outcome. No funding was received for this work.

**Availability of data and materials**

The datasets used and/or analyzed during the current study are available from the corresponding author on reasonable request.

**Declarations****Ethics approval and consent to participate**

For this study, a signed consent form was obtained.

**Consent for publication**

For this study, a signed consent form for publication was obtained.

**Competing interests**

The authors declare that they have no competing interests. The authors declare no conflicts of interest associated with this publication.

**Author details**

<sup>1</sup>Department of Ophthalmology, Federal University of Juiz de Fora Medical School, Juiz de Fora, MG, Brazil. <sup>2</sup>Department of Hematology, Federal University of Juiz de Fora Medical School, Juiz de Fora, MG, Brazil. <sup>3</sup>Juiz de Fora Eye Hospital, Av. Rio Branco, 4051, Bom Pastor, Juiz de Fora, MG 36021-660, Brazil. <sup>4</sup>Department of Ophthalmology, University of São Paulo Medical School, São Paulo, Brazil.

Received: 7 February 2022 Accepted: 4 June 2022

Published online: 20 June 2022

**References**

- Lopez Bernal J, Andrews N, Gower C, Robertson C, Stowe J, Tessier E, et al. Effectiveness of the Pfizer-BioNTech and Oxford-AstraZeneca vaccines on covid-19 related symptoms, hospital admissions, and mortality in older adults in England: test negative case-control study. *BMJ*. 2021;373:n1088.
- Patone M, Mei XW, Handunnetthi L, Dixon S, Zaccardi F, Shankar-Hari M, et al. Risks of myocarditis, pericarditis, and cardiac arrhythmias associated with COVID-19 vaccination or SARS-CoV-2 infection. *Nat Med*. 2021;28(2):410–22.
- Kim HW, Jenista ER, Wendell DC, Azevedo CF, Campbell MJ, Darty SN, et al. Patients with acute myocarditis following mRNA COVID-19 vaccination. *JAMA Cardiol*. 2021;6(10):196–201.
- Goss AL, Samudralwar RD, Das RR, Nath A. ANA investigates: neurological complications of COVID-19 vaccines. *Ann Neurol*. 2021;89(5):856–7.
- Testi I, Brandão-de-Resende C, Agrawal R, Pavesio C, Group C-VOIES. Ocular inflammatory events following COVID-19 vaccination: a multinational case series. *J Ophthalmic Inflamm Infect*. 2022;12(1):4.
- Ng XL, Betzler BK, Testi I, Ho SL, Tien M, Ngo WK, et al. Ocular adverse events after COVID-19 vaccination. *Ocul Immunol Inflamm*. 2021;29(6):1216–24.
- Pichi F, Aljneibi S, Neri P, Hay S, Dackiw C, Ghazi NG. Association of ocular adverse events with inactivated COVID-19 vaccination in patients in Abu Dhabi. *JAMA Ophthalmol*. 2021;139(10):1131–5.
- Eleiwa TK, Gaier ED, Haseeb A, ElSheikh RH, Sallam AB, Elhusseiny AM. Adverse Ocular Events following COVID-19 Vaccination. *Inflamm Res*. 2021;70(10–12):1005–9.
- Alhumaid S, Al Mutair A, Al Alawi Z, Rabaan AA, Tirupathi R, Alomari MA, et al. Anaphylactic and nonanaphylactic reactions to SARS-CoV-2 vaccines: a systematic review and meta-analysis. *Allergy Asthma Clin Immunol*. 2021;17(1):109.
- Flammer J, Pache M, Resink T. Vasospasm, its role in the pathogenesis of diseases with particular reference to the eye. *Prog Retin Eye Res*. 2001;20(3):319–49.
- Burger SK, Saul RF, Selhorst JB, Thurston SE. Transient monocular blindness caused by vasospasm. *N Engl J Med*. 1991;325(12):870–3.
- Bernard GA, Bennett JL. Vasospastic amaurosis fugax. *Arch Ophthalmol*. 1999;117(11):1568–9.
- Phatak S, Jaison J, Soman M, Mohan A, Nair RU. Retinal vasospastic phenomenon in a known case of systemic lupus erythematosus. *Indian J Ophthalmol*. 2020;68(11):2575–7.
- Abbate A, Gavin J, Madanchi N, Kim C, Shah PR, Klein K, et al. Fulminant myocarditis and systemic hyperinflammation temporally associated with BNT162b2 mRNA COVID-19 vaccination in two patients. *Int J Cardiol*. 2021;340:119–21.
- Jumroendarasame C, Panyakorn S, Othong R, Jumroendarasame A, Srimanan W, Tipparat K. Transient visual field loss after COVID-19 vaccination: experienced by ophthalmologist, case report. *Am J Ophthalmol Case Rep*. 2021;24:101212.
- Santovito LS, Pinna G. Acute reduction of visual acuity and visual field after Pfizer-BioNTech COVID-19 vaccine 2nd dose: a case report. *Inflamm Res*. 2021;70(9):931–3.
- Valenzuela DA, Groth S, Taubenslag KJ, Gangaputra S. Acute macular neuroretinopathy following Pfizer-BioNTech COVID-19 vaccination. *Am J Ophthalmol Case Rep*. 2021;24:101200.
- Bolletta E, Iannetta D, Mastrofilippo V, De Simone L, Gozzi F, Croci S, et al. Uveitis and other ocular complications following COVID-19 vaccination. *J Clin Med*. 2021;10(24):5960.

**Publisher's Note**

Springer Nature remains neutral with regard to jurisdictional claims in published maps and institutional affiliations.

**Ready to submit your research? Choose BMC and benefit from:**

- fast, convenient online submission
- thorough peer review by experienced researchers in your field
- rapid publication on acceptance
- support for research data, including large and complex data types
- gold Open Access which fosters wider collaboration and increased citations
- maximum visibility for your research: over 100M website views per year

At BMC, research is always in progress.

Learn more [biomedcentral.com/submissions](https://biomedcentral.com/submissions)

