

CLINICAL ARTICLE

Modified Broström Repair With and Without Augmentation Using Suture Tape for Chronic Lateral Ankle Instability

Ding-Li Xu, MD¹, Kai-Feng Gan, MD², Hao-Jie Li, MD³, Shu-Yi Zhou, MD³, Zhen-Qi Lou, MD³, Yang Wang, MD¹, Guo-Qin Li, MD¹, Chao-Yue Ruan, MD¹, Xu-dong Hu, PHD¹, Yun-Lin Chen, MD¹, Wei-Hu Ma, MD¹

¹Department of Orthopaedic, Ningbo No.6 Hospital, ²Department of Orthopaedic, Ningbo Medical Centre Lihuli Hospital and ³Department of Orthopaedic, Medical College of Ningbo University, Ningbo, China

Objective: To compare the clinical and radiological outcome between the modified Broström repair with augmentation using suture tape (MBA) and the modified Broström repair (MB) for patients with chronic lateral ankle instability.

Methods: A retrospective study was performed in Ningbo No. 6 Hospital. The study included 53 patients who underwent surgical treatment from March 2014 to July 2016 and were followed for 2 years. A total of 25 patients underwent modified Broström repair with augmentation using suture tape, and 28 patients were treated with modified Broström repair. Patients were evaluated using the American Orthopedic Foot and Ankle Scale (AOFAS) hindfoot scale, the Foot and Ankle Ability Measure (FAAM) score, range of motion (ROM), and the visual analogue scale (VAS). The talar tilt angle (TTA) and anterior talar translation (ATT) were used to evaluate the mechanical stability. All radiological outcomes were measured by two orthopaedic surgeons, with the measurements repeated 3 days later.

Results: The mean age of the patients was 26.6 ± 17.8 years in the MBA group and 28.1 ± 19.4 years in the MB group, and no statistical difference in preoperative data was found between two groups. There were significant differences before and after the operation within the groups. Both groups achieved satisfactory outcomes, and significant improvements (VAS, FAAM, AOFAS, TTA, and ATT) were observed between the 1-year follow-up and final follow-up ($P < 0.05$). The MBA group showed significant improvement in the FAAM Sport (87.1 ± 5.4 vs 78.2 ± 12.0 , $P = 0.001$) and total scores (93.1 ± 2.3 vs 90.5 ± 5.1 , $P = 0.027$) at the final follow-up compared with the MB group, and for the other outcomes, there were no significant differences between the two groups.

Conclusion: The modified Broström repair with augmentation using suture tap for chronic lateral ankle instability achieves a better outcome; however, further research is necessary.

Key words: Chronic lateral ankle instability; Modified Broström repair; Suture tape augmentation

Introduction

Ankle sprains are very common in the general community. Acute ankle sprains are mostly addressed with palliative treatment¹, but many patients may develop chronic lateral ankle instability (CLAI), which will have an impact on their daily lives. As a result, operative intervention is sometimes

required. Although CLAI has a high prevalence rate, the optimal surgical method remains controversial².

The Broström repair was first described in 1966. It involves direct repair of the torn ends of the anterior talofibular ligament and calcaneofibular ligament by midsubstance suturing³. Hamilton *et al.* described the

Address for correspondence Wei-hu Ma, MD, Department of Orthopaedics, Ningbo No.6 Hospital, Ningbo, Zhejiang Province, China 315000 Tel: 18906628168; Fax: 0086-0574-87801999; Email: wei_hu_ma@163.com; Kai-feng Gan, MD, Department of Orthopaedics, Ningbo Medical Centre Lihuli Hospital, Ningbo, Zhejiang Province, China 315000 Tel: 15724288924; Fax: 0086-0574-87018568; Email: gankaifeng@163.com

Disclosure: This study was supported by the National Natural Science Foundation of China (81400998) and the Natural Science Foundation of Zhejiang Province (ly19h060002).

Received 13 January 2019; accepted 19 July 2019

modified Broström repair, which is more suitable for patients because it enables a full range of plantarflexion and dorsiflexion and normal peroneal function⁴. The common advantages of this procedure include its simplicity and reliability, and it is performed with the original ligament tissue, which does not damage the normal tendon. Liu *et al.* reported that 25 patients with chronic lateral ankle instability who were treated with modified Broström repair yielded satisfactory outcome, and the signal/noise ratio of anterior talofibular ligaments was significantly decreased compared to preoperation (8.4 ± 2.4 vs 11.2 ± 3.4 , $P < 0.001$)⁵. Maffulli *et al.* reported that 42 patients with chronic lateral ankle instability who underwent ankle arthroscopy and anterior talofibular Broström repair had significant improvements in ankle laxity, AOFAS scores, and Kaikkonen scales during 9-year follow-up visits⁶.

Although the modified Broström repair is often used to treat CLAI, this procedure is not always the best surgical technique due to significant technical advances in surgical procedures for treating chronic lateral ligament instability and some reported complications, including ankle instability and wound infection. Petrer *et al.* reported on 55 patients with chronic lateral ankle instability who failed nonoperative management and underwent modified Broström repair. Although those patients showed significant improvement in the Foot and Ankle Outcome Scale after the operation ($P < 0.001$), 3 patients reported residual instability after a traumatic re-rupture; there were 2 patients with superficial wound infection and there was one patient with temporary neuropathia of the superficial peroneal nerve⁷.

To maintain stability and reduce complications, there is an increasing interest in ligament augmentation using suture tape to treat this condition⁸. Messer *et al.* reported that 21 patients with chronic lateral ankle instability treated using the modified Broström procedure with suture anchors had a significantly lower "overall satisfaction" score ($P = 0.013$), and that it results in a good or excellent outcome in the majority of patients with few complications⁹. Byung-Ki Cho *et al.* reported that, in 34 young female patients, ligament repair using suture tape yielded satisfactory functional results¹⁰. Li *et al.* reported on 62 patients with chronic lateral ankle instability treated with the Gould-modified Broström procedure with suture anchors who had anatomical ligament reconstruction and found that it yielded good clinical outcomes¹¹. Some researchers have also conducted biomechanical evaluations. Schuh *et al.* reported on 18 subjects randomly assigned to three different groups (traditional Broström [TB]; tape augmentation internal brace [IB]; and tape augmentation suture anchor repair [SA]), and the IB group had statistically superior performance¹². Waldrop *et al.*¹³ reported on 24 fresh-frozen cadaveric specimens divided into four groups (intact control group, traditional Broström repair, talus suture anchor modifications, and fibula suture anchor modifications of the Broström procedure), and found that the suture anchor groups (79.2 ± 34.3 N) had better strength than the Broström repair group (68.2 ± 27.8 N). With increased knowledge of chronic

lateral instability and surgical treatment, the most suitable operative method for this disease remains controversial, and whether the modified Broström with suture tape yields better outcomes remains unclear.

Until now, few studies have compared the clinical and radiological outcomes between the modified Broström repair with and without augmentation using suture tape for patients with chronic lateral ankle instability, and considered whether the modified Broström repair with and without augmentation using suture tape can provide better clinical outcome and diminish complications. Therefore, the present study compares the outcomes of those two surgical methods and aims to provide surgeons with information regarding whether: (i) ligament augmentation using suture tape for chronic ankle instability in patients may provide better strength after surgery; (ii) using suture tape can prevent complications including ligament re-rupture; (iii) the modified Broström repair with augmentation using suture tape has a better long-term outcome.

Patients and Methods

Patients

This was a retrospective study, and all data were collected from clinical records. The inclusion criteria were as follows: (i) patients over the age of 18 with chronic lateral ankle instability; (ii) patients with at least 3 months of failed palliative therapy before the operation; and (iii) patients treated with modified Broström repair or modified Broström repair with augmentation using suture tape. The exclusion criteria were as follows: (i) patients who previously underwent surgical treatment involving lateral ankle ligaments; (ii) patients with bilateral ankle instability; and (iii) patients with a history of infection of the ankle¹⁴. Here, we enrolled 53 patients who suffered from chronic lateral ankle instability who received surgical intervention in our hospital during March 2014 to July 2016 with a follow-up period of 2 years. This study protocol was approved by the institutional review board in Ningbo No. 6 Hospital.

In this study, 25 patients underwent the modified Broström with augmentation using suture tape (MBA group) and the other 28 patients underwent the modified Broström repair (MB group). The mean age of the patients was 26.6 years (range, 16–50 years) in the MBA group and 28.1 years (range, 17–55 years) in the MB group. Clinical and radiological data were collected by case notes. There were no differences between the two groups in rehabilitation protocols.

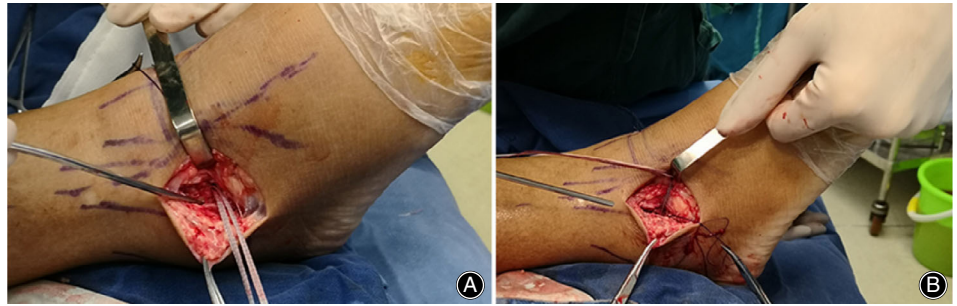
Surgical Procedure

Modified Broström Repair with Augmentation Using Suture Tape

Anesthesia and Position

All patients in the group received surgery under general anesthesia. After successful anesthesia, the patient was placed in the supine position in an orthopaedic bed.

Fig. 1 Modified Broström repair with augmentation using the suture tape. (A) The suture tape was inserted at the footprint of the anterior talofibular ligament (ATFL) on the fibula. (B) Lateral ligaments and articular capsule were reattached with suture tape.



Arthroscopy Debridement

A standard arthroscopy was performed to allow visualization and debridement of the joint, including osteophyte removal and synovectomies as needed.

Exposure

Along the anterior and inferior borders of the lateral malleolus, a curved skin incision was made.

Preparation of Holes

The first drill hole was made at the footprint of the anterior talofibular ligament (ATFL) on the talus. Once the hole was prepared, the 3.5-mm SwiveLock anchor with FiberTape (Arthrex, Florida, America) was inserted. The second drill hole was then made at the footprint of the ATFL on the fibula.

Insertion of InternalBrace

The InternalBrace (Arthrex, Florida, USA) was anchored into the fibula with a 3.5-mm SwiveLock anchor. Care was taken to insert the InternalBrace under adequate tension. There should be 1–2 mm of play in the brace to allow normal physiological movement of the repaired lateral ligament complex (Figs 1 and 2). Then, the modified Broström repair was performed.

The Modified Broström Repair

Anesthesia and Position

All patients in the group received surgery under general anesthesia. After successful anesthesia, the patient was placed in the supine position in an orthopaedic bed.

Arthroscopy Debridement

A standard arthroscopy was performed to allow visualization and debridement of the joint, including osteophyte removal and synovectomies as needed.

Exposure

Then, along the anterior and inferior borders of the lateral malleolus, a curved skin incision was made. The location of the inferior extensor retinaculum was identified. The anterior talofibular (ATF) ligament was divided into two parts 3 mm from the fibular margin.

Anchors Insertion

The periosteum was carefully dissected from the anterior and distal margins of the lateral malleolus and retracted to the proximal area. Two 3.5-mm SwiveLock anchors were inserted into the anteroinferior border of the lateral malleolus.

Repair the Ligament

While maintaining the ankle joint in neutral flexion and slight eversion, the capsule and ATF ligament were securely fixed to the fibula using horizontal mattress sutures¹⁵. The

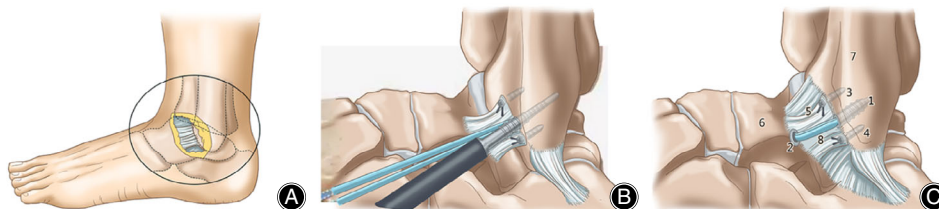


Fig. 2 (A) A curved skin incision along the anterior and inferior borders of the lateral malleolus. We exposed the soft tissue, and found the anterior talofibular ligament. (B) We attached the anterior talofibular ligament to the lateral malleolus by anchors, and two 3.5 mm SwiveLocks with suture tape were inserted into the fibula and talus. (C) The Modified Broström repair with augmentation using suture tape was accomplished. 1,2: SwiveLock anchor. 3,4: Anchor. 5: Anterior talofibular ligament. 6: Talus. 7: Lateral malleolus. 8: Suture tape.

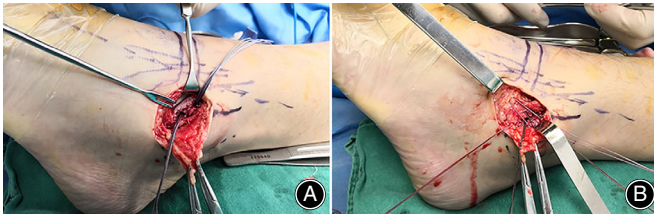


Fig. 3 Modified Broström repair. (A) A drill hole was made at the footprint of the anterior talofibular ligament (ATFL) on the talus and fibula. (B) Repaired lateral ligament complex.

fibular periosteum was overlapped and imbricated at the attachment site of the ATF ligament (Fig. 3).

Outcomes Assessment

American Orthopedic Foot and Ankle Scale Hind Foot Score

The American Orthopedic Foot and Ankle Scale hind foot score, which is a self-administered test, was used to evaluate the ankle function of patients¹⁶ and to assess surgery-related improvement¹⁷. The AOFAS scale, which contains three questionnaires (for Pain, Function, and Alignment), was evaluated preoperation and 1 year and 2 years after the operation¹⁸.

Visual Analogue Scale

Ankle pain is an important sign and a frequent patient complaint. We used the VAS score¹⁹ to assess the degree of patients' pain. A 10-point visual analog scale (VAS) was used for pain, and patients recorded the VAS by themselves.

Foot and Ankle Ability Measure

The Foot and Ankle Ability Measure (FAAM), which is a widely used measure of chronic lateral ankle instability, was applied to evaluate sports activities (eight questions) and activities of daily life (21 questions)²⁰. Every question is rated from 0 to 4, with 0 representing "unable to do" and four meaning "no difficulty." N/A responses are not counted. Therefore, each subscale has a maximum potential score (84 Activity of daily living and 32 Sport subscales). The scores for two subscales are divided by the maximum potential score and multiplied by 100 to obtain a percentage. As a result, the higher values mean greater physical function²¹.

Range of Motion

In addition, the range of motion (ROM), which defines the mobile function of the ankle, was used to measure ankle mobility²², and the ROM was measured by angulometer preoperation and at each follow-up visit.

Radiological Outcomes

The talar tilt angle²³ was defined as the angle between the distal articular surface of the tibia and the proximal articular

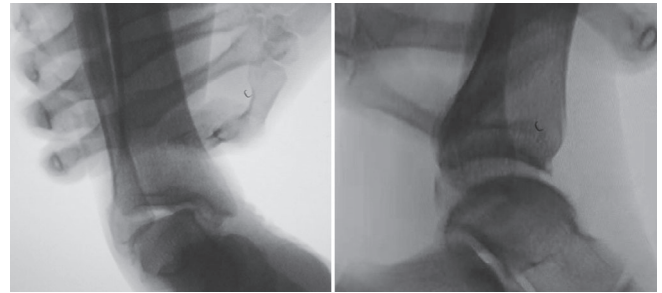


Fig. 4 The measurement of talar tilt angle (TTA) and anterior talar translation (ATT) in stress radiography with one hand immobilizing the crus and the other hand using the spring dynamometer to pull the foot with gauze.

surface of the talus on the varus stress view. The anterior talar translation²⁴ was defined as the shortest distance between the posterior articular border of the distal tibia and the posterior articular surface of the talus on the lateral X-ray. The talar tilt angle (TTA) and degree of anterior talar translation (ATT) were independently measured in the anterior drawer and varus stress radiographs using a spring dynamometer with a loading force of 150 N (Fig. 4). All measures were repeated three times by two orthopaedic surgeons; then the outcomes were averaged.

Statistical Methods

SPSS (version 19.0, 2010; SPSS, Chicago, IL, USA) was used for statistical analysis. Paired data analysis correlated with clinical evaluations was performed to compare improvement between the preoperative, postoperative, and follow-up scores and to compare differences between the two groups. Comparison of the results using the AOFAS, FAAM, VAS and ROM scores and radiological outcomes was made using paired-sample *t*-tests, and one-way ANOVA tests were used to compare results between the two groups. Differences were considered significant when the *P*-value was <0.05.

Results

General Results

There was no significant difference in the general results for patients in both MB and MBA groups, including gender, age, body mass index (BMI), operation time, and blood loss.

The American Orthopedic Foot and Ankle Scale Hind Foot Score

Improvement in the AOFAS scores from preoperation (68.2 ± 9.5) to 1 year after surgery (92.9 ± 8.6) was significant ($P < 0.001$), and the AOFAS scores significantly improved between the 1-year and 2-year follow-up (92.9 ± 8.6 vs 97.5 ± 3.3 , $P < 0.001$) in the modified Broström repair with augmentation using suture tape group. Similarly, in the modified Broström repair group, the

TABLE 1 Comparison of the clinical outcomes between the two groups (mean ± standard deviation)

	MBA group	MB group	F-value	P-value
AOFAS				
Preoperative	68.2 ± 9.5	67.3 ± 10.6	0.117	0.734
1 years	92.9 ± 8.6	92.4 ± 8.6	0.062	0.805
2 years	97.5 ± 3.3	96.3 ± 6.0	0.771	0.384
VAS				
Preoperative	6.2 ± 10.9	6.4 ± 1.0	0.751	0.393
1 years	1.4 ± 0.9	1.7 ± 1.3	1.332	0.254
2 years	0.6 ± 0.7	0.7 ± 1.2	0.335	0.565
Dorsiflexion				
Preoperative	54.9 ± 1.1	54.9 ± 1.2	0.005	0.942
1 year	52.8 ± 1.0	52.9 ± 1.1	0.043	0.836
2 years	53.9 ± 1.1	54.0 ± 1.1	0.217	0.644
Plantar flexion				
Preoperative	14.0 ± 1.1	13.9 ± 1.1	0.049	0.825
1 year	12.0 ± 0.9	12.0 ± 1.0	0.231	0.695
2 years	13.1 ± 1.0	12.9 ± 1.1	0.277	0.601
FAAM ADL				
Preoperative	66.8 ± 8.2	67.8 ± 12.4	0.108	0.744
1 year	89.7 ± 3.8	90.4 ± 5.5	0.304	0.583
2 years	95.3 ± 1.9	95.2 ± 5.0	0.008	0.929
FAAM Sport				
Preoperative	35.8 ± 6.3	35.5 ± 9.5	0.013	0.908
1 year	73.8 ± 4.9	74.9 ± 12.2	0.191	0.664
2 years	87.1 ± 5.4	78.2 ± 12.0	11.704	0.001
FAAM Total				
Preoperative	58.2 ± 7.5	58.9 ± 11.3	0.055	0.816
1 year	85.3 ± 3.8	86.1 ± 7.2	0.271	0.605
2 years	93.1 ± 2.3	90.5 ± 5.1	5.218	0.027

AOFAS, American Orthopedic Foot and Ankle Scale; FAAM ADL, Foot and Ankle Ability Measure Activities of Daily Living score; VAS, visual analogue scale

AOFAS scores were significantly improved after surgery, with recovery experienced at 2-year follow-up (67.3 ± 10.6 , 92.4 ± 8.6 and 96.3 ± 6.0). The AOFAS score preoperation ($P = 0.734$), at 1-year follow-up ($P = 0.805$), and at 2-year follow-up ($P = 0.384$) showed no significant difference between the two groups (Table 1); at the 1-year follow-up, all patients had returned to exercise activity without difficulties.

Visual Analogue Scale

The decrease in the VAS was significant ($P < 0.001$) between preoperation and the 1-year follow-up, and also significantly decreased between the 1-year follow-up and the 2-year follow-up ($P < 0.001$) in the two groups. In the modified Broström repair with augmentation using suture tape group, the VAS is 6.2 ± 1.1 , 1.4 ± 0.9 , and 0.6 ± 0.7 at each time point, and for the modified Broström repair group is 6.4 ± 1.0 , 1.7 ± 1.3 , and 0.7 ± 1.2 , respectively. There was no significant difference between the two groups at each time.

Range of Motion

The mean dorsiflexion was 54.88 ± 1.13 preoperation, 52.80 ± 1.08 at the 1-year follow-up, and 53.88 ± 1.13 at the 2-year follow-up, and the mean plantar flexion was

13.96 ± 1.09 , 11.96 ± 0.98 , and 13.08 ± 0.99 , respectively, in the modified Broström repair with augmentation using suture tape group. In the the modified Broström repair group, the mean dorsiflexion was 54.86 ± 1.15 preoperation, 52.86 ± 1.14 at 1-year follow-up, and 53.86 ± 1.14 at 2-year follow-up, and the mean plantar flexion was 13.89 ± 1.10 , 11.96 ± 1.07 , and 12.93 ± 1.09 , respectively. There was no significant difference between the two groups at each time point.

Foot and Ankle Ability Measure

The Foot and Ankle Ability Measure Activities of Daily Living (FAAM ADL) score (89.7 ± 3.8 vs 66.8 ± 8.2 , $P < 0.05$), the Foot and Ankle Ability Measure sport (FAAM Sport) score (73.8 ± 4.9 vs 35.8 ± 6.3 , $P < 0.05$), and the Foot and Ankle Ability Measure (FAAM) Total scale (85.3 ± 3.8 vs 58.2 ± 7.5 , $P < 0.05$) were significantly improved at 1-year follow-up compared with preoperation in the modified Broström repair with augmentation using suture tape group. The modified Broström repair group had similarly improvement. There were significant differences in the FAAM Sport (87.1 ± 5.4 vs 78.2 ± 12.0 , $P = 0.001$) and FAAM Total (93.1 ± 2.3 vs 90.5 ± 5.1 , $P = 0.027$) at 2-year follow-up visit between the two groups. The MBA had 10.1% more than the MB group in the FMMA Sport score and 2.8% more in the

TABLE 2 Comparison of the radiological outcomes between the two groups (mean \pm standard deviation)

	MBA group	MB group	F value	P value
TTA				
Preoperation	14.0 \pm 3.2	14.2 \pm 3.5	0.193	0.662
1 year	3.3 \pm 1.58	2.9 \pm 1.7	0.885	0.351
2 years	2.4 \pm 1.3	2.7 \pm 1.4	0.407	0.527
ATT				
Preoperation	12.2 \pm 3.6	12.2 \pm 3.9	0.001	0.983
1 year	3.4 \pm 1.6	3.4 \pm 1.5	0.001	0.978
2 years	2.9 \pm 1.6	3.1 \pm 1.3	0.143	0.706

ATT, anterior talar translation; TTA, talar tilt angle

FMMA Total score at the 2 year follow-up visit. There was no significant difference between two groups at other visit times.

Radiological Outcomes

In the modified Broström repair with augmentation using suture tape group, the talar tilt angle (14.0 \pm 3.2 vs 3.3 \pm 1.58) and the anterior talar translation (12.2 \pm 3.6 vs 3.4 \pm 1.6) were significantly decreased between preoperation and 1-year follow-up ($P < 0.001$). These values decreased at the 2-year follow-up compared to the outcomes at 1-year follow-up; the TTA was from 3.3 \pm 1.6 to 2.4 \pm 1.3 ($P < 0.001$) and the ATT is from 3.4 \pm 1.6 to 2.9 \pm 1.6 ($P < 0.05$). In the modified Broström repair group, the talar tilt angle (14.2 \pm 3.5 vs 2.9 \pm 1.7) and anterior talar translation (12.2 \pm 3.9 vs 3.5 \pm 1.5) were significantly decreased at the 1-year follow-up ($P < 0.001$). The TTA was well maintained at the 2-year follow-up compared to the outcomes at the 1-year follow-up (2.7 \pm 1.4 vs 2.9 \pm 1.7, $P = 0.168$). The ATT decreased at the 2-year follow-up compared to the outcomes at the 1-year follow-up (3.1 \pm 1.3 vs 3.4 \pm 1.5, $P < 0.001$) (Table 2). There was no significant difference in TTA and ATT between the two groups at each time point.

Complications

Postoperative complications in the MB group included 1 case of mechanical instability, which was treated with modified Broström repair with augmentation using suture tape after the final follow-up, and 1 case of wound infection, which was healed within 10 days after palliative treatment including antibiotic therapy and routine wound management. In the MBA group, there were 3 cases of abnormal dorsal foot paresthesia, which may damage the superficial peroneal nerve, but all 3 patients recovered.

Discussion

Chronic lateral ankle instability is a common disease, but the best treatment procedure remains controversial. Several surgical procedures for chronic lateral instability of the

ankle have been applied. The modified Broström repair, which is an anatomic reconstruction, has shown satisfactory outcomes, but there are still some complications, including ankle instability and ligament tear. Huang *et al.* reported that, in 32 patients with chronic lateral ankle instability treated with the modified Broström repair, at the final follow-up, 16 patients were very satisfied with the results, 10 patients were satisfied, 3 patients rated their satisfaction as fair, and 1 patient was not satisfied with the results²⁵. In addition, Mark Porter *et al.* reported that, of 25 patients who underwent the modified Broström repair, 3 patients experienced recurrent ankle injuries²⁶. Similarly, Petrer *et al.* reported that 55 patients who were treated with modified Broström repair yielded satisfactory outcomes, but 3 patients reported residual instability after a traumatic retear, and there were 2 cases of superficial wound infection⁷. Moreover, Sami Hassan *et al.*²⁷ retrospectively analyzed 26 individuals (27 ankles) with the modified Broström repair, with 21 patients postoperatively providing AOFAS scores. Overall, of the 21 patients, 15 (71.4%) had excellent results, 3 (14.3%) had good results, 1 (4.8%) had a fair result, and 2 (9.5%) had poor results.

The modified Broström repair has good clinical outcomes, but it is significantly weaker than the native ATFL; Kirk *et al.*²⁸ reported that Broström repairs can only provide approximately 50% of the strength of the native, uninjured ligament. As a result, the modified Broström repair with augmentation using suture tape was proposed, and this method has received great interest among surgeons. Consequently, some researchers began to use this new procedure. For example, Chris Coetzee *et al.*¹⁴ stated that, in 81 patients (30 males and 51 females) with chronic lateral ankle instability who underwent modified Broström repair with augmentation using suture tape, the average AOFAS score was 94.3, and 79.0% of the subjects obtained a score of 90 or higher on the FAAM Sport subscale. The single-leg hop test (Limb Symmetry Index %) showed that 86.4% of patients achieved normal or near normal results. However, after the suture tape augmented repair, the ankle dorsiflexion comparisons showed a significant difference: 9.2 \pm 3.3 cm (operative side) and 10.4 \pm 3.7 cm (contralateral side).

Although there are many researchers studying the modified Broström repair or modified Broström repair with augmentation using suture tape, there are few prospective studies in which the two procedures are compared. In our study, we prospectively compared those two groups, and the most distinct findings were that the MBA group yielded a better outcome in the FAAM scale, and that, after surgery, patients could rehabilitate over time because at the final follow-up, the ankle function and radiological outcomes had progressed when compared with the 1-year follow-up. According to our results, improvements in the AOFAS scale, VAS scale, TTA, and ATT from preoperation to the 1-year follow-up were significant in both groups ($P < 0.001$). Moreover, the AOFAS scale, VAS, and ATT outcomes had

statistically significant progress in both groups at the final follow-up ($P < 0.05$). However, in the MB group, there was no significant difference in the TTA from the 1-year follow-up to the final follow-up ($P = 0.168$). This result means that both methods have satisfactory clinical outcomes for chronic lateral ankle instability, and the suture tape may provide better strength in the repaired ligament. Some studies have reported similar outcomes of ankle function recovery during follow-up²⁹.

During early mobilization, after the ankle ligament reconstruction, the elongation of ligaments is associated with ankle laxity and decreased instability³⁰; therefore, the suture tape augmentation allowed for higher stability of the ankle and reduced ligament elongation. The modified Broström repair with augmentation using suture tape has been thought to improve the ankle stability of the reconstructed ATFL. Schuh *et al.* reported that there was a 95% higher torque at failure in the suture tape augmentation construct compared to the Broström repair, and the ATFL reconstruction failed at an angle of 24.1°; in the suture tape group, failure occurred at 35.5° ($P = 0.02$)³¹. Functional exercise can promote the recovery of ligament strength and result in the improvement of ankle function. This is a possible reason why the FAAM Sport scale and FAAM total score were significantly improved between the two groups at the final follow-up. Some researchers have reported that functional exercise can enhance the levels of growth hormone in the serum and result in more tensile strength of the ligament³². There was no significant difference in range of motion between the two groups at preoperation, 1-year follow-up or final follow-up ($P > 0.05$).

Most complications occurred in patients with poor tissue quality or previously failed operations. Huang *et al.* reported that 9 out of 32 patients with chronic lateral ankle instability with generalized joint hypermobility sustained ankle sprains after the modified Broström procedure²⁵. Xu and Lee¹⁵ reported that failure rates were 11.4% (5 patients) in the laxity group and 1.8% (1 patient) in the nonlaxity group, and patients without generalized joint laxity showed significantly better clinical outcomes compared with the laxity patients. In our study, 1 case of mechanical instability in the MB group may have been caused by poor tissue quality. In our prospective study, there was no significant difference in radiological and clinical outcomes, except the FAAM scale; moreover, the outcomes were better, and the abnormal dorsal foot paresthesia had recovered during follow-up. The results of the present study reveal that the modified Broström repair with augmentation using suture tape provides a better effect than the modified Broström repair.

There were some limitations of our study. First, the number of cases was small, and our follow-up term was of a short-midterm range of 2 years; however, this can be solved with further research. Second, although we recruited a relatively homogeneous sample of patients based on demographics and physical activity level, the participants with chronic lateral ankle instability had diverse experiences with rehabilitation after surgery due to patients' different economic circumstances.

In conclusion, both methods can yield satisfactory outcomes for CLAI, and the modified Broström repair with augmentation using suture tape has a better functional outcome; however, more research needs to be undertaken.

References

- Al-Mohrej OA, Al-Kenani NS. Acute ankle sprain: conservative or surgical approach? *EFORT Open Rev*, 2016, 1: 34–44.
- Cho B-K, Park J-K, Choi S-M, SooHoo NF. A randomized comparison between lateral ligaments augmentation using suture-tape and modified Broström repair in young female patients with chronic ankle instability. *Foot Ankle Surg*, 2019, 25: 137–142.
- Brostrom L. Sprained ankles. VI. Surgical treatment of "chronic" ligament ruptures. *Acta Chir Scand*, 1966, 132: 551–565.
- Hamilton WG, Thompson FM, Snow SW. The modified Brostrom procedure for lateral ankle instability. *Foot Ankle*, 1993, 14: 1–7.
- Liu W, Li H, Hua Y. Quantitative magnetic resonance imaging (MRI) analysis of anterior talofibular ligament in lateral chronic ankle instability ankles pre- and postoperatively. *BMC Musculoskelet Disord*, 2017, 18: 397.
- Maffulli N, Del Buono A, Maffulli GD, *et al.* Isolated anterior Talofibular ligament Broström repair for chronic lateral ankle instability. *Am J Sports Med*, 2013, 41: 858–864.
- Petrera M, Dwyer T, Theodoropoulos JS, Ogilvie-Harris DJ. Short- to medium-term outcomes after a modified Brostrom repair for lateral ankle instability with immediate postoperative Weightbearing. *Am J Sports Med*, 2014, 42: 1542–1548.
- Matsui K, Burgesson B, Takao M, Stone J, Guillo S, Glazebrook M. Minimally invasive surgical treatment for chronic ankle instability: a systematic review. *Knee Surg Sports Traumatol Arthrosc*, 2016, 24: 1040–1048.
- Messer TM, Cummins CA, Ahn J, Kelikian AS. Outcome of the modified Brostrom procedure for chronic lateral ankle instability using suture anchors. *Foot Ankle Int*, 2000, 21: 996–1003.
- Cho B-K, Park K-J, Kim S-W, Lee H-J, Choi S-M. Minimal invasive suture-tape augmentation for chronic ankle instability. *Foot Ankle Int*, 2015, 36: 1330–1338.
- Li X, Killie H, Guerrero P, Busconi BD. Anatomical reconstruction for chronic lateral ankle instability in the high-demand athlete: functional outcomes after the modified Brostrom repair using suture anchors. *Am J Sports Med*, 2009, 37: 488–494.
- Schuh R, Benca E, Willegger M, *et al.* Comparison of Brostrom technique, suture anchor repair, and tape augmentation for reconstruction of the anterior talofibular ligament. *Knee Surg Sports Traumatol Arthrosc*, 2016, 24: 1101–1107.
- Waldrop NE 3rd, Wijdicks CA, Jansson KS, LaPrade RF, Clanton TO. Anatomic suture anchor versus the Brostrom technique for anterior talofibular ligament repair: a biomechanical comparison. *Am J Sports Med*, 2012, 40: 2590–2596.
- Coetzee JC, Ellington JK, Ronan JA, Stone RM. Functional results of open Brostrom ankle ligament repair augmented with a suture tape. *Foot Ankle Int*, 2018, 39: 304–310.
- Xu HX, Lee KB. Modified Brostrom procedure for chronic lateral ankle instability in patients with generalized joint laxity. *Am J Sports Med*, 2016, 44: 3152–3157.
- Roos EM, Brandsson S, Karlsson J. Validation of the foot and ankle outcome score for ankle ligament reconstruction. *Foot Ankle Int*, 2001, 22: 788–794.
- Schneider W, Jurenitsch S. Normative data for the American Orthopedic foot and ankle society ankle-hindfoot, midfoot, hallux and lesser toes clinical rating system. *Int Orthop*, 2016, 40: 301–306.
- Kitaoka HB, Alexander IJ, Adelaar RS, Nunley JA, Myerson MS, Sanders M. Clinical rating systems for the ankle-hindfoot, midfoot, hallux, and lesser toes. *Foot Ankle Int*, 1997, 18: 187–188.
- Heller GZ, Manuguerra M, Chow R. How to analyze the visual analogue scale: myths, truths and clinical relevance. *Scand J Pain*, 2016, 13: 67–75.
- Martin RL, Irgang JJ, Burdett RG, Conti SF, Van Swearingen JM. Evidence of validity for the foot and ankle ability measure (FAAM). *Foot Ankle Int*, 2005, 26: 968–983.
- Gonzalez-Sanchez M, Li GZ, Ruiz Munoz M, Cuesta-Vargas AI. Foot and ankle ability measure to measure functional limitations in patients with foot and ankle disorders: a Chinese cross-cultural adaptation and validation. *Disabil Rehabil*, 2017, 39: 2182–2189.
- Thornton J, Sabah S, Segaren N, Cullen N, Singh D, Goldberg A. Validated method for measuring functional range of motion in patients with ankle arthritis. *Foot Ankle Int*, 2016, 37: 868–873.

- 23.** Cox JS, Hewes TF. "Normal" talar tilt angle. *Clin Orthop Relat Res*, 1979, 39: 37–41.
- 24.** Beynnon BD, Webb G, Huber BM, Pappas CN, Renstrom P, Haugh LD. Radiographic measurement of anterior talar translation in the ankle: determination of the most reliable method. *Clin Biomech (Bristol, Avon)*, 2005, 20: 301–306.
- 25.** Huang B, Kim YT, Kim JU, Shin JH, Park YW, Kim HN. Modified Brostrom procedure for chronic ankle instability with generalized joint hypermobility. *Am J Sports Med*, 2016, 44: 1011–1016.
- 26.** Porter M, Shadbolt B, Ye X, Stuart R. Ankle lateral ligament augmentation versus the modified Brostrom-Gould procedure: a 5-year randomized controlled trial. *Am J Sports Med*, 2019, 47: 659–666.
- 27.** Hassan S, Thurston D, Sian T, Shah R, Aziz A, Kothari P. Clinical outcomes of the modified Brostrom technique in the management of chronic ankle instability after early, intermediate, and delayed presentation. *J Foot Ankle Surg*, 2018, 57: 685–688.
- 28.** Kirk KL, Campbell JT, Guyton GP, Parks BG, Schon LC. ATFL elongation after Brostrom procedure: a biomechanical investigation. *Foot Ankle Int*, 2008, 29: 1126–1130.
- 29.** Yoo JS, Yang EA. Clinical results of an arthroscopic modified Brostrom operation with and without an internal brace. *J Orthop Traumatol*, 2016, 17: 353–360.
- 30.** Omar M, Petri M, Dratzidis A, *et al.* Biomechanical comparison of fixation techniques for medial collateral ligament anatomical augmented repair. *Knee Surg Sports Traumatol Arthrosc*, 2016, 24: 3982–3987.
- 31.** Schuh R, Benca E, Willegger M, *et al.* Comparison of Broström technique, suture anchor repair, and tape augmentation for reconstruction of the anterior talofibular ligament. *Knee Surg Sports Traumatol Arthrosc*, 2016, 24: 1101–1107.
- 32.** West DWD, Lee-Barthel A, McIntyre T, Shamim B, Lee CA, Baar K. The exercise-induced biochemical milieu enhances collagen content and tensile strength of engineered ligaments. *J Physiol*, 2015, 593: 4665–4675.