



Contents lists available at ScienceDirect

## International Journal of Surgery Case Reports

journal homepage: [www.casereports.com](http://www.casereports.com)

# Magnetic resonance cholangiopancreatography uncovering massive gallbladder mucocele in a patient with ambiguous clinical and laboratory findings: A case report



Queenie Reyes<sup>a</sup>, Ruth Louise McLeod<sup>a</sup>, Katrina Fernandes<sup>a</sup>,  
Vijayragavan Muralidharan<sup>b</sup>, Laurence Weinberg<sup>a,b,\*</sup>

<sup>a</sup> Department of Anaesthesia, Austin Hospital, 145 Studley Rd., Heidelberg, Victoria 3084, Australia

<sup>b</sup> The University of Melbourne, Department of Surgery, Victoria, 3084, Australia

## ARTICLE INFO

## Article history:

Received 19 February 2017

Received in revised form 27 April 2017

Accepted 30 April 2017

Available online 19 May 2017

## Keywords:

Gallbladder

Mucocele

Magnetic resonance

cholangiopancreatography

## ABSTRACT

**INTRODUCTION:** Radiological imaging of the gallbladder is a fundamental aspect of assessing severity of acute cholecystitis in addition to guiding the optimal timing of surgical intervention. We present a case of acute severe cholecystitis with massive gallbladder mucocele initially presenting with equivocal and inconclusive clinical, laboratory, and ultrasound findings. Magnetic resonance cholangiopancreatography allowed accurate evaluation of cholelithiasis and demonstrated a massive gallbladder mucocele.

**CASE PRESENTATION:** A 39-year-old Caucasian female presented with mild right upper quadrant pain coupled with intermittent epigastric discomfort after meals. Diagnostic abdominal ultrasound could not reliably detect cystic or common bile duct stones due to patient obesity and meteorism. Computed tomography was contraindicated due to severe contrast allergy. Magnetic resonance cholangiopancreatography allowed timely, accurate evaluation of cholelithiasis. This subsequently demonstrated a massive gallbladder mucocele requiring urgent laparoscopic cholecystectomy.

**CONCLUSION:** Magnetic resonance cholangiopancreatography should be considered as a complementary imaging modality to assess patients presenting with atypical biliary symptoms, particularly when ultrasound is equivocal or inconclusive, clinical and laboratory findings are non-specific, and computer tomography is contraindicated. Magnetic resonance cholangiopancreatography can also be considered in patients with acute cholecystitis not adherent to a specific severity grade.

© 2017 The Author(s). Published by Elsevier Ltd on behalf of IJS Publishing Group Ltd. This is an open access article under the CC BY-NC-ND license (<http://creativecommons.org/licenses/by-nc-nd/4.0/>).

## 1. Background

Radiological imaging of the gallbladder is a fundamental component of assessing severity of acute cholecystitis in addition to guiding the optimal timing of surgical intervention (inpatient/urgent versus outpatient/elective) [1,2]. Specific to gallstones, accurate imaging determines whether preoperative or intraoperative removal of associated stones in the common bile duct is indicated. We present a case of acute, severe cholecystitis presenting with equivocal and inconclusive clinical, laboratory, and ultrasound findings. Magnetic resonance cholangiopancreatography allowed accurate identification of cholelithiasis and demonstrated a massive gallbladder mucocele requiring urgent laparoscopic cholecystectomy.

## 2. Case presentation

In this case report, all information was reported in line with the SCARE criteria [3].

A 39-year-old Caucasian female presented with mild right upper quadrant pain of four days duration coupled with intermittent epigastric discomfort after meals. There was no associated nausea, vomiting, fever or jaundice. Blood tests showed mildly elevated liver enzymes (alkaline phosphatase 40 g/L, alanine aminotransferase 24 international units/L, aspartate aminotransferase 19 international units/L, gamma-glutamyl transpeptidase 51 international units/L, bilirubin total 5 micromol/L), and C-reactive protein (15 mg/L), with a normal white cell count. A diagnostic abdominal ultrasound could not reliably detect cystic or common bile duct stones due to patient obesity and meteorism. Computed tomography was considered however the patient had a severe allergy to iodine contrast. Magnetic resonance cholangiopancreatography was subsequently performed, which accurately identified cholelithiasis, and an acutely inflamed, grossly distended gallbladder mucocele with a stone in the cystic duct (Fig. 1), indicative of Grade 2 cholecystitis [4,5]. There were large stones obstruct-

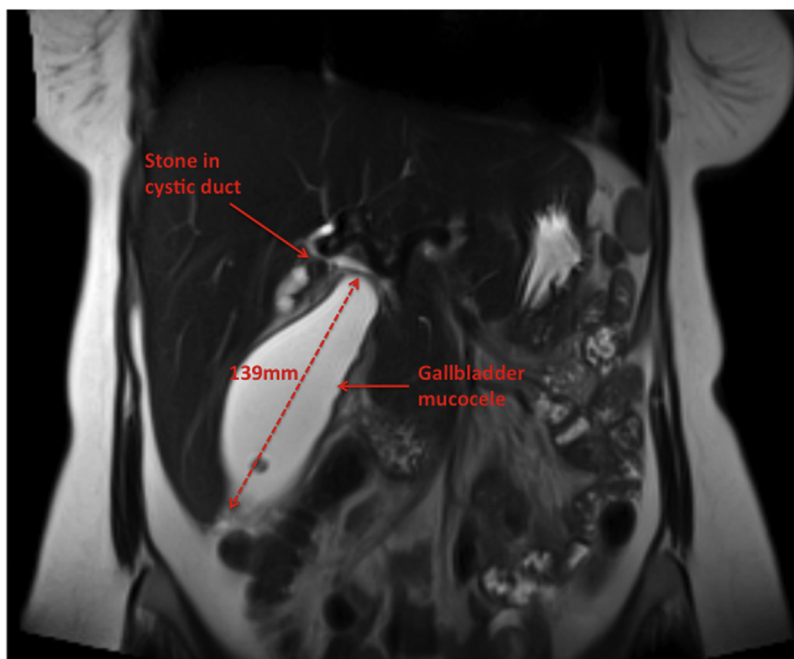
\* Corresponding author.

E-mail addresses: [queenie.reyes@nh.org.au](mailto:queenie.reyes@nh.org.au)

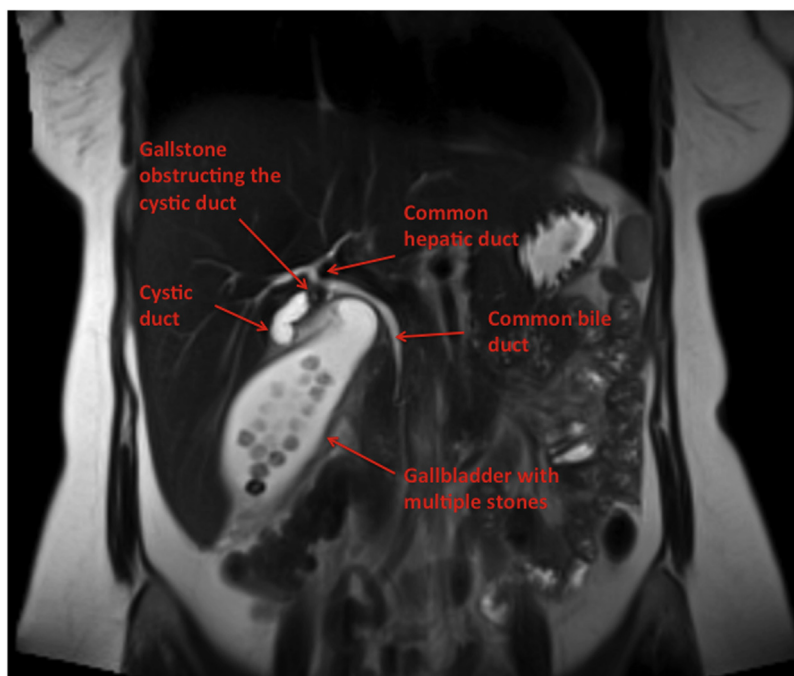(Q. Reyes), [r1mcl4@student.monash.edu](mailto:r1mcl4@student.monash.edu) (R.L. McLeod), [klfer4@student.monash.edu](mailto:klfer4@student.monash.edu) (K. Fernandes), [vijayragavan.Muralidharan@austin.org.au](mailto:vijayragavan.Muralidharan@austin.org.au) (V. Muralidharan), [laurence.weinberg@austin.org.au](mailto:laurence.weinberg@austin.org.au) (L. Weinberg).

<http://dx.doi.org/10.1016/j.ijscr.2017.04.031>

2210-2612/© 2017 The Author(s). Published by Elsevier Ltd on behalf of IJS Publishing Group Ltd. This is an open access article under the CC BY-NC-ND license (<http://creativecommons.org/licenses/by-nc-nd/4.0/>).



**Fig. 1.** Magnetic resonance cholangiopancreatography demonstrating the grossly distended gallbladder mucocoele spanning over 139 mm.



**Fig. 2.** Magnetic resonance cholangiopancreatography demonstrating a gallstone in the cystic duct just distal to its junction with the common hepatic duct and cholelithiasis. At least 15 large stones are visible in the gallbladder, and two more stones in the cystic duct, each measuring around 6.9 mm.

ing the cystic duct with at least 15 other sizeable stones within the gallbladder itself (Fig. 2). An urgent laparoscopic cholecystectomy confirmed a grossly distended gallbladder and follow up histopathology showed a suppurative gallbladder mucocoele with acute-on-chronic cholecystitis secondary to cholelithiasis.

### 3. Discussion

Ultrasound continues to be the preferred imaging examination for diagnosis of biliary disorders [6]. Some ultrasonographic find-

ings are more strongly associated with acute cholecystitis than others, such as a positive Murphy's sign is reported to have a sensitivity as high as 88% [6]. The visualisation of increased gall bladder wall thickness >3.5 mm has been found to be a reliable and independent predictor of acute cholecystitis [6]. Ultrasound can be limited by sonographer experience, obesity and meteorism [1,6]. Computed tomography can be used in the setting of a complex patient presentation or diagnostic dilemma [6]. Further benefit of computed tomography can be identification of other possible diagnoses and complications of acute cholecystitis [6]. Though the widespread availability of conventional magnetic resonance imag-

ing and magnetic resonance cholangiopancreatography has limited its diagnostic use for biliary disorders, it is reported to be equivalent and in some cases superior when compared to ultrasonography [6].

Computed tomography however involves exposure to ionizing radiation, and in our case, intravenous contrast was contraindicated due to severe contrast allergy. Magnetic resonance imaging offers the advantages of improved stone conspicuity and absence of ionizing radiation compared to computed tomography [7]. In this case, magnetic resonance cholangiopancreatography facilitated precise identification of the biliary tree anatomy, localised the site of gallstone obstruction, and excluded biliary anatomic variations, thereby minimizing intraoperative iatrogenic bile duct injury. Magnetic resonance cholangiopancreatography allowed timely surgical intervention, thus avoiding treatment delay, which can lead to gallbladder empyema and mural necrosis.

#### 4. Conclusion

Although ultrasonography continues to be the first line modality to investigate biliary disorders, it failed to identify any cystic or common bile duct stones in our patient due to obesity and meteorism. Computed tomography would be the next line imaging modality, particularly within patients who are a diagnostic dilemma or have a complex presentation. However, intravenous contrast limited its use within our case secondary to severe contrast allergy. The exposure of radiation associated with computed tomography would have also limited its use in our case, given our patient was a young female. The subsequent utilisation of magnetic resonance cholangiopancreatography facilitated accurate identification of acute biliary abnormalities, as demonstrated by our case, in the setting of an otherwise vague, clinical presentation of biliary symptoms. As magnetic resonance cholangiopancreatography is becoming more accessible, it should be considered as the imaging modality of choice to assess specific patient groups presenting with atypical biliary symptoms, and where ultrasound has been inconclusive.

#### Conflict of interests

The authors declare that they have no competing interests.

#### Declarations

A copy of the signed consent, report and accompanying images has been provided to the Austin Health Research Ethics Committee. The Ethics Review Committee has waived the need for Ethics approval.

#### Availability of data and materials

The original radiology images are available for review.

#### Funding

The Department of Anaesthesia Research Fund, Austin Hospital has provided funding for the submission of this case report.

#### Ethical approval

A copy of the signed consent, report and accompanying images has been provided to the Austin Health Research Ethics Committee. The Ethics Review Committee has waived the need for Ethics approval.

#### Consent

Written informed consent was obtained from the patient for publication of this case report and accompanying images. A copy of the written consent is available for review by the Editor-in-Chief of this journal.

#### Authors' contributions

RML and KF collated the information regarding the case. LW was the principle anaesthetist and VM was the principle surgeon involved in the management of the patient. RML and KF completed the literature. QR, LW, VM, RML, and KF contributed to writing the manuscript. All authors read and approved the final manuscript.

#### Guarantor

Dr. Queennie Reyes, Dr. Ruth Louise McLeod, Dr. Katrina Fernandes, A/Prof Vijayaragavan Muralidharan, A/Prof Laurence Weinberg.

#### Acknowledgment

Not applicable.

#### References

- [1] M. Tonolini, A. Ravelli, C. Villa, R. Bianco, Urgent MRI with MR cholangiopancreatography (MRCP) of acute cholecystitis and related complications: diagnostic role and spectrum of imaging findings, *Emerg. Radiol.* 19 (2012) 341–348.
- [2] Y. Watanabe, M. Nagayama, A. Okumara, Y. Amoh, MR imaging of acute biliary disorders, *Radiographics* 27 (2007) 477–495.
- [3] R.A. Agha, A.J. Fowler, A. Saetta, I. Barai, S. Rajmohan, D.P. Orgill, SCARE group, The SCARE statement: consensus-based surgical case report guidelines, *Int. J. Surg.* (2016) 180–186.
- [4] M. Yokoe, T. Takada, S.M. Strasberg, J.S. Solomkin, T. Mayumi, H. Gomi, H.A. Pitt, O.J. Garden, S. Kiriya, J. Hata, T. Gabata, M. Yoshida, F. Miura, K. Okamoto, T. Tsuyuguchi, T. Itoi, Y. Yamashita, C. Dervenis, A.C. Chan, W.Y. Lau, A.N. Supe, G. Belli, S.C. Hilvano, K.H. Liao, M.H. Kim, S.W. Kim, C.G. Ker, Tokyo Guidelines Revision Committee. TG13 diagnostic criteria and severity grading of acute cholecystitis (with videos), *J. Hepatobiliary Pancreat. Sci.* 20 (2013) 35–46.
- [5] Y. Yamashita, T. Takada, S.M. Strasberg, H.A. Pitt, D.J. Gouma, O.J. Garden, M.W. Büchler, H. Gomi, C. Dervenis, J.A. Windsor, S.W. Kim, E. de Santibanes, R. Padbury, X.P. Chen, A.C. Chan, S.T. Fan, P. Jagannath, T. Mayumi, M. Yoshida, F. Miura, T. Tsuyuguchi, T. Itoi, A.N. Supe, Tokyo Guideline Revision Committee. TG13 surgical management of acute cholecystitis, *J. Hepatobiliary Pancreat. Sci.* 20 (2013) 89–96.
- [6] A. Pinto, A. Reginelli, L. Cagini, F. Coppolino, A.M.S. Ianora, R. Bracale, M. Giganti, L. Romano, Accuracy of ultrasonography in the diagnosis of acute calculous cholecystitis: review of the literature, *Crit. Ultrasound J.* 5 (2013) S11, <http://dx.doi.org/10.1186/2036-7902-5-S1-S11>.
- [7] B.M. Yeh, P.S. Liu, J.A. Soto, C.A. Corvera, H.K. Hussain, MR imaging and CT of the biliary tract, *Radiographics* 29 (2009) 1669–1688.

#### Open Access

This article is published Open Access at [scimedirect.com](http://scimedirect.com). It is distributed under the [IJSCR Supplemental terms and conditions](#), which permits unrestricted non commercial use, distribution, and reproduction in any medium, provided the original authors and source are credited.