



Case Report

Supine percutaneous nephrolithotomy in horseshoe kidney



Nadeem Sohail, FCPS^{a,*}, Amjad Albodour, HBU^{b,c},
Khalid M. Abdelrahman, CABU^b and Kamran H. Bhatti, MS^b

^a Urology Section, Alkhor Hospital, Hamad Medical Corporation, Doha, Qatar

^b Alkhor Hospital, Hamad Medical Corporation, Doha, Qatar

Received 15 November 2016; revised 6 December 2016; accepted 11 December 2016; Available online 1 February 2017

المخلص

نقدم حالة لمريض عمره ٤٥ عاماً، يشتكي من ألم متكرر في الخصرة اليسرى لمدة ثلاثة أشهر. أظهرت الأشعة المقطعية للبطن والحوض كلية حذوية مع وجود حصتين في الكأس الوسطى والسفلى للكلى اليسرى، قياس كل حصاة تقريبا ١,٥سم. لدى المريض تاريخ مرضي لعدة محاولات غير ناجحة لتفتيت الحصوات بالصدمات خارج الجسم في نفس الجهة. وعولج المريض بنجاح باستخراج حصوات الكلية عن طريق الجلد في وضعية الاستلقاء ونتج عنها إزالة الحصوات بالكامل. نقدم في هذا التقرير طريقة قصيرة وتحتاج إلى إقامة أقصر من المعدل في المستشفى مع عدم وجود مضاعفات أثناء أو بعد العملية.

الكلمات المفتاحية: كلية حذوية؛ استخراج حصوات الكلية عن طريق الجلد؛ حصى الكلى؛ تفتيت الحصوات بالصدمات خارج الجسم؛ ألم الخصرة

Abstract

We report a case of a 45-year-old male who presented with recurrent left loin pain of three months' duration. A CT scan of his abdomen and pelvis showed a horseshoe kidney with two stones in the middle and lower calyx of the left kidney, each stone measuring approximately 1.5 cm in size. The patient had a past history of several unsuccessful attempts of extracorporeal shockwave lithotripsy (ESWL) on the same side. We treated the patient successfully by performing a percutaneous nephrolithotomy (PCNL) in the supine position that resulted in complete stone clearance. In addition, we report a

shorter procedure time and hospital stay with no peri-operative or post-operative complications.

Keywords: ESWL; Horseshoe kidney; Loin pain; Percutaneous nephrolithotomy; Renal stone

© 2017 The Authors.

Production and hosting by Elsevier Ltd on behalf of Taibah University. This is an open access article under the CC BY-NC-ND license (<http://creativecommons.org/licenses/by-nc-nd/4.0/>).

Background

Introduction

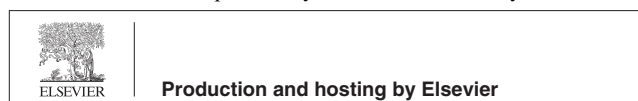
Horseshoe kidney is found to be one of the most common congenital renal abnormalities. It has a prevalence of 1 in 400 persons and a male-to-female ratio of 2:1.¹ As the lower poles of kidneys are fused during embryogenesis, the inferior mesenteric artery interferes with the ascent of the kidney to its normal position. Therefore, the horseshoe kidney remains located in a position more inferior and medial to its normal position. The insertion of the ureters in these kidneys is higher and anterior in the renal pelvis due to an anterior location of the renal collecting system. These factors lead to impaired urinary drainage from collecting system, resulting in increased incidence of a PUJ obstructions, infections (24%) and stone formations (20%), according to studies.^{2,3} PCNL is considered the procedure of choice for treating renal stones in horseshoe kidneys.^{3,4}

Most of the surgeons perform PCNL in the prone position. We routinely perform PCNL in the supine position in our centre.⁵ Therefore, we decided to treat this case also in same position.

* Corresponding address: Urology Section, Alkhor Hospital, Hamad Medical Corporation, P.O. Box 3050, Doha, Qatar.

E-mail: dr.nadeemsohail@gmail.com (N. Sohail)

Peer review under responsibility of Taibah University.



^c Participated in surgical procedure.

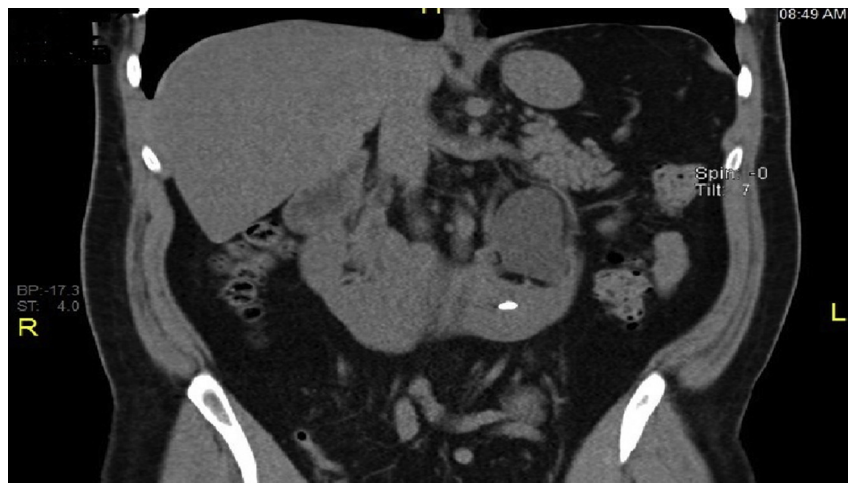

Figure 1: CT KUB, lower calyx stone.

Case presentation

A 45-year-old male presented with recurrent left loin pain of three months' duration. His physical examination was unremarkable, and blood investigations and urinalysis including urine culture were normal. His BMI was 29.2 kg/m². A spiral CT scan of his abdomen and pelvis was performed. It showed a horseshoe kidney with two calculi, one in the middle and the other in the lower calyx of the left kidney, each measuring approximately 1.5 cm in size (Figures 1 and 2). He had undergone several sessions of ESWL on the same side in the past.

Surgical technique

Under general anaesthesia, the patient was placed in our routine modified "complete supine flank free position". After positioning, flexible cystoscopy was performed to insert ureteric catheter to perform a retrograde contrast study. Without changing the position of patient, a puncture of renal collecting system was performed under combined

fluoroscopic and ultrasonic guidance. We selected the upper calyx, as it is usually easy to access in an abnormality located horseshoe kidney (Figure 3). After introducing a guidewire through the puncture needle, the tract was dilated using a balloon dilator. A 30 French Amplantz sheath was followed over it. After gaining the access to the collecting system, a 26 French nephroscope was used. Both stones were located and fragmented with help of an ultrasonic lithoclast. Complete stone clearance was obtained. The flexible scope was used to look for any residual fragments (Figure 4) and it was reconfirmed by performing on-table radiographs. A retrograde JJ stent was inserted under fluoroscopic guidance. A nephrostomy tube for drainage was not used post-operatively. The total operating time was 42 min with a blood loss volume of 100 cc. The patient was discharged on the second post-operative day on oral non-steroidal anti-inflammatory drugs. A follow-up exam was performed in the clinic twice, once on the 5th post-operative day for removal of JJ stent and once after one month for repeat ultrasound exam to look for the presence of any residual fragments. He was completely stone free.

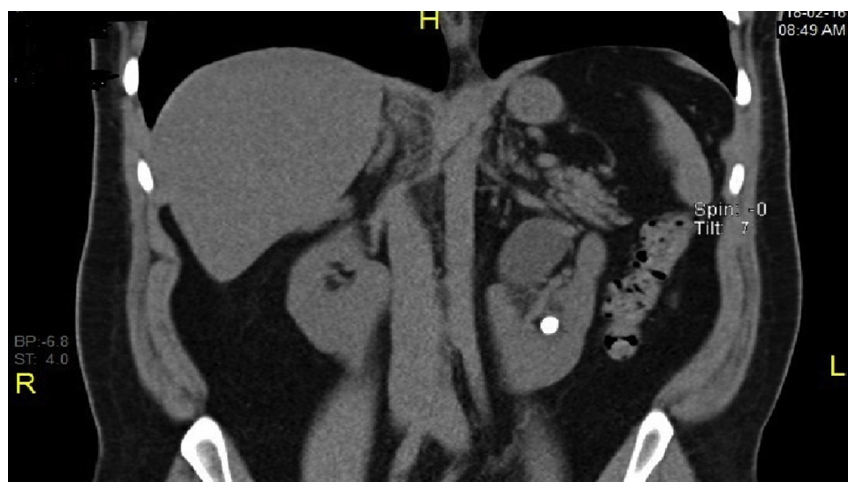

Figure 2: CT KUB, middle calyx stone.

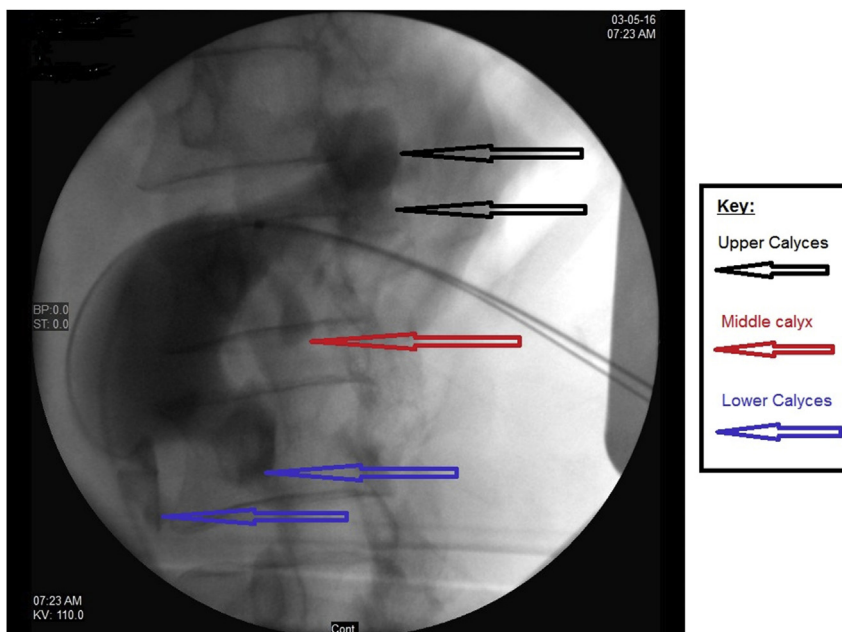


Figure 3: Upper calyx access.

Discussion

Different treatment modalities have been used for treating renal stones in the horseshoe kidney. These include open surgery, extracorporeal shockwave lithotripsy (ESWL), ureteroscopy and laparoscopic/robotic surgery. Several of these modalities have limitations, for instance ESWL has a low stone clearance rate especially in stones larger than 2 cm in size.^{2,10} Laparoscopic or robotic renal stone surgery is an option with an excellent outcome.⁶ However, these procedures need expertise and specialized equipment. Many urologists believe PCNL to be the ideal procedure for treatment of renal stones in the horseshoe kidney. This

procedure results in a higher stone clearance rate and has a lower complication rate.^{7,8} It has been observed that the blood supply of a horseshoe kidney originates from the ventral-medial aspect, whereas the isthmus receives its supply either directly by aorta or by the iliac vessels. Therefore, percutaneous access of the renal collecting system is safe, as it is gained on the opposite side to where the renal blood vessels enter the kidney.⁸

Due to the lower position of the kidneys, upper pole access of the collecting system can be obtained easily through a subcostal approach resulting in a lower risk of pleural injury.⁹ It has also been observed by many authors that upper pole access allows an easy approach to all of the collecting system resulting in complete stone clearance.¹⁰

Although many centres have published literature on performing PCNL for a horseshoe kidney in prone position, very little work has been done on performing it in supine position. Goumas IK and colleagues in 2013 presented a poster at the SIU, UK (Société Internationale d'Urologie, United Kingdom) section meeting regarding supine PCNL in the horseshoe kidney. According to them, this position is safe and is an effective way of treating renal stones in a horseshoe kidney.

We believe supine PCNL is a reasonable alternative to standard prone PCNL. Unlike in prone position, where the patient has to be kept initially in lithotomy for insertion of ureteric catheter, Supine PCNL patients remain in same position throughout the procedure. This helps to reduce the total operating time.⁵ Although our patient had a CT scan of abdomen to observe the adjacent abdominal visceral anatomy, the combination of ultrasound and fluoroscope for the purpose of puncturing the calyx adds further safety and avoids injuring any abdominal viscera including the colon.

Conclusion

Percutaneous nephrolithotomy is considered a safe and effective treatment option in patients with renal stones in a

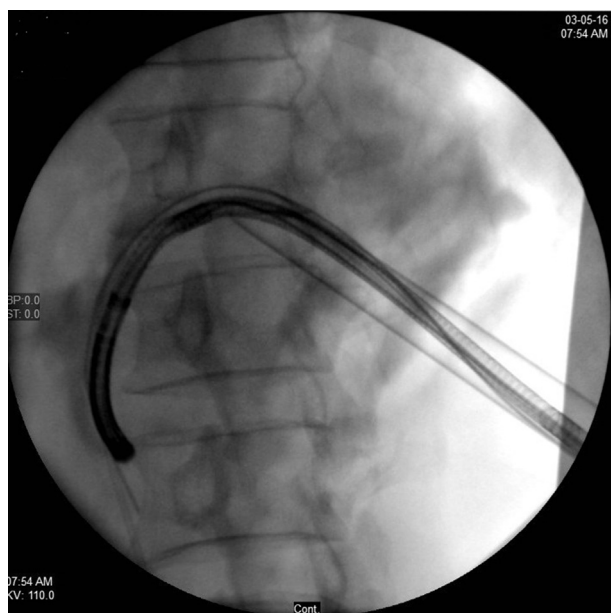


Figure 4: Use of flexible scope.

horseshoe kidney. Supine position is an alternative option for PCNL with similar outcomes to the PCNL in the standard prone position. It provides an additional benefit of performing the procedure in a single position, which is known to reduce total operating time.

Abbreviations: CT, computed tomography; ESWL, extracorporeal shockwave lithotripsy; PCNL, percutaneous nephrolithotomy; PUJ, pelviureteric junction.

Disclosure statements

No competing financial interests exist.

Ethical approval

The ethics committee of Hamad Medical Corporation approved this study.

Guarantor

NS.

Funding

None.

Informed consent

Only patient's data is used in the study. Waiver of consent approved from ethical and research committees of institute obtained.

Authors' contributions

NS researched literature and conceived the study. NS was involved in protocol development, gaining ethical approval, patient recruitment and data analysis. NS wrote the first draft of the manuscript. NS reviewed and edited the manuscript and approved the final version of the manuscript. AA, KA and KH helped in performing surgery and reviewed the manuscript and approved the final version of the manuscript.

Conflict of interests

The authors have no conflict of interest to declare.

Acknowledgements

None.

References

1. Glenn JF. Analysis of 51 patients with horseshoe kidney. *N Engl J Med* **1959**; 261: 684.
2. Evans WP, Resnik MI. Horseshoe kidney and urolithiasis. *J Urol* **1981**; 125: 620–621.
3. Yohannes P, Smith AD. The endourological management of complications associated with horseshoe kidney. *J Urol* **2002**; 168: 5–8.
4. Osther PJ, Razvi H, Liatsikos E, et al. PCNL among patients with renal anomalies: patient characteristics and outcomes; a Subgroup Analysis of the CROES Global PCNL study. *J Endourol* **2011**; 25(10): 1627–1632.
5. Sohail N, Albodour A, AbdelRahman K. Percutaneous nephrolithotomy in complete supine flank-free position in comparison to prone position: a single-centre experience. *Arab J Urol* **2016**. <http://dx.doi.org/10.1016/j.aju.2016.10.001>. In Press.
6. Olucuoglu E, Camtosun A, Bicer S, Bayraktar AM. Laparoscopic pyelolithotomy in a horseshoe kidney. *Turk J Urol* **2014**; 40(4): 240–244.
7. Shokeir AA, El-Nahas AR, Shoma AM, Eraky I, El-Kenawy M, Mokhtar A, El-Kappany H. Percutaneous nephrolithotomy in treatment of large stones within horseshoe kidneys. *Urology* **2004**; 64: 426–429.
8. Tepeler A, Sehgal PD, Akman T, Unsal A, Ozyuvali E, Armagan A, Nakada SY. Factors affecting outcomes of percutaneous nephrolithotomy in horseshoe kidneys. *Urology* **2014**; 84: 1290–1294.
9. Rizvi S, Zaidi Z. Percutaneous nephrolithotomy (PCNL) in horse shoe kidneys. *J Pak Med Assoc* **2007**; 57: 222–224.
10. Raj GV, Auge BK, Weizer AZ, et al. Percutaneous management of calculi within horseshoe kidneys. *J Urol* **2003**; 170: 48–51.

How to cite this article: Sohail N, Albodour A, Abdelrahman KM, Bhatti KH. Supine percutaneous nephrolithotomy in horseshoe kidney. *J Taibah Univ Med Sc* **2017**;12(3):261–264.