



Localization of uncoupling protein 1 (UCP-1) in the sebaceous gland of the dorsal region in the Sunda porcupine (*Hystrix javanica*)

Andhika Yudha PRAWIRA¹⁾, Savitri NOVELINA¹⁾, Wartika Rosa FARIDA²⁾,
Huda Shalahudin DARUSMAN^{1,3)}, Katsuhiko WARITA⁴⁾,
Srihadi AGUNGPRIYONO¹⁾ and Yoshinao Z. HOSAKA^{4)*}

¹⁾Department of Anatomy, Physiology, and Pharmacology, Faculty of Veterinary Medicine, IPB University, Bogor 16680, Indonesia

²⁾Zoology Division, Research Center for Biology, Indonesian Institute of Sciences, Cibinong 16911, Indonesia

³⁾Primate Research Center, IPB University, Bogor 16151, Indonesia

⁴⁾Laboratory of Veterinary Anatomy, Faculty of Agriculture, Tottori University, Tottori 680-8553 Japan

ABSTRACT. Uncoupling protein 1 (UCP-1) was believed to be an exclusive protein found in the brown adipose tissue of small rodents and humans; however, recent studies show that the expression of UCP-1 protein has been found in the sebaceous glands of the mouse tail and human skin. There are a few reports about the presence of UCP-1 in the sebaceous glands of other rodents, such as the Sunda porcupine (*Hystrix javanica*), a wild spiny rodent commonly found in Indonesia with a large sebaceous gland. The aim of this study was to identify the presence of UCP-1 in the sebaceous glands on the skin of the Sunda porcupine. The skin from three regions (thoracodorsal, lumbosacral and apex caudal) of eight adult Sunda porcupines was used to detect UCP-1-immunopositive cells through immunohistochemistry. All three regions were found immunopositive to anti-UCP-1 antibody in the sebaceous gland of quill and hair follicles, and the epidermal layer in quill and hair follicles with various intensities. The result of immunohistochemistry revealed that the thoracodorsal and apex caudal region was the most intense immunoreaction followed by the lumbosacral region. These findings proved that the presence of UCP-1 was also identified in the sebaceous glands of other rodent (*Hystrix javanica*) and regions of the body, which has not been reported previously.

KEY WORDS: quill follicle, sebocyte, suna porcupine, uncoupling protein 1

J. Vet. Med. Sci.

82(12): 1729–1733, 2020

doi: 10.1292/jvms.20-0412

Received: 6 July 2020

Accepted: 1 October 2020

Advanced Epub:

14 October 2020

Uncoupling protein 1 (UCP-1) is one of the proteins found in the mitochondria of brown adipose tissue (BAT). The main role of this protein is thermogenesis from mitochondria in the absence of oxidative phosphorylation [8]. UCP-1 is specifically expressed in the mitochondria of BAT as a major site of thermogenesis in small rodents, maintaining body temperature in new-borns, awaking from hibernation, and recovery from hypothermia during anaesthesia [18].

There are several reports of UCP-1 expression in rodent non-adipose tissue, in brain and thymus, at the protein level and mRNA level, respectively. However, there is still controversy regarding this [2, 3, 10]. The study conducted by Mori *et al.* [14] found mRNA and protein of UCP-1 present in human skin, including sebaceous glands, sweat glands and the epidermal layer—they speculated that the UCP-1 protein was thought to play a role in the thermoregulation of human skin. In addition, Miller *et al.* [12] found that UCP-1 was distributed in the sebaceous glands of mice and played a vital role in serving alternative antioxidants.

The Sunda porcupine (*Hystrix javanica*) (F. Cuvier, 1823) is one of many wild rodents that have similar skin characteristics to quill [15, 21]. Sebaceous glands in the Sunda porcupine skin are relatively large; and only found in the area of quill [16]. The most developed sebaceous glands are found in the dorsal region, a well-developed quill part of the body used as a defence mechanism. Sebaceous glands are also widely distributed on the dorsal side of a Sunda porcupine, but there have been few reports on the distribution of UCP-1.

In this study, we tried to reveal the distribution of UCP-1 proteins in the sebaceous glands of the Sunda porcupine skin and identify the presence of UCP-1 protein in non-adipose tissue in other Rodentia, especially wild rodents.

*Correspondence to: Hosaka, Y. Z.: y-hosa@tottori-u.ac.jp

©2020 The Japanese Society of Veterinary Science



This is an open-access article distributed under the terms of the Creative Commons Attribution Non-Commercial No Derivatives (by-nc-nd) License. (CC-BY-NC-ND 4.0: <https://creativecommons.org/licenses/by-nc-nd/4.0/>)




Fig. 1. Dorsal region of skin samples. Thoracodorsal (TD), lumbosacral (LS) and apex caudal (AC).

MATERIALS AND METHODS

Animals and skin samples

All procedures were performed in accordance with the ethical approval of The Ethical Clearance Subcommittee of Life Science, Indonesian Institute of Sciences No. B-12695/K/KS.02.04/XII/2017. In this study, we used skin samples from eight adults Sunda porcupines aged 2–4 years (3 males and 5 females) weighing 6–8 kg. The Sunda porcupines used in this study were consisted of 6 captive animals in captivity of Indonesian Institute of Science, and 2 wild animals. Since the animals are protected, capture permission of wild animals was obtained from Ministry of Forestry and Environment of Republic of Indonesia (approval No. SK. 386/KSDAE/SET/KSA.2/10/2017). The captive animals continued to be bred after this study. While the other two were euthanized according to the IPB ethical approval No. 92-2018 IPB for other studies. The scapular BAT of 2 weeks old mice was also collected as a form of positive control.

The skin samples were collected via a biopsy procedure from 8 samples of the thoracodorsal (TD), 4 samples of the lumbosacral (LS), and 2 samples of the apex caudal (AC) region (Fig. 1). The animals were sampled by skin biopsy, and the procedures were conducted under anaesthesia and sedation [10% HCl ketamine (ilium Ketamil, Troy Laboratories, Glendinning, NSW, Australia) and 2% xylazine HCl (ilium Xylazil; Troy Laboratories) with a dose of 2.5 mg/kg body weight (BW) and 1 mg/kg BW]. The anaesthesia and sedation were injected intramuscular at the base of the tail of the animals restricted in the cage. The quills in the area of biopsy were removed and plucked before biopsy performed. This step was important in the skin treatment of the Sunda porcupine in order to maximize the immerse of fixative in histological processing and ease the section of the tissue.

Immunohistochemistry

The biopsied skins were fixed in 4% of paraformaldehyde for 7 days at room temperature. The skin proceeded to the standard paraffin histological procedure. The paraffin block was sectioned at 8 μ m of thickness, followed by immunohistochemistry staining. Dewaxed sections were incubated in TritonX 0.1–0.2% for 10 min at room temperature followed by 3% H₂O₂ in methanol for 30 min at –20°C after being washed with phosphate buffered saline (PBS, 0.01M, pH 7.4). The immunostaining procedure was performed with the Nichirei Histofine kit [SAB-PO (Goat) kit (normal serum, secondary antibody, and streptavidin complex), Nichirei Bioscience, Tokyo, Japan]. The sections were incubated in 10% normal goat serum for 15 min at room temperature; before then being incubated with goat anti-UCP-1 polyclonal antibody (#sc:6529, Santa Cruz Biotechnology, Santa Cruz, CA,

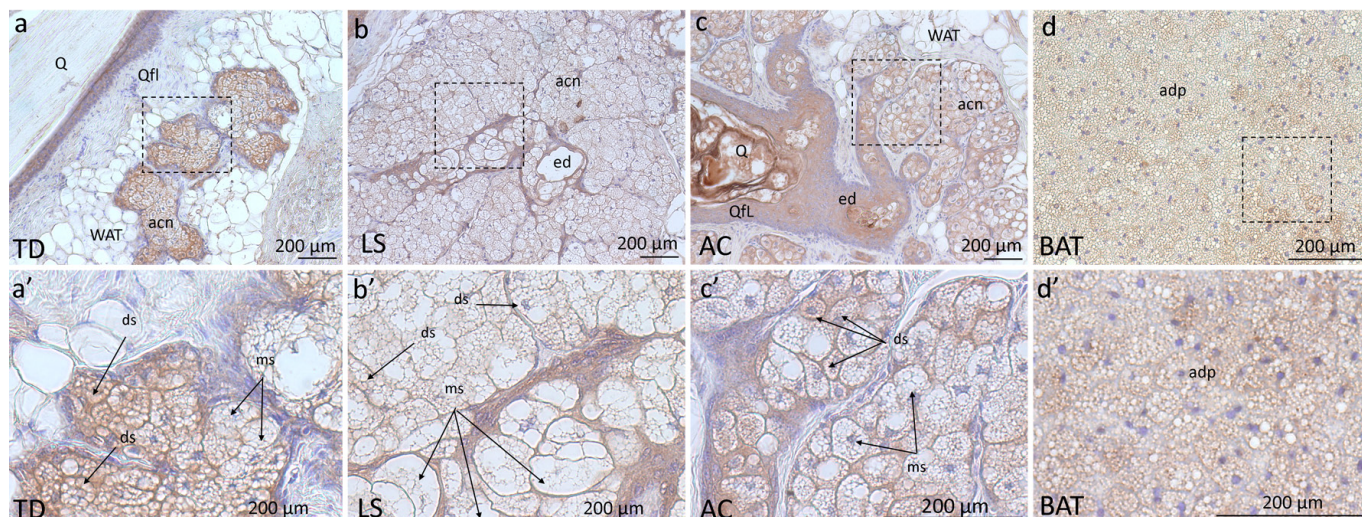


Fig. 2. The presence of uncoupling protein 1 (UCP-1) in the sebaceous gland in several regions of the skin of the Sunda porcupine. Thoracodorsal (TD) (a, a'), lumbosacral (LS) (b, b') and apex caudal (AC) (c, c') regions are compared to scapular brown adipose tissue (BAT) of a mouse (d, d'). Bottom pictures are enlarged views in the enclosed area of upper pictures. acn: acini of the sebaceous gland, adp: adipocyte, ds: developing sebocyte, ed: excretory duct, ms: mature sebocyte, Qfl: quill follicle line, Q: quill, WAT: white adipose tissue.

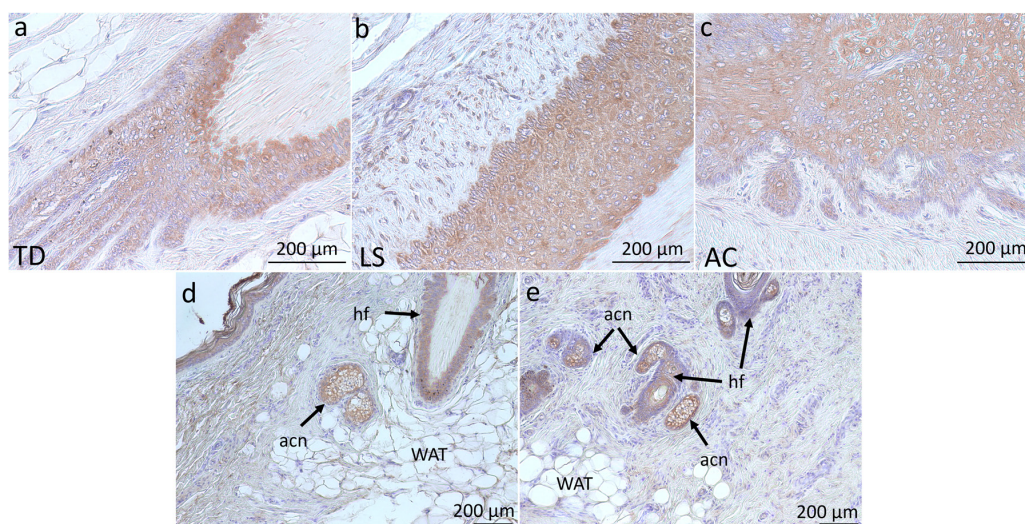


Fig. 3. Immunopositive reaction in the quill follicle line (a, b, c) and the sebaceous gland of a hair follicle (d, e). TD: thoracodorsal, LS: lumbosacral, AC: apex caudal, hf: hair follicle, acn: acini, WAT: white adipose tissue.

USA), in a dilution of 1:100 for 1 hr at room temperature. The sections were then washed with PBS 0.01M pH 7.4 and incubated with anti-goat IgG secondary antibody for 10 min at room temperature. This was followed by a streptavidin complex for 5 min at room temperature. The sections were washed with PBS and then visualized by incubating in 3,3'-diaminobenzidine for 2 min. The sections were counterstained with Mayer's hematoxylin and dehydrated in graded ethanol, clearing in xylene, and mounted with Eukitt® (ORSAtec, Freiburg, Germany). The sections were observed under the light microscopy (IX71, Olympus, Tokyo, Japan). The immunopositive intensity in each region was compared descriptively.

RESULTS

UCP-1 immunopositive reactions were found in all observed regions: TD, LS and AC (Fig. 2). The sebaceous gland and epidermal layer of hair and quill follicles were UCP-1 immunopositive (Figs. 2 and 3). The intensity of the immunopositive reaction in the sebaceous gland of the quill follicle was broader than that of the hair follicle due to the large size of the gland (Figs. 2 and 3). A lot of lobes of acini and the larger size of the sebocyte in the sebaceous gland of the quill follicle contribute to the broader immunopositive reaction in the gland compared to the sebaceous gland in hair follicle even though the intensities

were similar. The UCP-1 distribution and intensities were scattered and varied in acini and the wall of the excretory duct. Strong immunoreaction in the acini of the gland was detected in the TD and AC region, while it was weakest in the LS region (Fig. 2). Additionally, the developing sebocyte (small to medium size with a lot of small lipid vacuoles with medium to large-sized nuclei) in the acini and excretory duct appeared more intense than the mature sebocytes (large size, with a few number of larger vacuoles with small or without nucleus) (Fig. 2). The presence of UCP-1 proteins in the acini of sebaceous glands was identified in the cell membrane and membrane of lipid droplets of sebocyte.

DISCUSSION

The characteristics of Sunda porcupine skin are quills that grow in the form of clusters [16]. The cluster density of the Sunda porcupine skin is much lower than the density of fur in several other rodents, resulting in an area without appendage among quill clusters [11, 16]. Quill follicles develop with a variety of compartments which are more complex than hair follicles: the significant difference being that the glands are larger [16]. Although there are several types of quill in the Sunda porcupine skin, the structure of the sebaceous glands is generally similar in comparison to other regions.

The sebocyte and adipocyte are similar in several different aspects. Both of those cells accumulate lipid but have different functions; the sebocyte act as the holocrine secretion to release the lipid content onto the skin surface, while adipocytes act as the energy storing tissue [19]. Moreover, these cells originated from different sites. The sebocyte was derived from keratinocyte, and adipocyte from the mesenchymal tissue [17].

The findings that UCP-1 protein present in other tissue besides BAT in the Sunda porcupine was correlated with the report of Mori *et al.* [14] and Miller *et al.* [12]. To date, Mori *et al.* [14] have found immunohistochemical localization of UCP1 in the granular layers of the epidermis, sweat glands, hair follicles, and sebaceous glands of various parts of the human body. Miller *et al.* [12] also reported the distribution of UCP1 in sebaceous glands in the mouse tail. The distribution and intensity of the UCP-1 in the Sunda porcupine skin showed that specific regions contributed to the presence of the UCP-1. Each region observed in this study had a specific type of quill, resulting in different intensities of UCP-1 immunoreaction. The skin of the thoracodorsal and apex caudal region of the Sunda porcupine (which showed the strongest intensity) was known to have different types of quill and skin characteristics. Generally, in the Hystriichidae family, including the Sunda porcupine, thoracodorsal have spine-type quills, the apex caudal possessed a more rattle-type, and the lumbosacral possessed the true-type of quill [6, 21, 22]. Moreover, several characteristics of each region showed that the skin color showed that the apex caudal region has the darkest color compared to the other regions while the thickness of thoracodorsal and apex caudal region are thicker than that in lumbosacral [15]. These anatomical features of the skin may contribute to the UCP-1 immunoreaction in the sebaceous gland of the skin. Furthermore, the correlation between skin specific feature and the presence of UCP-1 in the sebaceous gland still unclear.

The role of UCP-1 in the Sunda porcupine skin is still unknown. Although general function of the sebaceous glands are lubrication and skin protection, the presence of UCP-1 protein provides more current information on other roles related to the activity of these proteins at the cellular or molecular levels in the gland. The various intensities of UCP-1 in the acini of the sebaceous gland indicate that sebocytes use UCP-1 in cellular activity, which may also play a role in lipogenesis in addition to acting as an antioxidant. Generally, under certain conditions where brown adipocytes in BAT are less active and only requires a small amount of ATP, the coenzyme Q and UCP-1 will act in an anabolic process, such as Krebs cycle; thus, the BAT would accumulate lipid [1, 4, 5]. Research conducted by Anderson *et al.* [1] found that less active BAT due to lack of coenzyme Q as a regulator of UCP-1 would accumulate lipids and produce paler colour of BAT compared to the common BAT. The process of lipid synthesis in sebocytes is known to require Acetyl CoA and citrate originating from the Krebs cycle [23]. This process may occur to accumulate lipids in the sebocyte. When accumulated, the cells will degenerate and decay on their way to the excretory duct [13, 20]. The fat accumulation is the general mechanism of all holocrine gland including sebaceous gland, and in some points, the cell will begin the apoptotic process through several mechanisms. In sebocytes, the accumulated lipid will lead to the cell degeneration and decay (apoptosis) during their way to the duct. Liman and Alan [9] revealed that apoptotic proteins, both inhibitor or activator protein, were detected in the developing sebocytes, such as survivin (inhibitor) and bax-1, atg7 (activator). The mechanism includes the inactivation of survivin when lipids were accumulated, which lead to the apoptotic process, such as activation of bax-1 and atg7 and other autophagy protein that lead to the cellular degradation. In addition, the DNase 1 and DNase 2 which released from lysosome act to degrade the DNA. This mechanism is a general phenomenon of all holocrine gland in mammals and avian [7]. This phenomenon might be contributed to the different intensities of immunoreaction in developing and mature sebocyte, since developing sebocytes are active cells that accumulated lipid whereas mature sebocytes are degenerate and inactive cells. This allegation needs to be investigated further to prove the role of UCP-1 in the sebaceous glands.

We challenged to prove the presence of UCP-1 and succeeded in identifying it in the sebaceous glands of the Sunda porcupine. The distribution of UCP-1 in the sebaceous gland of the dorsal body and tail indicates it is not only found in brown fat tissue. Due to the restrictions on material availability, this paper was limited to note only in the results morphological analysis. If new materials can be obtained and additional analysis can be performed in the future, we will be able to clarify the characteristics and the significance of UCP-1 in the sebaceous gland in the Sunda porcupine in more detail by conducting analysis of various aspects that could not be achieved this time.

POTENTIAL CONFLICTS OF INTEREST. The authors have nothing to disclose.

ACKNOWLEDGMENTS. We would like to thank Directorate of Human Resource Qualification, the Directorate General of Resources for Science and Technology and Higher Education, Ministry of Research, Technology and Higher Education of the Republic of Indonesia, Enhanced International Publication program (No.1406.2/D3/PG/2018) for the fund of this work. Moreover, we would like to thank Muhammad Risman Wahid, Yuliasuti, Desrayni Hanadhita, and Anisa Rahma for the assistance in this work of publication.

REFERENCES

- Anderson, C. M., Kazantzis, M., Wang, J., Venkatraman, S., Goncalves, R. L. S., Quinlan, C. L., Ng, R., Jastroch, M., Benjamin, D. I., Nie, B., Herber, C., Van, A. A., Park, M. J., Yun, D., Chan, K., Yu, A., Vuong, P., Febbraio, M., Nomura, D. K., Napoli, J. L., Brand, M. D. and Stahl, A. 2015. Dependence of brown adipose tissue function on CD36-mediated coenzyme Q uptake. *Cell Rep.* **10**: 505–515. [Medline] [CrossRef]
- Carroll, A. M., Haines, L. R., Pearson, T. W., Brennan, C., Breen, E. P. and Porter, R. K. 2004. Immunodetection of UCP1 in rat thymocytes. *Biochem. Soc. Trans.* **32**: 1066–1067. [Medline] [CrossRef]
- Carroll, A. M., Haines, L. R., Pearson, T. W., Fallon, P. G., Walsh, C. M., Brennan, C. M., Breen, E. P. and Porter, R. K. 2005. Identification of a functioning mitochondrial uncoupling protein 1 in thymus. *J. Biol. Chem.* **280**: 15534–15543. [Medline] [CrossRef]
- Echtay, K. S., Winkler, E., Frischmuth, K. and Klingenberg, M. 2001. Uncoupling proteins 2 and 3 are highly active H⁽⁺⁾ transporters and highly nucleotide sensitive when activated by coenzyme Q (ubiquinone). *Proc. Natl. Acad. Sci. USA* **98**: 1416–1421. [Medline] [CrossRef]
- Echtay, K. S., Winkler, E. and Klingenberg, M. 2000. Coenzyme Q is an obligatory cofactor for uncoupling protein function. *Nature* **408**: 609–613. [Medline] [CrossRef]
- Findlay, G. H. 1977. Rhythmic pigmentation in porcupine quills. *Z. Säugetierkd.* **42**: 231–239.
- Fischer, H., Fumicz, J., Rossiter, H., Napirei, M., Buchberger, M., Tschachler, E. and Eckhart, L. 2017. Holocrine secretion of sebum is a unique DNase2-dependent mode of programmed cell death. *J. Invest. Dermatol.* **137**: 587–594. [Medline] [CrossRef]
- Jezeq, P. 1999. Fatty acid interaction with mitochondrial uncoupling proteins. *J. Bioenerg. Biomembr.* **31**: 457–466. [Medline] [CrossRef]
- Liman, N. and Alan, E. 2013. The process of apoptosis in a holocrine gland as shown by the avian uropygial gland. *Anat. Rec. (Hoboken)* **296**: 504–520. [Medline] [CrossRef]
- Lengacher, S., Magistretti, P. J. and Pellerin, L. 2004. Quantitative rt-PCR analysis of uncoupling protein isoforms in mouse brain cortex: methodological optimization and comparison of expression with brown adipose tissue and skeletal muscle. *J. Cereb. Blood Flow Metab.* **24**: 780–788. [Medline] [CrossRef]
- Mangelsdorf, S., Vergou, T., Sterry, W., Lademann, J. and Patzelt, A. 2014. Comparative study of hair follicle morphology in eight mammalian species and humans. *Skin Res. Technol.* **20**: 147–154. [Medline] [CrossRef]
- Miller, C. N., Yu, P., Ambati, S., McKinney, E. C., Avra, T., Baile, C. A. and Meagher, R. B. 2016. UCP1 in sebaceous glands corresponds with increased antioxidant potential and not brown adipose tissue function. *Exp. Dermatol.* **25**: 563–565. [Medline] [CrossRef]
- Montagna, W. 1974. An introduction to sebaceous glands. *J. Invest. Dermatol.* **62**: 120–123. [Medline] [CrossRef]
- Mori, S., Yoshizuka, N., Takizawa, M., Takema, Y., Murase, T., Tokimitsu, I. and Saito, M. 2008. Expression of uncoupling proteins in human skin and skin-derived cells. *J. Invest. Dermatol.* **128**: 1894–1900. [Medline] [CrossRef]
- Prawira, A. Y., Hanadhita, D., Rahma, A., Supratikno, Novelina, S. and Agungpriyono, S. 2018. Characteristic of skin morphology of Sunda porcupine (*Hystrix javanica*) with special reference to the connective tissue. *Indo. J. Vet. Sci.* **12**: 23–28.
- Prawira, A. Y., Novelina, S., Darusman, H. S., Farida, W. R. and Agungpriyono, S. 2018. The dorsal skin structure contributes to the surface bacteria populations of Sunda Porcupine (*Hystrix javanica*). *Anat. Histol. Embryol.* **47**: 591–598. [Medline] [CrossRef]
- Schneider, M. R. and Paus, R. 2010. Sebocytes, multifaceted epithelial cells: lipid production and holocrine secretion. *Int. J. Biochem. Cell Biol.* **42**: 181–185. [Medline] [CrossRef]
- Shimizu, Y. and Saito, M. 1991. Activation of brown adipose tissue thermogenesis in recovery from anaesthetic hypothermia in rats. *Am. J. Physiol.* **261**: 301–304.
- Smith, K. R. and Thiboutot, D. M. 2008. Thematic review series: skin lipids. Sebaceous gland lipids: friend or foe? *J. Lipid Res.* **49**: 271–281. [Medline] [CrossRef]
- Thody, A. J. and Shuster, S. 1989. Control and function of sebaceous glands. *Physiol. Rev.* **69**: 383–416. [Medline] [CrossRef]
- van Weers, D. J. 1979. Notes on Southeast Asian porcupines (Hystricidae, Rodentia) IV. On the taxonomy of the subgenus *Acanthion* F. Cuvier, 1823 with note on the other taxa of the family. *Beaufortia* **29**: 215–272.
- van Weers, D. J. 1983. Specific distinction in old world porcupines. *Zool. Gart.* **53**: 226–232.
- Wheatley, V. R. 1974. Cutaneous lipogenesis. Major pathways of carbon flow and possible interrelationships between the epidermis and sebaceous glands. *J. Invest. Dermatol.* **62**: 245–256. [Medline] [CrossRef]