

Single-staged hybrid repair of extent II thoracoabdominal aortic aneurysm with infrarenal abdominal aortic occlusion

Priya B. Patel, MD, MPH, and Virendra I. Patel, MD, MPH, *New York, NY*

ABSTRACT

Thoracoabdominal aortic aneurysm repair has been associated with a high risk of postoperative mortality, spinal cord ischemia, and renal failure. Endovascular repair combined with open repair in a two-staged hybrid approach has had a lower incidence of postoperative morbidity and mortality compared with open repair. In the present report, we have described single-stage hybrid repair of a complex chronic type B aortic dissection with a Crawford extent II thoracoabdominal aortic aneurysm in a patient with extensive prior aortic reconstruction. (*J Vasc Surg Cases Innov Tech* 2022;8:218-21.)

Keywords: Extent II; Hybrid repair; Single-stage; TAAA; Thoracoabdominal

Crawford extent II thoracoabdominal aortic aneurysm (TAAA) repair requires replacement of the full length of the thoracoabdominal aorta. Consequently, these patients have an increased risk of postoperative mortality, spinal cord ischemia, visceral ischemia, and renal failure.^{1,2} The use of staged hybrid repair with thoracic endovascular aortic repair (TEVAR) and subsequent open repair has reduced the overall rate of morbidity and mortality associated with extent II TAAA repairs.³⁻⁵

In the present report, we have described the case of single-stage hybrid extent II TAAA repair in which a staged approach could not be completed owing to the patient's extensive vascular surgical history. The patient provided written informed consent for the report of her case details and imaging studies.

CASE REPORT

A 46-year-old female with chronic type B aortic dissection secondary to cocaine use had presented with severe abdominal and back pain in the setting of uncontrolled hypertension. Her surgical history was significant for aortoiliac reconstruction for lower extremity malperfusion, right axillary–femoral–femoral

bypass for distal aortic occlusion, and aortic valve resuspension with ascending aortic and subtotal arch replacement for delayed retrograde type A dissection.

Computed tomography angiography performed at presentation demonstrated a chronic postdissection TAAA, with the thoracic aorta measuring 6.9 cm and abdominal aorta measuring 7.5 cm (*Fig 1*). All visceral vessels originated from the true lumen. Occlusion was noted proximal to the aortic bifurcation, iliac stents bilaterally, and the right axillofemoral graft. Distal reconstitution of the left iliac system through the left hypogastric artery and reconstitution of the right iliac system through the patent femoral–femoral bypass graft were present.

The operative plan was to perform a hybrid repair in which a TEVAR device would be deployed at the distal end of the previous aortic arch reconstruction, essentially converting an extent II TAAA repair to an extent III repair. The TEVAR device would then serve as an elephant trunk for an open extent III repair. However, the patient's prior aortic arch reconstruction and infrarenal aortic occlusion prevented the typical access for TEVAR and made both the TEVAR and the open TAAA repair mutually exclusive (*Fig 2, A*).

Monitoring of the motor evoked potentials (MEP) and placement of a spinal drain were used for spinal cord protection. The patient was placed in the right lateral decubitus position, and the thoracoabdominal aorta was exposed in the typical manner. Direct aortic puncture was performed proximal to the aortic occlusion. Intravascular ultrasound was used to confirm the placement of two wires within the true lumen. A Zenith tapered graft (Cook Medical Inc, Bloomington, IN) was positioned and deployed at the distal end of the previously placed aortic arch graft, such that 6 cm of overlap was present between both grafts. One of the two wires was left in place and would later be used to complete the left heart bypass (LHB) circuit. In preparation for the LHB, a 12-mm Dacron graft with a 10-mm sidearm was also sewn to the common iliac artery.

LHB was established with cannulation of the left inferior pulmonary vein. The outflow cannula was then attached to a

From the Division of Vascular Surgery and Endovascular Interventions, Columbia University Medical Center, Columbia University College of Physician and Surgeons.

Author conflict of interest: none.

Correspondence: Virendra I. Patel, MD, MPH, Division of Vascular Surgery and Endovascular Interventions, Columbia University Medical Center, Columbia University College of Physician and Surgeons, Herbert Irving Pavilion, 161 Fort Washington Ave, Fifth Floor, Ste 532, New York, NY 10032 (e-mail: vp2385@cumc.columbia.edu).

The editors and reviewers of this article have no relevant financial relationships to disclose per the Journal policy that requires reviewers to decline review of any manuscript for which they may have a conflict of interest.

2468-4287

© 2022 Published by Elsevier Inc. on behalf of Society for Vascular Surgery. This is an open access article under the CC BY-NC-ND license (<http://creativecommons.org/licenses/by-nc-nd/4.0/>).

<https://doi.org/10.1016/j.jvscit.2022.02.007>

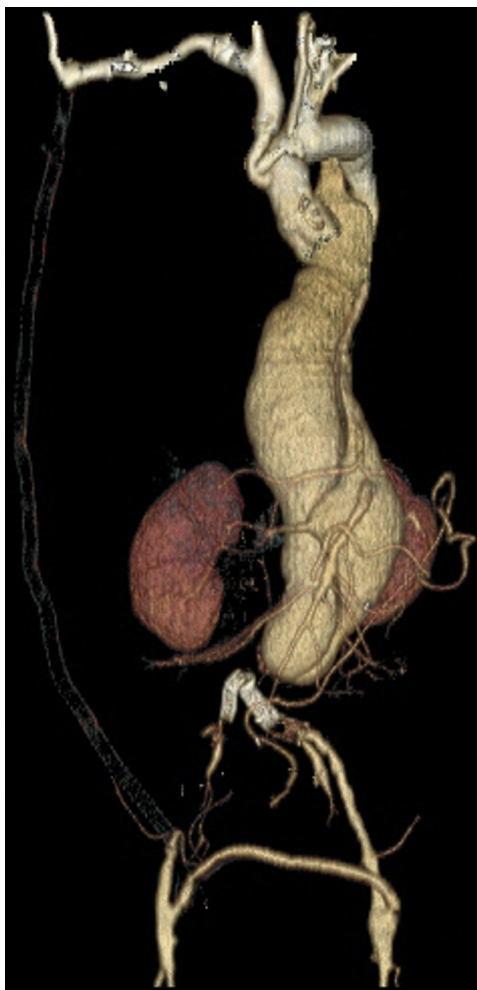

Fig 1. Preoperative computed tomography scan with volume rendered reconstruction of the extent II thoracoabdominal aortic aneurysm (TAAA).

Y-connector, allowing for two arterial perfusion systems. The wire left in place after TEVAR deployment was used to introduce a cannula to perfuse the viscera and kidneys. The second arterial perfusion system was connected to the 10-mm sidearm branch of the common iliac artery graft to perfuse the pelvis and lower extremities.

The distal end of the TEVAR graft was then clamped to allow for proximal anastomosis of a 24-mm Dacron main body graft. To obliterate any dissection channels, the graft was sewn by reapproximating the true and false lumens (Fig 2, B). An 18 × 9-mm bifurcated graft was sewn to the main body graft, which would be used for visceral reconstruction. Next, the celiac artery was ligated at its origin and amputated, and aortic–celiac artery bypass was completed such that the remainder of the viscera was continuously perfused via the LHB circuit. An aortic–superior mesenteric artery bypass was completed in a similar fashion (Fig 2, C). Two 6-mm hybrid vascular grafts (W.L. Gore & Associates, Flagstaff, AZ) were attached to the main body graft for aortic–renal bypass. The left renal artery was ligated and amputated, into which the hybrid vascular graft

was placed. The stent was deployed and secured in place to prevent dislodgement. The right aortic–renal artery bypass was completed in a similar fashion (Fig 2, C). Each visceral and renal anastomosis was completed with <10 minutes of visceral and renal ischemia time, respectively.

The remainder of the aorta was then opened, and multiple bleeding intercostal and lumbar vessels in both the true and false lumens were identified. Because of the stable intraoperative MEP, all intercostal arteries were ligated without reimplantation.

The distal aorta was occluded; therefore, any further distal reconstruction was aborted. The distal end of the main body graft was oversewn. The left iliac bypass graft (12-mm Dacron graft) was anastomosed to the distal aspect of the main body graft, and the 10-mm Dacron sidearm was clamped and oversewn (Fig 2, D). At that point, all MEP were satisfactory, and the LHB circuit was discontinued. The aortic aneurysm sac was closed over the aortic reconstruction.

Postoperatively, the patient required an increase in blood pressure to maintain spinal cord perfusion, which was ultimately

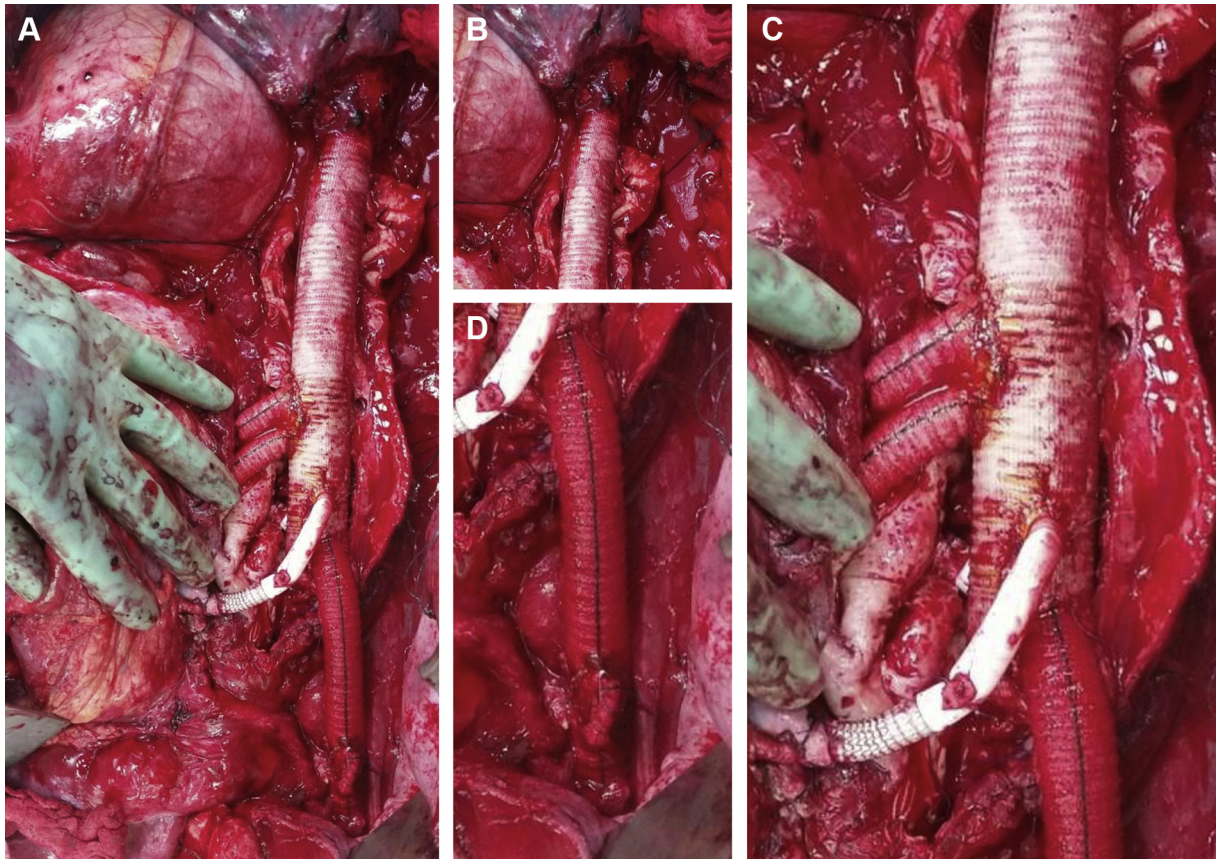


Fig 2. **A**, Intraoperative image of single-staged hybrid repair of extent II thoracoabdominal aortic aneurysm (TAAA). **B**, Intraoperative image showing anastomosis of the distal thoracic endovascular aortic repair (TEVAR) graft and proximal aortic tube graft. **C**, Intraoperative image showing individual bypass of each visceral and renal vessel to the aortic graft. **D**, Intraoperative image showing left iliac artery reconstruction with a 12-mm Dacron graft and an oversewn 10-mm sidearm used for the left heart bypass (LHB) circuit.

weaned to the normal range. She also experienced an increase in creatinine to 1.6 mg/dL, which had normalized before discharge. She maintained the use of all her extremities without paresis or paralysis. At 1 year of follow-up, the patient did not show clinical signs of spinal cord ischemia, visceral ischemia, or renal failure. The 1-year follow-up computed tomography angiogram showed thrombosis of the false lumen and patent aortic–visceral and aortic–renal bypasses (Fig 3).

DISCUSSION

The breadth of aortic involvement in extent II TAAA repair requires extensive preoperative planning and perioperative coordination. Our patient's previous vascular interventions, including an ascending aortic arch reconstruction, aortoiliac reconstruction, and axillary–femoral–femoral bypass further compounded the difficulty of our operative approach. We, therefore, opted to perform a hybrid repair in which a TEVAR procedure would be used to serve as an elephant trunk for standard open extent III repair. However, she experienced infrarenal aortic occlusion, making the TEVAR

and open TAAA repair both mutually necessary, and each procedure needed to be performed sequentially.

The use of TEVAR allows for descending thoracic repair without the need for aortic arch cross-clamping and aortic anastomosis. This was especially important for our patient because of her previous arch reconstruction. Furthermore, given the extent of the TAAA and no safe sequential clamping sites, we decided to reconstruct the visceral vessels with individual bypasses instead of reimplantation onto the main graft. With the use of our LHB circuit, each visceral and renal vessel was individually bypassed, with <10 minutes each of visceral and renal ischemia time.

Throughout the procedure, other forms of previously established multimodal organ protection were also used.⁵⁻⁸ We placed a spinal cord drain at the start of the case for postoperative spinal cord perfusion pressure control. An LHB was established and used to perfuse the pelvis and lower extremities through the patent left femoral system and to perfuse the viscera and kidneys through direct access of the aorta.



Fig 3. One-year follow-up computed tomography scan with volume rendered reconstruction of the extent II thoracoabdominal aortic aneurysm (TAAA) repair.

CONCLUSIONS

The use of a staged repair distributes the cumulative spinal cord ischemia burden and allows time for vascular remodeling and collateralization.³⁻⁵ Although our case could not be performed using a staged repair, our results were comparable, with the expected acute kidney injury and no long-term renal failure, paralysis or paraplegia.

REFERENCES

1. Coselli JS, Bozinovski J, LeMaire SA. Open surgical repair of 2286 thoracoabdominal aortic aneurysms. *Ann Thorac Surg* 2007;83:S862-4.
2. Conrad MF, Crawford RS, Davison JK, Cambria RP. Thoracoabdominal aneurysm repair: a 20-year perspective. *Ann Thorac Surg* 2007;83:856-61.
3. Hawkins RB, Mehaffey JH, Narahari AK, Jain A. Improved outcomes and value in staged hybrid extent II thoracoabdominal aortic aneurysm repair. *J Vasc Surg* 2017;66:1357-63.
4. Etz CD, Zoli S, Mueller CS, Bordin CA, Luozzo GD, Lazala R, et al. Staged repair significantly reduces paraplegia rate after extensive thoracoabdominal aortic aneurysm repair. *J Thorac Cardiovasc Surg* 2010;139:1464-72.
5. Jain A, Flohr TF, Johnston WF, Tracci MC, Cherry KJ, Upchurch GR, et al. Staged hybrid repair of extensive thoracoabdominal aortic aneurysms secondary to chronic aortic dissection. *J Vasc Surg* 2016;63:62-9.
6. See RB, Awosika OO, Cambria RP, Conrad MF, Lancaster RT, Patel VI, et al. Monitoring helps prevent delayed paraplegia after aortic surgery. *Ann Neurol* 2016;79:636-45.
7. Coselli JS, LeMaire SA. Left heart bypass reduces paraplegia rates after thoracoabdominal aortic aneurysm repair. *Ann Thorac Surg* 1999;67:1931-4; discussion: 1953-8.
8. Coselli JS, LeMaire SA, Conklin LD. Morbidity and mortality after extent II thoracoabdominal aortic aneurysm repair 2002;73:1107-15; discussion: 1115-6.

Submitted Nov 13, 2021; accepted Feb 5, 2022.