

Mantle of forensics in child sexual abuse

Preethi Murali,
Manoj Prabhakar

Department of Oral Pathology
and Microbiology, Meenakshi
Academy of Higher Education
and Research, Faculty of
Dentistry, Meenakshi Ammal
Dental College, Chennai,
Tamil Nadu, India

Address for correspondence:

Dr. Preethi Murali,
Department of Oral Pathology,
Meenakshi Ammal Dental
College, Alapakkam,
Maduravoyal, Chennai - 600 095,
Tamil Nadu, India.
E-mail: preethiraj_opath@madc.
edu.in

Introduction

“You may forget your childhood but your childhood does not forget you”

Child Sexual Abuse (CSA) is defined by the WHO as the “involvement of a child in sexual activity that he or she does not fully comprehend, is unable to give informed consent to, as that violates the law as social taboos of society.”

Contacts or interaction between a child and an older or more knowledgeable child or adult when the child is being used as an object of gratification for the older child's or adult's sexual needs. These contacts or interactions are carried out against the child using force, trickery, bribes, threats, or pressure. The perpetrators can be any person including those under the age of 18 years when that person is either significantly older than the victim or is in a position of

Abstract

Child sexual abuse (CSA) is defined as inappropriate adolescent or adult sexual behavior or contact with a child. Sexual abuse may be committed by any person including those under the age of 18 years when that person is either significantly older than the victim or is in a position of power or control over the child. Detecting CSA requires a high incidence of suspicion and familiarity with physical, behavioral, and verbal indications of abuse. Shame and guilt often may have discussion difficult. Studies have shown that approximately 60% of abused children have injuries to head, face, and mouth. Some of the oral and dental features that may be commonly noted in CSA are bruised lips, lacerated mucosa, nonexplainable missing teeth, tongue or frenal injuries, bone fractures in maxillofacial complex, and tooth trauma. It is important to us as dentists to remain vigilant as children depend on adults for protection. Hence, this review will culminate the investigations required by us not only as dentists but also as socially responsible adults.

Key words: Child sexual abuse, reporting, sexually transmitted disease


power or control over the child. Abused children experience negative emotions such as fear, anger, and sadness. The main reason for the need of dentist/doctor is when there is a delay in disclosure of the act.^[1]

Dentistry and child sexual abuse

The common possible reasons for dentists to identify CSA are as follows:

1. About 65% of injuries resulting from child abuse are on the head, neck, or mouth
2. The victims may avoid the same physician, but return to the same dentist as dentistry involves treatments with multiple visits
3. Children are most likely to have a regular preventive care in the same dental clinic.^[2]

CSA can be diagnosed based on history, physical examination, and laboratory findings. A dentist can

Access this article online	
Website: www.jfds.org	Quick Response Code 
DOI: 10.4103/jfo.jfds_17_18	

This is an open access journal, and articles are distributed under the terms of the Creative Commons Attribution-NonCommercial-ShareAlike 4.0 License, which allows others to remix, tweak, and build upon the work non-commercially, as long as appropriate credit is given and the new creations are licensed under the identical terms.

For reprints contact: reprints@medknow.com

How to cite this article: Murali P, Prabhakar M. Mantle of forensics in child sexual abuse. J Forensic Dent Sci 2018;10:71-4.

interpret trauma, collect specimens, and treat injury and also can help and support the vulnerable patient. Injuries often speak for themselves and are usually more eloquent.^[2,3]

Harbingers of child sexual abuse

Mucosal bruising/laceration, tooth trauma (fractures, intrusion, and avulsion of teeth), missing teeth (not explainable by decay or periodontal status), single or multiple apical lesions, or fractured teeth in the absence of decay or unclear history and bone fractures to the maxillofacial complex are important signals which can be identified by dental practitioners.^[3]

Oropharyngeal bruising or laceration which is possibly associated with sexual abuse, or forced feeding or forced insertion of implements, oral signs of sexually transmitted diseases (STD), Oral/intraoral burns caused by hot or caustic foods and fluids. Most often, the victims are found to be ignoring their needs for medical and dental care.^[4]

Some suspected signs which can be found in CSA victims are ecchymosis, abrasion, or laceration in elliptical or ovoid patterns, presence of zones of positive pressure where tongue pressure is exercised and zones of negative pressure where suction has been done. An intercanine linear distance measuring 3.0 cm is suspicious of an adult human bite.^[5]

Use of bite mark as an identification tag

The dentist can photograph the bite mark with an identification tag and a scale marker. The photograph should be taken at a right angle or perpendicular to the bite. Even if saliva cells have dried, they should be collected on a sterile cotton swab moistened with distilled water, dried, and placed in a cardboard specimen tube or envelope.

A control sample should be obtained from an uninvolved area of the child's skin. All samples should be sent to a certified forensic laboratory for prompt analysis.^[2-5]

Sexually transmitted diseases

In children, the isolation of a sexually transmitted organism may be the 1st indication that abuse has occurred provided perinatal and iatrogenic transmission is ruled out.^[4] Gonorrhoea caused by *Neisseria gonorrhoeae* is diagnosed by culture of using selective media such as sugar fermentation, enzyme substances, serological, or DNA hybridization. Syphilis may show papule on the lip area. It is rare to be detectable in childhood. A positive test of *Treponema pallidum* highly suggests a sexual abuse. Chlamydial infections by *Chlamydia trachomatis*, Trichomoniasis by *Trichomonas vaginalis* Bacterial vaginosis by *Gardnerella vaginalis*, herpes by herpes simplex virus 1 and 2 and HIV are few other common STDs in victims.^[6]

Condyloma acuminatum occurs in 10%–90% of sexually abused children. The investigation includes cytology which eventually leads to biopsy in identifying the disease.^[7]

It is known that the detection of semen in the oral cavity is possible for several days after exposure. The chain of custody must be maintained on all samples submitted for forensic analysis.^[5,7]

Reporting

As a 1st report, it can be reported to the Police using Helpline number "100." Further, if there is no response, a direct application can be written to "The Superintendent of police under section 154(3) of code of criminal procedure (CrPC)". Still, if there is no response, it can be directly reported to the Magistrate under Section 156(3) of CrPC. Online reporting can also be made.^[1]

Psychological aspects

The children who have undergone sexual abuse, reveal "Posttraumatic stress disorder." This is a clinical symptom which has three phases:

- Re-enactment of traumatic event
- Avoidance of cues associated with the event
- Physiological hyperactivity.

Another short-term negative effect is the development of sexually reactive behavior. Suicidal gestures, fear of any person or place, sleep disorders, depression, and anxiety may be present. The impact of the above may be minimal during exposure, and the behavior of sadness and anger emerge when the particular child acquires the needed perspective. Therefore, psychiatric diseases usually appear during the victim's adult life.^[8]

There is a need of forensic interviewing for various purposes, the most important being extracting credible information as well to protect the child from the risk of possible revictimization. It is essential for a counseling psychologist, who is trained in counseling skills exclusively for CSA victims. They should be able to encourage narrative events, possess body language such as prompting and nodding, encourage verbally, and use open-ended and also avoid closed-ended and leading questions. Counseling must be primarily supportive and not therapeutic.^[9-11]

The psychiatrist believes that the degree of trauma suffered by the child depends to a greater extent on the way in which the victim will be treated by his family and the Criminal Justice System following disclosure of the incident, than on the incident itself.^[12]

The Indian scenario

In India, according to a report prepared by Dr. Loveleen Kacker, IAS, published Ministry of Women and Child Development,

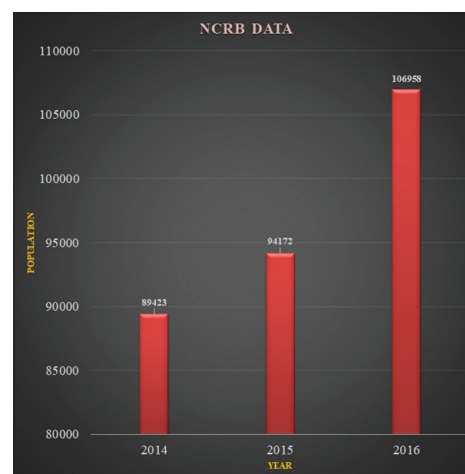
Government of India, the scenario includes 5–12 years of the age group who are most at risk. About 53.22% of children have faced one or more forms of CSA. The states which predominate the highest percentage among boys and girls are Andhra Pradesh, Bihar, Assam, and New Delhi. About 21.90% have experienced severe forms while 50.76% have experienced other forms of sexual abuse. The highest incidence reported has been children with institutional care. Studies also educate us that 50% perpetrators were known to the child or in a position of trust and responsibility. Most of the children did not report the matter to anyone. In the year 2015, about 25% of rapes were committed by their employers and coworkers.^[12] Until 2012, the Indian Penal Code recognized rape, outraging modesty of women, and unnatural acts. Other forms of nonpenetrative sexual assaults, harassment, and exploitation were not explicitly recognized as crimes and therefore not recorded assuming they were reported.^[7,13]

Later, “The Protection of Children from Sexual Offences (POCSO) act” was formulated in 2012. Some of the highlights of POCSO^[14-16] are as follows:

- A child is any person below 18
- Different forms of sexual abuse include harassment and pornography
- Provides trial as child-friendly as possible
- Emergency medical need is provided
- A CSA case must be disposed within a year of reporting
- As per POCSO, mandatory reporting is entrusted, and if failed, 6-month imprisonment or fine is imposed. Sexual offenses and kidnapping account for 81% of the crimes against minors
- The role of media is minimal here. The CrPC prohibits disclosing of the identity of victims.

There has been a steady rise in the increase of offenses against children as per the National Crime Records Bureau. Government figures reveal a child is sexually abused every 15 min. According to a report on crimes of India for 2016, the number of crimes against children was 106,958, out of which 36,022 cases were recorded under POCSO [Graph 1]. India is home to largest sexually abused children in the world, but there is reluctance to talk about the topic so that real numbers of cases could be much higher.^[17]

The National Commission for the protection of child rights has been given the task of monitoring implementation of the protection of children from sexual resources and staffs are required for this. There is effort by the human rights on the Indian Government to adopt and enforce policies that will rectify as well as prevent sexual violence against children. India is a party to international human rights treaties, like the International Covenant on civil and political rights and the convention on the rights of the child.^[18]



Graph 1: National Crime Records Bureau data

Conclusion

The role and responsibility a dental practitioner holds is to create awareness, identify, document, and notify. A definite follow-up consultation is needed.^[15] There can be various educatory programs for dental practitioners organized by the dental association regarding identifying the victim, reporting them, handling the psychological aspect of the child and the child’s family. In view of great hopes that such incidents should not prevail and if it does should not be left unnoticed. The dentist’s incapability would not be a crime, but ignorance would be.

Financial support and sponsorship

Nil.

Conflicts of interest

There are no conflicts of interest.

References

1. Deepa R. Child sexual Abuse: CSA. A parent’s guide to save the smiles by Aware.
2. Hinchliffe J. Forensic odontology, Part 5. Child abuse issues. *Br Dent J* 2011;210:423-8.
3. Costacurta M, Benavoli D, Arcudi G, Docimo R. Oral and dental signs of child abuse and neglect. *Oral Implantol* 2015;8:68-73.
4. Sasmita P. Oral and dental aspects of child abuse. *Dent J* 2006;39:68-71.
5. Guideline on Oral and Dental Aspects of Child Abuse and Neglect. *Clinical practice guidelines. Am Acad Pediatr Dent* 2010;37:172-5.
6. Hammerschlag MR. Sexually Transmitted Diseases and Child Sexual Abuse. *Portable Guides to Investigating Child Abuse*. Available from: <http://www.puborder@ncjrs.org>. [Last accessed on 2018 Feb 27].
7. Percinoto AC, Danelon M, Crivelini MM, Cunha RF, Percinoto C. Condyloma acuminata in the tongue and palate of a sexually abused child: A case report. *BMC Res Notes* 2014;7:467.
8. Sakelliadis EI, Spiliopoulou CA, Papadodima SA. Forensic investigation of child victim with sexual abuse. *Indian Pediatr* 2009;46:144-51.

9. Themeli O, Panagiotaki M. Forensic interviews with children victims of sexual abuse: The role of the counselling psychologist. *Eur J Counsel Psychol* 2014;3:1-19.
10. Gondim RM, Munoz DR, Petri V. Child abuse: Skin markers and differential diagnosis. *Bras Dermatol* 2011;86:527-36.
11. Blain SM, Kittle PE, Kenney JP, Musselman RJ, Needleman HL, Mouden LD. Oral and dental aspects of child abuse and neglect. *Am Acad Pediatr* 1999;104:348-50.
12. Vinutha YJ, Krishnapriya V, Shilpa G, Vasanti D. Forensic dentistry: A pedodontist's perspective. *J Med Radiol Pathol Surg* 2015;1:8-14.
13. Crime in India; 2015. Available from: <http://www.ncrb.gov.in/StatPublications/CII/CII2015/FILES/CrimeInIndia2015.pdf>. [Last accessed on 2018 Feb 25].
14. Varadan SL, Kumar P. Study on Child Abuse. A Report Kacker. India; 2007.
15. Ganguly's Protection of Children from Sexual Offences Act; 2012. (No 32 of 2012 act).
16. Child Sexual Abuse. Guidelines for Medico-Legal Care for Victims of Sexual Violence.
17. Available from: www.bbc.com/news/world-asia-india-42193533. [Last accessed on 2018 Jun 21].
18. Breaking the Silence. Child Sexual abuse-India. A Report by Human Rights Watch Organisation; 2013.