

# Acute Necrotizing Fasciitis Caused by *Rhizopus* Infection in a Patient with Diabetes and Pulmonary Tuberculosis: A Case Report

Xiaoqing Huang<sup>1</sup>, Junke Qiu<sup>1</sup>, Lei Pan<sup>1</sup>, Caihong Wang<sup>1</sup>, Chuanfeng Tang<sup>2</sup>

<sup>1</sup>Tuberculosis Intensive Care Unit, Zhejiang Hospital of Integrated Traditional Chinese and Western Medicine, Hangzhou, Zhejiang, People's Republic of China; <sup>2</sup>Emergency Department, Zhejiang Hospital of Integrated Traditional Chinese and Western Medicine, Hangzhou, Zhejiang, Peoples Republic of China

Correspondence: Chuanfeng Tang, Emergency Department, Zhejiang Hospital of Integrated Traditional Chinese and Western Medicine, No. 208 East Huancheng Road, Hangzhou, Zhejiang, 310000, People's Republic of China, Tel +8615155110013, Email T20237243@163.com

**Background:** Zygomycosis, also termed mucormycosis, is a rare yet highly fatal fungal infection caused by Mucorales species, notably *Rhizopus* spp.

**Case Presentation:** This case study details a 72-year-old man with diabetes, pulmonary tuberculosis, and nephrotic syndrome who developed acute necrotizing fasciitis attributable to *R. oryzae*. Despite initial empirical antibiotic therapy, the infection progressed rapidly. Metagenomic next-generation sequencing (mNGS) facilitated a swift diagnosis, identifying *R. oryzae* in blood and drainage samples. The treatment included amphotericin B and isavuconazole, along with aggressive surgical debridement. The patient exhibited substantial improvement, and he was discharged after stabilization.

**Conclusion:** This case highlights the critical role of early diagnosis through mNGS and the need for a multidisciplinary approach to manage severe mucormycosis in immunocompromised patients.

**Keywords:** *Rhizopus* infection, acute necrotizing fasciitis, diabetes, case report

## Background

Zygomycosis, also known as mucormycosis, is a rare but highly fatal infection caused primarily by organisms from the order Mucorales (class Zygomycetes).<sup>1</sup> Although uncommon, this infection carries a high mortality rate, particularly among immunocompromised individuals or patients with disseminated disease.<sup>2</sup> In recent decades, the incidence of zygomycosis has increased, especially in healthcare settings that treat immunocompromised patients.<sup>3</sup> It is generally considered an opportunistic infection, most commonly affecting patients with poorly controlled diabetes mellitus, solid organ or hematopoietic stem cell transplant recipients, patients with trauma, or those receiving immunosuppressive therapy.<sup>4–6</sup> A retrospective review reported mortality rates for zygomycosis ranging from 44% to 76%.<sup>7</sup>

Zygomycosis, which is caused by species such as *Rhizopus* spp. and *Mucor* spp.,<sup>1</sup> is a serious concern, particularly in immunocompromised individuals. *Rhizopus* is one of the more frequently identified fungal genera in indoor environments, being found in approximately 9% of samples in certain regions.<sup>8</sup> Its presence is particularly alarming because of its strong association with severe infections. Although rare, *Rhizopus* and other fungi from the *Mucoraceae* family can cause necrotizing fasciitis, a condition most commonly linked to bacterial pathogens such as *Group A Streptococcus* and *Staphylococcus aureus*, which are more aggressive in soft tissue infections.<sup>9,10</sup> Zygomycosis typically affects immunocompromised individuals, and it is more common in the sinuses, lungs, or gastrointestinal tract, with its occurrence in necrotizing fasciitis requiring specific risk factors such as uncontrolled diabetes, immunosuppressive therapy, or trauma.<sup>11,12</sup> In this context, we present a case of acute necrotizing fasciitis caused by a *Rhizopus* infection in a patient with diabetes and pulmonary tuberculosis (TB).

## Case Presentation

### Prior to Our Hospital

This case involved a 72-year-old man. On May 24, 2024, while working in a field, he sustained a small knife cut on his left lower leg, resulting in minor bleeding, but the wound was left untreated. This study was approved by the Ethics Committee of the Zhejiang Hospital of Integrated Traditional Chinese and Western Medicine. The written and signed informed consent was obtained from the patient.

On May 27, he experienced a sudden episode of hemoptysis, producing approximately 200 mL of blood, and subsequently sought medical attention at a local hospital. Bronchial artery computed tomography angiography revealed several significant findings as follows: 1) tortuosity and thickening of the right bronchial arteries; 2) patchy opacities in the right middle lung lobe; 3) diffuse miliary, nodular, and patchy lesions in both lungs; and 4) mildly enlarged mediastinal lymph nodes. The imaging findings suggested a diagnosis of pulmonary TB. He underwent emergency bronchial artery embolization, followed by a comprehensive treatment regimen, including hemostatics, expectorants, and antimicrobial therapy with piperacillin–tazobactam. Additionally, insulin was administered for diabetes management, and amlodipine besylate was prescribed to control hypertension. On May 30, both T-SPOT.TB and sputum TB-PCR tests returned positive results, confirming the diagnosis of pulmonary TB. Subsequently, he was prescribed a triple anti-tuberculosis regimen with HRMfx.

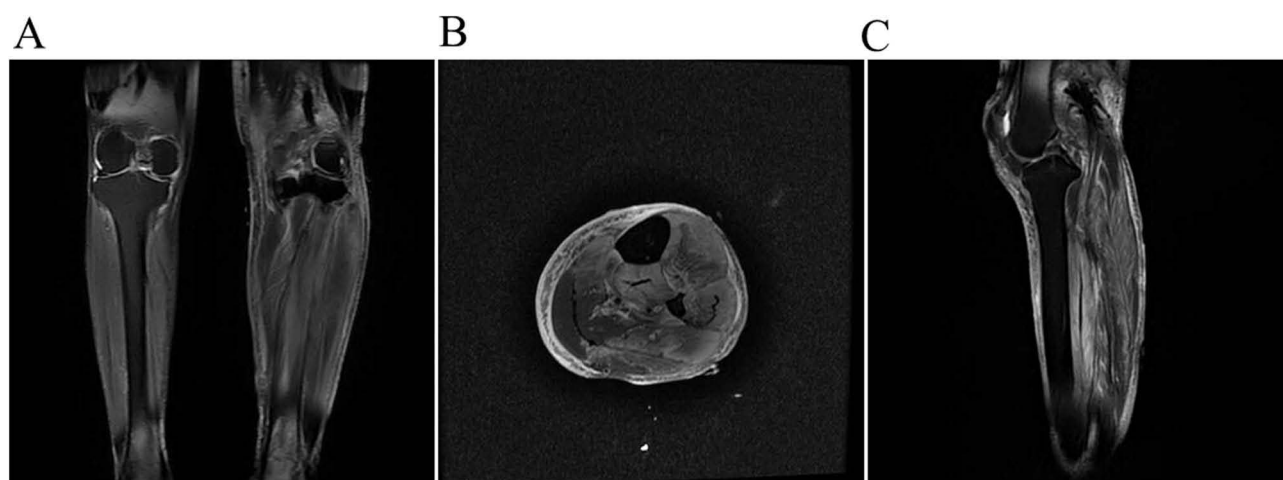
On June 5, he displayed elevated skin temperature, redness, and swelling in the left lower leg. Despite daily debridement and dressing changes, no improvement was noted. By June 8, his erythema and swelling had worsened, and on June 11, he developed a high fever of 39°C. The inflammation had extended to the entire left lower leg, accompanied by ulceration and purulent discharge. He also experienced severe pain. Sulbactam was administered, but it proved ineffective, with symptoms persisting. Laboratory tests revealed a negative blood culture, a normal white blood cell count, an elevated C-reactive protein (CRP) level (107.8 mg/L), and a normal procalcitonin (PCT) level.

### On Admission

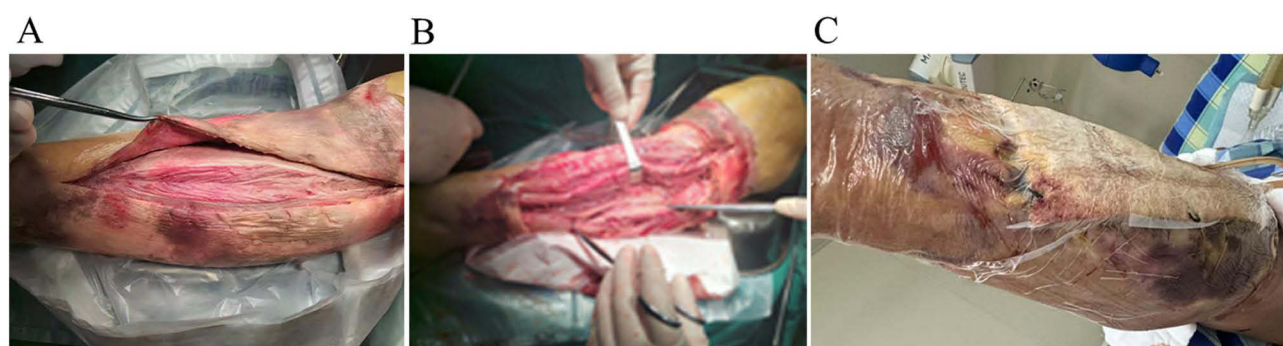
On June 14, he was transferred to our hospital. His medical history included nephrotic syndrome for more than 10 years, with serum creatinine levels ranging 170–200  $\mu\text{mol/L}$  for the past 7 years. He also had type 2 diabetes mellitus for 5 years and hypertension for 4 years with poor glycemic control and suboptimal blood pressure management despite treatment with insulin and oral antihypertensives.

Upon admission, the patient's vital signs were as follows: temperature, 37.3°C; heart rate, 115 bpm; respiratory rate, 21 breaths/min; and blood pressure, 120/85 mmHg. His height and weight were 156 cm and 57.5 kg, respectively. He was alert but appeared fatigued. Cardiopulmonary and abdominal examinations revealed no significant abnormalities. The left lower leg exhibited extensive purple–red discoloration, increased skin temperature, scattered blisters, and some ulceration with exudate. Although there was no purulence, the dorsalis pedis pulse was diminished, and the toes were pale and cool. Pain in the left foot was assessed as 3 on the numeric rating scale.

Abdominal ultrasound revealed no abnormalities in the liver, gallbladder, pancreas, or spleen and no fluid accumulation in the chest or abdomen. Echocardiography demonstrated mild tricuspid and mitral regurgitation with an ejection fraction of 60%. Magnetic resonance imaging of the left lower leg revealed bone marrow edema in the tibial plateau, multiple swollen muscle groups with intermuscular fluid suggesting an infectious process, and effusion in the left knee joint (Figure 1). Doppler ultrasound of both lower limbs identified arterial intima–media complex thickening with plaque formation. The results of laboratory tests were as follows: erythrocyte sedimentation rate, 42 mm/h; white blood cell count,  $24.4 \times 10^9/\text{L}$  (neutrophils 92.5%, lymphocytes 2.5%); hemoglobin, 82 g/L; CRP, 294 mg/L; PCT, 24.37 ng/mL; creatinine, 641  $\mu\text{mol/L}$ ; albumin, 24.4 g/L; glucose, 15.52 mmol/L; total glycated hemoglobin, 9.8%; HbA1c, 8.1%; and B-type natriuretic peptide, 53 pg/mL. The results of blood gas analysis were as follows: pH, 7.204; bicarbonate, 4.6 mmol/L; base excess, –22.4 mmol/L; and lactate, 0.8 mmol/L. The coagulation profile results included a thrombin time of 13.9 s, fibrinogen level of 1163 mg/dL, and D-dimer level of 1707  $\mu\text{g/L}$ . Therefore, on admission, his diagnoses included acute necrotizing fasciitis, pulmonary tuberculosis, type 2 diabetes mellitus, hypertension, nephrotic syndrome, metabolic acidosis, renal anemia, and hypoalbuminemia.



**Figure 1** Fat-saturated T2-weighted magnetic resonance images. (A) Coronal view, (B) axial view, and (C) sagittal view.



**Figure 2** Intraoperative findings. (A) Extensive necrosis and exudation of the skin in the upper and middle segments of the left lower leg. (B) Post-excision, superficial venous thrombosis and necrotizing fasciitis with extensive muscle necrosis were observed, and they were most pronounced in the anterior tibial compartment. (C) Following thorough debridement, bleeding was controlled, and the wound was covered with a vacuum sealing drainage dressing for continuous drainage.


## Treatment

Under general anesthesia, emergency debridement was performed, and the wound was covered with a vacuum sealing drainage (VSD) dressing for continuous drainage (Figure 2). Intraoperative specimens were collected for bacterial and pathological analyses. Postoperatively, he was transferred to the tuberculosis care unit.

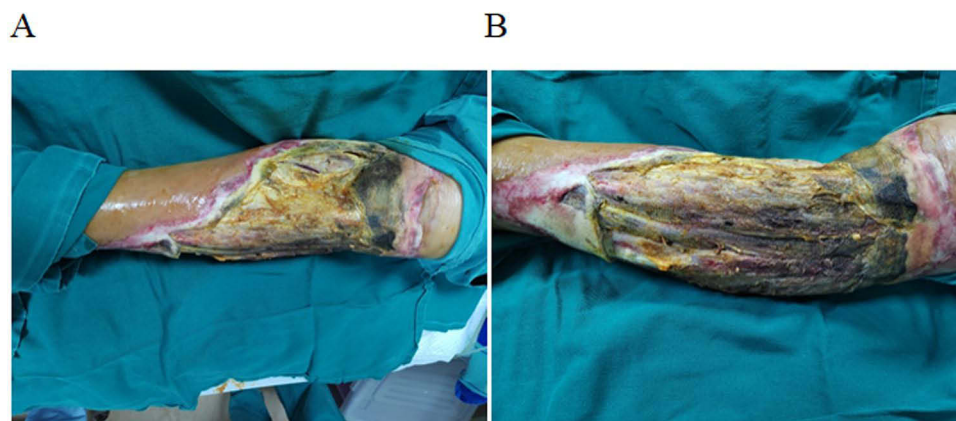
Postoperatively, he experienced hypotension and metabolic acidosis, which were managed with fluid resuscitation, norepinephrine (0.28  $\mu\text{g}/\text{kg}/\text{min}$ ), mechanical ventilation, sodium bicarbonate, heparin, and bedside continuous renal replacement therapy. Additionally, meropenem and sulbactam were administered for infection, isoniazid and levofloxacin were administered for tuberculosis, and insulin was administered for glycemic control. Other treatments included albumin supplementation and enteral nutrition.

On June 17, sputum Xpert testing confirmed the presence of rifampicin-sensitive TB, although repeated mycobacterial sputum cultures were negative. Xpert testing and metagenomic next-generation sequencing (mNGS) of the VSD drainage fluid were negative for TB. However, mNGS detected *R. oryzae* in both the VSD drainage fluid (4737 sequences) and blood (257 sequences). Additionally, *Rhizopus* spp. were isolated from the intraoperative pus culture (+++, Figure 3).

Antifungal therapy was initiated with amphotericin B (50 mg daily) and isavuconazole (200 mg daily, with an initial dose of 200 mg every 8 h for 48 h). On June 19 and 24, he underwent additional debridement and VSD drainage (Figure 4). Despite normal fibrinogen levels, he experienced progressive decreases in hemoglobin levels and platelet counts, although liver and spleen ultrasound and ferritin and triglyceride levels remained normal. Further investigations,



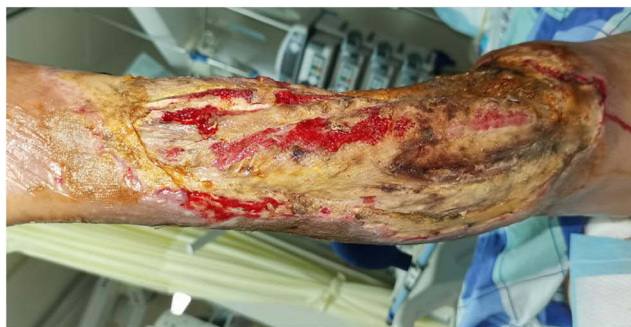**Figure 3** Culture and pathological findings. (A and B) Culture: exudates cultured on Sabouraud dextrose agar and potato dextrose agar at 26–28°C for 3 days, revealing colonies that transitioned from white or gray to gray or brown with a dense, fluffy, cotton-like appearance. (C) Smear: rhizoids (beneath the mycelium), smooth hyphae (few or no septa), upright sporangia with spherical, smooth-walled sporangiospores. (D) Pathological findings: extensive necrosis and abundant fungal hyphae in tissue with positivity on periodic acid-Schiff and periodic acid-methenamine silver staining, indicating *Rhizopus* spp.



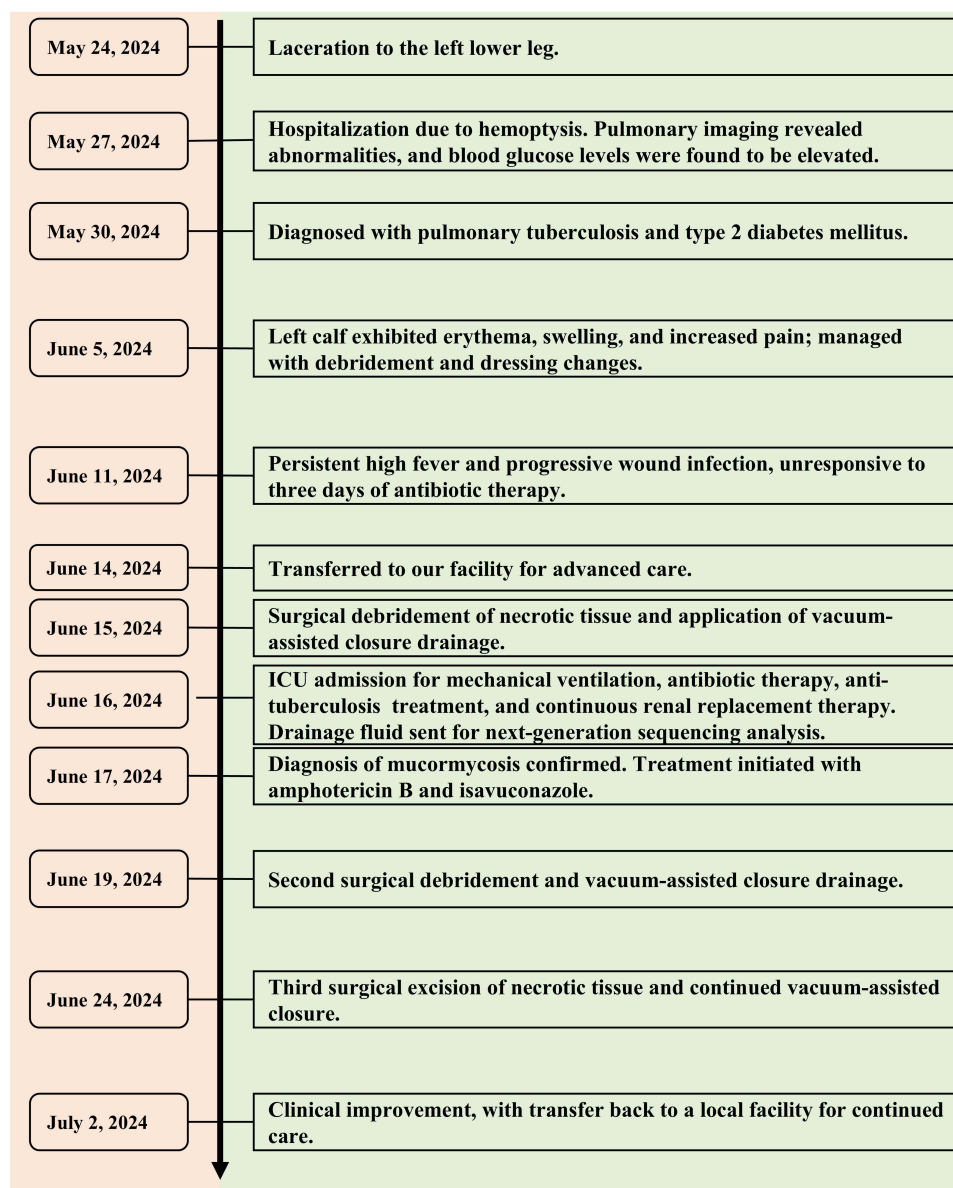
**Figure 4** Observations before debridement and vacuum sealing drainage (June 19 and 24). (A) On June 19, previously intact skin and muscle deteriorated with expanded necrosis and complete loss of the anterior tibial muscles. (B) By June 24, necrosis had progressed to the knee with severe involvement of the anterior tibial muscles.

including NK cells, ADAMTS13, and bone marrow biopsy, were declined by the family. Sulbactam was discontinued because of thrombocytopenia, and received red blood cell and plasma transfusions.

Subsequently, his condition improved. Specifically, his temperature normalized, his redness and swelling subsided, the local wound stabilized, his inflammatory marker levels decreased, and his liver and kidney function improved. His hemoglobin level and platelet count gradually increased, his metabolic acidosis was corrected, and his circulatory status stabilized after discontinuing norepinephrine. Urine output began to increase on July 1. Finally, he was discharged on July 2 because of financial constraints (Figure 5). Figure 6 outlines the timeline of the case presentation and treatment course to aid in understanding the progression.



**Figure 5** Hospital discharge (July 2). Prior to discharge, the vacuum sealing drainage was removed, revealing well-formed granulation tissue and no evidence of further necrotic progression.



**Figure 6** Timeline of the patient's course prior to and during hospitalization.

## Discussion

Necrotizing fasciitis is a severe, rapidly advancing soft tissue infection with a mortality rate exceeding 70% if complicated by septic shock and organ failure.<sup>13,14</sup> It commonly affects patients with diabetes, vascular disease, immunosuppression, and chronic kidney failure.<sup>15</sup> Though rare, mucormycosis (often caused by *Rhizopus* spp) can cause NF, especially in immunocompromised patients, leading to rapid tissue necrosis and severe systemic effects.<sup>16,17</sup>

In this case, a 72-year-old patient with a history of diabetes mellitus, pulmonary TB, nephrotic syndrome, and hypertension developed acute necrotizing fasciitis attributable to *R. oryzae*. This case report is significant for both its rarity and its description of the complexities of managing mucormycosis in a patient with multiple comorbidities, including pulmonary tuberculosis and poorly controlled diabetes mellitus. It emphasizes the critical need for a combined diagnostic approach incorporating imaging, histopathology, and microbiological techniques such as mNGS to ensure accurate and timely identification of the causative pathogen. The rapid progression of necrotizing fasciitis in this patient underscores the importance of an integrated therapeutic strategy combining surgical intervention, antifungal therapy, and supportive care, particularly in immunocompromised individuals. Our findings further reinforce the value of

a multidisciplinary approach in managing such severe and rare fungal infections, for which timely and coordinated interventions can substantially improve patient outcomes.

*Rhizopus* spp. are opportunistic pathogens that predominantly affect immunocompromised individuals, particularly those with uncontrolled diabetes or hematologic malignancies or those receiving immunosuppressive therapy or chemotherapy.<sup>18,19</sup> Our patient, with uncontrolled diabetes, was at high risk for *Rhizopus* infection. Previous cases highlighted the critical role of diabetes in predisposing patients to the rapid and fatal progression of rhino-orbital cerebral mucormycosis.<sup>20</sup> Our case, consistent with other reports, underscores that diabetes mellitus, especially when poorly controlled, is the most common underlying risk factor for mucormycosis.<sup>19,21</sup> These fungi thrive in high-glucose environments because of ketone reductase, and the increased iron uptake often observed in patients with diabetes further promotes fungal growth and infection.<sup>22</sup>

The diagnosis of *Rhizopus* infection typically relies on pathogen detection and histopathological findings, but effective biochemical biomarkers for this infection are lacking. In this case, *R. oryzae* was isolated from drainage, indicating infection, and pathological evidence was also obtained. Given the patient's rapid and severe complications, early diagnosis and treatment were critical for improving his prognosis. mNGS, a rapid, precise, and effective diagnostic tool, using blood and drainage samples confirmed the infection. Unlike traditional methods, mNGS offers unbiased sampling, enabling the simultaneous identification of all potential pathogens without prior target selection. Several studies validated the utility of mNGS in diagnosing *Rhizopus* infections.<sup>20,23,24</sup> Although histological confirmation of non-septate hyphae remains the gold standard, mNGS, which returns results within 24 h, should be the first-line diagnostic tool in suspicious cases. However, it is important to note that the use of mNGS presents diagnostic challenges, particularly in low-income settings, and warrants further discussion. Therefore, although mNGS is highlighted, other diagnostic options should also be considered, especially in resource-limited environments. Additionally, in the context of necrotizing soft tissue infections, the presence of gas in the subcutaneous tissues (subcutaneous emphysema) is commonly observed using imaging modalities such as CT. When integrated with other techniques, these imaging methods offer a comprehensive approach to diagnosing and assessing the extent of the condition.

For patients with mucormycosis, early and aggressive surgical debridement combined with antifungal therapy is crucial for improving survival.<sup>25,26</sup> The optimal strategy involves multiple debridements, continuous VSD, or even amputation to contain the infection, alongside prompt systemic antifungal treatment. Effective management of underlying conditions, such as diabetes or immunosuppression, is also vital for successful outcomes.<sup>27,28</sup> Liposomal amphotericin B is the first-line treatment, with posaconazole and isavuconazole recommended as alternatives. Combination therapy with amphotericin B and either posaconazole or isavuconazole has demonstrated superior efficacy versus monotherapy.<sup>29</sup> Isavuconazole can also serve as salvage therapy when amphotericin B is ineffective or poorly tolerated.<sup>30</sup> Although echinocandins generally lack activity against Mucorales, *Rhizopus* spp. can express target enzymes, indicating potential clinical utility.<sup>31</sup> The efficacy of other treatments, such as iron chelators and hyperbaric oxygen therapy, remains unclear and under investigation.

Nursing care was crucial in managing this complex case, particularly given the patient's immunocompromised status. The nursing team ensured continuous monitoring of vital signs, effective pain management, and meticulous wound care. Regular assessments for infection were essential, alongside strict glycemic control through closely monitored insulin therapy. Postoperative care included diligent management of the VSD system to ensure proper drainage and prevent secondary infection. The nursing team also provided critical education and support to the patient and family regarding wound care and the risks of recurrent infection. Additionally, the study was limited by the lack of follow-up data, which hindered the evaluation of the long-term outcomes of the interventions.

## Conclusions

This case highlights essential aspects of managing mucormycosis in immunocompromised patients, a rare but severe infection. It underscores the importance of early, accurate, and rapid diagnosis using advanced molecular techniques, such as mNGS, especially when traditional methods are time-consuming. However, given the rarity of this infection, it is important to consider other established techniques (such as imaging), particularly in resource-limited settings. Effective management necessitates a multidisciplinary approach that includes surgical intervention, antifungal therapy, and

supportive care. This case illustrates the challenges of treating severe fungal infections in patients with multiple comorbidities and emphasizes the critical need for rapid and coordinated treatment strategies.

## Abbreviations

mNGS, metagenomic next-generation sequencing; TB, tuberculosis; CRP, C-reactive protein; PCT, procalcitonin; VSD, vacuum sealing drainage.

## Data Sharing Statement

The datasets generated and analyzed during the present study are available from the corresponding author on reasonable request.

## Ethics Approval and Consent to Participate

This study was approved by the Ethics Committee of the Zhejiang Hospital of Integrated Traditional Chinese and Western Medicine. All procedures performed in studies involving human participants were in accordance with the ethical standards of the institutional and/or national research committee and with the 1964 Helsinki declaration and its later amendments or comparable ethical standards. The written and signed informed consent was obtained from the patient.

## Consent for Publication

Written informed consent has been provided by the patient to have the case details and any accompanying images published. Institutional approval was not required to publish the case details.

## Funding

This work was supported by Guidance Project of Hangzhou Municipal Health Commission (20220919Y034).

## Disclosure

The authors report no conflicts of interest in this work.

## References

- Maertens J, Demuyck H, Verbeken EK, et al. Mucormycosis in allogeneic bone marrow transplant recipients: report of five cases and review of the role of iron overload in the pathogenesis. *Bone Marrow Transplant*. 1999;24(3):307–312. doi:10.1038/sj.bmt.1701885
- Jestin M, Azoulay E, Pene F, et al. Poor outcome associated with mucormycosis in critically ill hematological patients: results of a multicenter study. *Ann Intensive Care*. 2021;11(1):31. doi:10.1186/s13613-021-00818-4
- Bitar D, Van Cauteren D, Lanternier F, et al. Increasing incidence of zygomycosis (mucormycosis), France, 1997–2006. *Emerg Infect Dis*. 2009;15(9):1395–1401. doi:10.3201/eid1509.090334
- Lelievre L, Garcia-Hermoso D, Abdoul H, et al. Posttraumatic mucormycosis: a nationwide study in France and review of the literature. *Medicine (Baltimore)*. 2014;93(24):395–404. doi:10.1097/MD.0000000000000221
- Bitar D, Lortholary O, Le Strat Y, et al. Population-based analysis of invasive fungal infections, France, 2001–2010. *Emerg Infect Dis*. 2014;20(7):1149–1155. doi:10.3201/eid2007.140087
- Corzo-Leon DE, Chora-Hernandez LD, Rodriguez-Zulueta AP, Walsh TJ. Diabetes mellitus as the major risk factor for mucormycosis in Mexico: epidemiology, diagnosis, and outcomes of reported cases. *Med Mycol*. 2018;56(1):29–43. doi:10.1093/mmy/myx017
- Roden MM, Zaoutis TE, Buchanan WL, et al. Epidemiology and outcome of zygomycosis: a review of 929 reported cases. *Clin Infect Dis*. 2005;41(5):634–653. doi:10.1086/432579
- Khateb A, Mohammed F, Alsubhi F, Abdullah R, Alkatib S. Prevalence of mycoses and investigation of fungal indoor environment. *Majmaah Journal of Health Sciences*. 2023;11(2):105. doi:10.5455/mjhs.2023.02.010
- Lin JN, Chang LL, Lai CH, Lin HH, Chen YH. Group A streptococcal necrotizing fasciitis in the emergency department. *J Emerg Med*. 2013;45(5):781–788. doi:10.1016/j.jemermed.2013.05.046
- Miller LG, Perdreau-Remington F, Rieg G, et al. Necrotizing fasciitis caused by community-associated methicillin-resistant *Staphylococcus aureus* in Los Angeles. *N Engl J Med*. 2005;352(14):1445–1453. doi:10.1056/NEJMoa042683
- Mantadakis E, Samonis G. Clinical presentation of zygomycosis. *Clin Microbiol Infect*. 2009;15 Suppl 5:15–20. doi:10.1111/j.1469-0691.2009.02974.x
- Kontoyiannis DP, Lewis RE. Invasive zygomycosis: update on pathogenesis, clinical manifestations, and management. *Infect Dis Clin North Am*. 2006;20(3):581–607. doi:10.1016/j.idc.2006.06.003
- Iacopi E, Coppelli A, Goretti C, Piaggese A. Necrotizing Fasciitis and The Diabetic Foot. *Int J Low Extrem Wounds*. 2015;14(4):316–327. doi:10.1177/1534734615606534
- Chen LL, Fasolka B, Treacy C. Necrotizing fasciitis: a comprehensive review. *Nursing*. 2020;50(9):34–40. doi:10.1097/01.NURSE.0000694752.85118.62

15. Guilu T, Jing W, Ling J, Guidan R, Tongbin C. Therapeutic effect of medical maggot on diabetic foot ulcer and its influence on Notch1 mRNA expression. *Chin J Postgraduates Med.* 2021;44:1025–1028.
16. Spellberg B, Walsh TJ, Kontoyiannis DP, Edwards, Jr., J, Ibrahim AS. Recent advances in the management of mucormycosis: from bench to bedside. *Clin Infect Dis.* 2009;48(12):1743–1751. doi:10.1086/599105
17. Patel A, Kaur H, Xess I, et al. A multicentre observational study on the epidemiology, risk factors, management and outcomes of mucormycosis in India. *Clin Microbiol Infect.* 2020;26(7):944e949–944e915. doi:10.1016/j.cmi.2019.11.021
18. Cornely OA, Alastruey-Izquierdo A, Arenz D, et al. Global guideline for the diagnosis and management of mucormycosis: an initiative of the European confederation of medical mycology in cooperation with the mycoses study group education and research consortium. *Lancet Infect Dis.* 2019;19(12):e405–e421. doi:10.1016/S1473-3099(19)30312-3
19. Steinbrink JM, Miceli MH. Mucormycosis. *Infect Dis Clin North Am.* 2021;35(2):435–452. doi:10.1016/j.idc.2021.03.009
20. Li J, Ge Y, Xin C, Jiang L. Rhino-orbital-cerebral mucormycosis caused by *Rhizopus arrhizus* diagnosis via metagenomics next-generation sequencing: a case report. *Front Cell Infect Microbiol.* 2024;14:1375058. doi:10.3389/fcimb.2024.1375058
21. Jeong W, Keighley C, Wolfe R, et al. The epidemiology and clinical manifestations of mucormycosis: a systematic review and meta-analysis of case reports. *Clin Microbiol Infect.* 2019;25(1):26–34. doi:10.1016/j.cmi.2018.07.011
22. Karnak D, Avery RK, Gildea TR, Sahoo D, Mehta AC. Endobronchial fungal disease: an under-recognized entity. *Respiration.* 2007;74(1):88–104. doi:10.1159/000094708
23. Chen GJ, Chen XB, Rao WY, Pan XY, Li SY, Su ZQ. Airway necrosis and granulation tissue formation caused by *Rhizopus oryzae* leading to severe upper airway obstruction: a case report. *Front Cell Infect Microbiol.* 2024;14:1366472. doi:10.3389/fcimb.2024.1366472
24. Wang L, Qu Y, Tang L, Li Y, Liu L, Liu Y. Case report: a case of pulmonary mucormycosis caused by *Rhizopus azygosporus* infection complicated by type 2 diabetes mellitus. *Front Med.* 2023;10:1240436. doi:10.3389/fmed.2023.1240436
25. Muthu V, Agarwal R, Patel A, et al. Definition, diagnosis, and management of COVID-19-associated pulmonary mucormycosis: delphi consensus statement from the fungal infection study forum and academy of pulmonary sciences, India. *Lancet Infect Dis.* 2022;22(9):e240–e253. doi:10.1016/S1473-3099(22)00124-4
26. Panigrahi MK, Manju R, Kumar SV, Toi PC. Pulmonary mucormycosis presenting as nonresolving pneumonia in a patient with diabetes mellitus. *Respir Care.* 2014;59(12):e201–205. doi:10.4187/respcare.03205
27. Thakur Rai N, Misra M, Misra S, et al. Insulin and early debridement keys to survival in COVID 19 associated mucormycosis patients (CAM)- An experience from tertiary care hospital in India. *J Diabetes Metab Disord.* 2023;22(2):1459–1469. doi:10.1007/s40200-023-01269-3
28. Luo Z, Zhang L. Diagnosis and treatment of pulmonary mucormycosis: a case report. *Exp Ther Med.* 2017;14(4):3788–3791. doi:10.3892/etm.2017.4986
29. Ibrahim AS, Gebremariam T, Fu Y, Edwards JE Jr, Spellberg B. Combination echinocandin-polyene treatment of murine mucormycosis. *Antimicrob Agents Chemother.* 2008;52(4):1556–1558. doi:10.1128/AAC.01458-07
30. Ervens J, Ghannoum M, Graf B, Schwartz S. Successful isavuconazole salvage therapy in a patient with invasive mucormycosis. *Infection.* 2014;42(2):429–432. doi:10.1007/s15010-013-0552-6
31. Ibrahim AS, Bowman JC, Avanesian V, et al. Caspofungin inhibits *Rhizopus oryzae* 1,3-beta-D-glucan synthase, lowers burden in brain measured by quantitative PCR, and improves survival at a low but not a high dose during murine disseminated zygomycosis. *Antimicrob Agents Chemother.* 2005;49(2):721–727. doi:10.1128/AAC.49.2.721-727.2005

## Infection and Drug Resistance

### Publish your work in this journal

Infection and Drug Resistance is an international, peer-reviewed open-access journal that focuses on the optimal treatment of infection (bacterial, fungal and viral) and the development and institution of preventive strategies to minimize the development and spread of resistance. The journal is specifically concerned with the epidemiology of antibiotic resistance and the mechanisms of resistance development and diffusion in both hospitals and the community. The manuscript management system is completely online and includes a very quick and fair peer-review system, which is all easy to use. Visit <http://www.dovepress.com/testimonials.php> to read real quotes from published authors.

Submit your manuscript here: <https://www.dovepress.com/infection-and-drug-resistance-journal>

**Dovepress**  
Taylor & Francis Group