



Baricitinib as rescue therapy in a patient with COVID-19 with no complete response to sarilumab

A. Cingolani^{1,2} · A. M. Tummolo^{3,8} · G. Montemurro⁴ · E. Gremese^{4,5} · L. Larosa⁶ · M. C. Cipriani³ · G. Pasciuto⁴ · R. Liperoti^{3,5} · R. Murri^{1,2} · T. Pirroni^{6,7} · R. Cauda^{1,2} · M. Fantoni^{1,2} · for COVID 2 Columbus Working Group

Received: 30 May 2020 / Accepted: 28 June 2020 / Published online: 8 July 2020
© Springer-Verlag GmbH Germany, part of Springer Nature 2020

Abstract

A patient with COVID-19-related severe respiratory failure, with insufficient response to an antiretroviral therapy, hydroxychloroquine and Interleukin-6 (IL-6) antagonist therapy, presented a prompt resolution of the respiratory function and improvement in the radiological picture after baricitinib at an oral dose of 4 mg per day for 2 weeks.

Keywords Baricitinib · SARS-CoV-2 · Sarilumab · COVID-19 · Immunotherapy

Introduction

In January 2020, the World Health Organization declared the outbreak of a global health emergency due to coronavirus disease 2019 (COVID-19). It started in Wuhan, China, in December 2019 [1]. Severe acute respiratory syndrome coronavirus 2 (SARS-CoV-2) is a novel coronavirus that is able to infect humans. It binds to angiotensin-converting enzyme 2 (ACE2) receptors that are highly expressed on the cell surface of multiple organs. The main pathogenetic mechanisms

are represented by cytokine storm, characterized by high levels of pro-inflammatory cytokines, and by the coronavirus immune evasion. Higher plasma levels of cytokines IL-6, IL-2, IL-7, IL-10, interferon gamma inducible protein (IP10), monocyte chemoattractant protein (MCP1), macrophage inflammatory protein (MIP1A) and TNF-alpha have been found in COVID-19 patients admitted to intensive care units, and the cytokine storm syndrome was proportional to the severity of disease [2, 3]. Recently, Infectious Diseases Society of America (IDSA) guidelines pointed out the lack of evidence in the efficacy of any pharmacological approach for COVID-19, strongly suggesting the inclusion of patients in clinical trials [4]. Among these drugs, anti-IL6 receptor (id est tocilizumab) [5] has been adopted to treat SARS-CoV-2 severe pneumonia with several trials registered for this mechanism, and other anti-IL-6 drugs such as sarilumab have been used off-label in clinical practice, with preliminary data showing an improvement in the clinical response [6]. Other immune mediators have been recently licensed by the Italian Drug Agency for compassionate use in COVID-19, such as canakinumab and ruxolitinib (www.AIFA.gov); nevertheless, the clinical efficacy as well as the potential sequencing of these drugs has not been reported yet. Among immune mediators, a significant role has been hypothesized by a group of drugs, members of the numb-associated kinase (NAK) family—including AAK1 (AMP-Activating-Kinase) and GAK (Cyclin G Associated Kinase), acting by inhibition of clathrin-mediated endocytosis, which have been hypothesized to be potentially useful in countering SARS-CoV-2 infections [7, 8]. Baricitinib was identified as a NAK

✉ A. M. Tummolo
anita.tummolo@gmail.com

¹ Dipartimento di Scienze di Laboratorio e Infettivologiche, Fondazione Policlinico Gemelli IRCCS, Rome, Italy

² Dipartimento di Sicurezza e Bioetica, Università Cattolica S. Cuore, Milan, Italy

³ Dipartimento di Scienze dell'invecchiamento, Fondazione Policlinico Gemelli IRCCS, Rome, Italy

⁴ Dipartimento di Scienze Mediche e Chirurgiche, Fondazione Policlinico Gemelli IRCCS, Rome, Italy

⁵ Dipartimento di Scienze Geriatriche e Ortopediche, Università Cattolica S. Cuore, Milan, Italy

⁶ Dipartimento di Diagnostica per immagini, Fondazione Policlinico Gemelli IRCCS, Rome, Italy

⁷ Dipartimento di Scienze Radiologiche e Ematologiche, Università Cattolica S. Cuore, Milan, Italy

⁸ Division of Infectious Diseases, Covid 2 Columbus, Fondazione Policlinico Gemelli, IRCCS, Università Cattolica S. Cuore, L.go A. Gemelli 8, 00167 Rome, Italy

(numb-associated kinase) inhibitor, with a particularly high affinity for AAK (adaptor-associated kinase).

To contribute to the correct timing of administration of baricitinib, we report the case of a patient with a respiratory failure linked to COVID-19, with only partial improvement after sarilumab, who had a favorable outcome after 2 weeks of consequent oral treatment with the anti-Janus kinase (JAK1 and JAK2) inhibitor baricitinib.

Case presentation

A 71-year-old male with respiratory failure associated with positive SARS-CoV-2 real-time polymerase chain reaction test had been hospitalized for fever, cough and dyspnea. At the time of admission, symptoms had started 6 days earlier, and chest X-ray showed radiographic signs of COPD (chronic obstructive pulmonary disease) and bilateral mid-basal interstitial involvement compatible with inflammatory–infectious changes. Respiratory rate was 24 per minute and blood gas analysis showed a pO_2/FiO_2 ratio of 209 mmHg in room air. Inflammatory markers at admission showed CRP (C-reactive protein) 106 mg/L, PCT (procalcitonin) under the lower limit of detection, hemoglobin 14.1 g/dL, platelets count $153 \times 10^5/mm^3$, lymphocyte 1270 cells/ mm^3 (18%), LDH (lactate dehydrogenase) 360 U/L (normal upper limit ≤ 250 U/L). A definite pattern of plasma cytokines (IL-6, TNF α , IL-1 β , IL-8, by multi-cytokine test for ELLA-Bio-Techne, Minneapolis) was performed, according to the clinical protocol at baseline, showing high levels of IL-6 (97.4 pg/mL), as well as of TNF α (25.9 pg/mL) and IL-8 (25.9 pg/mL) and dosages were repeated on a 7-day interval, during clinical observation (see Fig. 1). Supportive oxygen implementation with Venturi mask (FiO_2 40%) and oral therapy with lopinavir/ritonavir (800 mg/100 mg a day), hydroxychloroquine (400 mg/day) and azithromycin (500 mg/day) were started. The above combination represented a standard of care of COVID-19 treatment at that time in our hospital. According to a defined clinical–pharmacologic protocol, shared in a multidisciplinary team, excluding other concomitant infections and due to the shortage of tocilizumab intravenously in that period, the patient received a first dose of sarilumab 400 mg intravenously by an off-label use and a second one after 3 days. After 4 days from the first dose of sarilumab, due to an increase of the respiratory rate, to an oxygen saturation drop under 90% not responsive to increase of oxygen supplementation and a PO_2/FiO_2 ratio of 59 mmHg, transfer to intensive care unit (ICU) was required. During ICU admission, patient breathing was supported by high-flow oxygen and no intubation was necessary. Seven days after sarilumab administration, a CT (computed tomography) scan was performed showing multiple areas of increased parenchymal density mainly of the consolidative

type and, in part, of the "ground-glass" type, located in both lungs and with peripheral subpleural distribution. These alterations were more evident in the dorsal regions of the lower lobes. A radiological software was used to calculate the percentage of well aerated parenchyma [87% (emphysema was included)] and of COVID-19 pneumonia (sum of ground-glass opacities and consolidations, 13%) [9]. In addition, CT confirmed the presence of COPD with a severe condition of centrilobular and paraseptal emphysema with a confluent appearance, more evident in the apical segments of the upper lobes and the right lower lobe (Fig. 1a). Due to the stable clinical conditions, not requiring tracheal intubation, the patient was transferred to a sub-intensive care unit.

There, the patient presented with poor general clinical conditions. He was alert and oriented, and not dyspneic in oxygen supportive therapy with nasal cannulae at high flows (FiO_2 60%, flow 40 L/min). In the following days, the patient underwent daily blood gas analysis, with constant detection of hypoxemia (PO_2/FiO_2 ratio of 109 mmHg), so it was not possible to decrease the amount of FiO_2 needed by the patient.

In the suspicion of a pulmonary embolism, a CT scan of the chest with contrast was performed, after 14 days from the sarilumab administration. In this regard, it should be noted that the patient at home was taking oral acenocoumarol every day, as he had been carrying a mechanical aortic valve since 2003. Since hospitalization, this therapy had been suspended and the patient had started therapy with enoxaparin subcutaneously at therapeutic dosage.

Compared to the CT scan performed after sarilumab, it showed a worsening consolidative evolution of the bilateral interstitial lesions previously presented, but absence of luminal filling defects attributable to ongoing thrombotic processes. The percentage of well-aerated parenchyma was 89%, while the amount of COVID-19 pneumonia was 11% (Fig. 1b). At this point, the patient showed cytokine levels similar to the baseline. In particular, IL-6 levels, after the expected increasing following anti-IL6-R administration, was only slightly lower on the 14th day (79.1 pg/mL) with respect to baseline (97.4 pg/mL).

Considering the persistent unchanged oxygen supplementation need, the persistent low PO_2/FiO_2 ratio (121 mmHg at time of CT scan) and the worsening registered at the CT scan, it was therefore decided to start oral baricitinib as a rescue therapy, at a dosage of 4 mg per day for 2 weeks. Written informed consent to the use of an off-label drug was obtained. Blood gas analysis subsequently showed a constant increase in the pO_2 , which allowed to interrupt oxygen therapy with nasal cannulae at high flows and to start oxygen therapy in a Venturi mask. The FiO_2 needed amount progressively decreased, and subsequently oxygen therapy was stopped. After 2 weeks of therapy with baricitinib, the patient was persistently not dyspneic in room air.

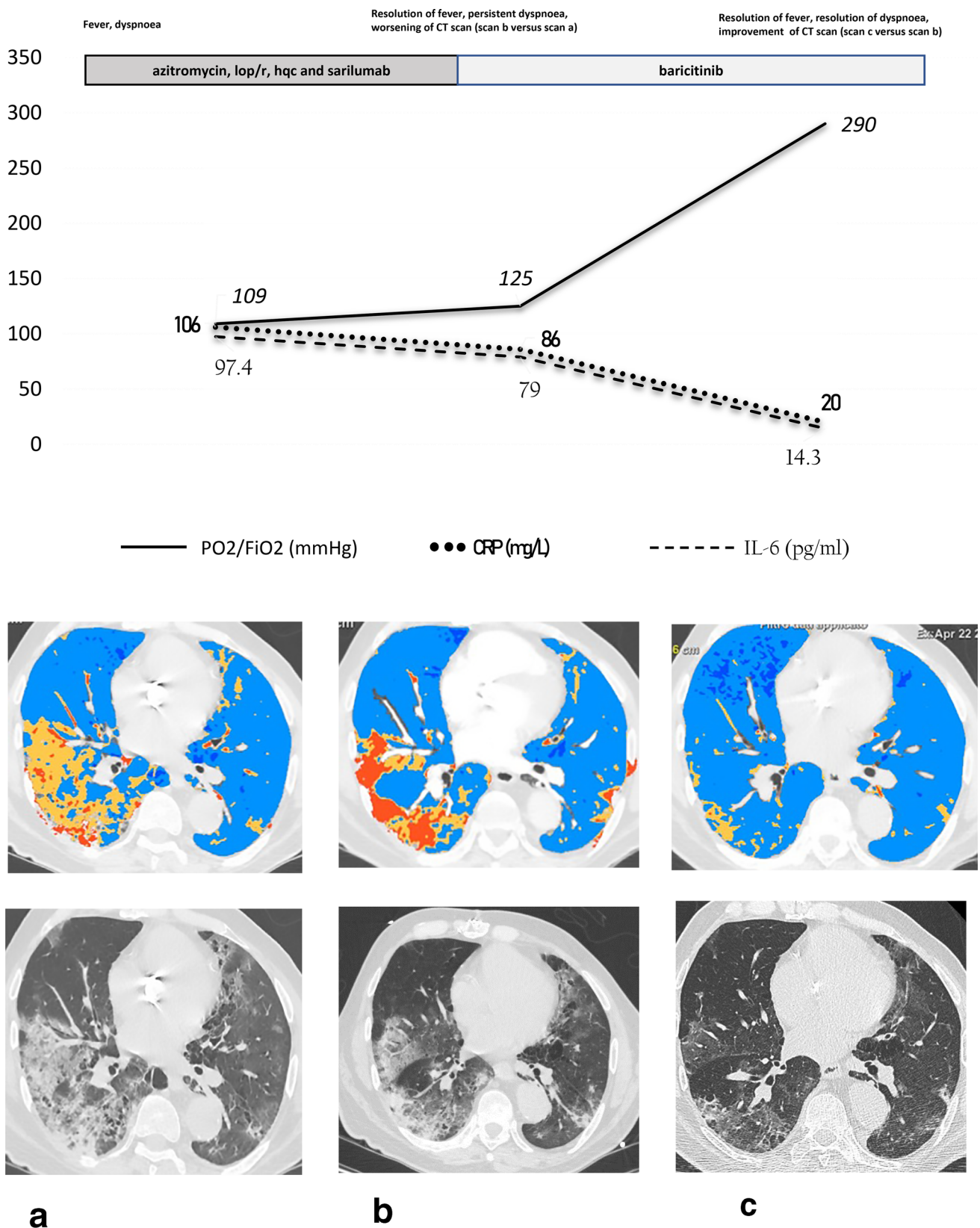


Fig. 1 Disease course, laboratory parameters, and radiologic pictures according to sequential immune treatment. The image shows disease course, laboratory parameters, and radiologic pictures according to sequential immune treatment. CT scan **a** shows the radiological pic-

ture of the first week (after azitromycin, lop/r, hqc and sarilumab); CT scan **b** shows the second week (at baricitinib starting) and CT scan **c** shows the fourth week (after 2 weeks of baricitinib). *HQC* hydroxychloroquine; *Lop/r* lopinavir/ritonavir

A CT scan of the thorax was then repeated. It showed a significant reduction of the multiple areas of increased parenchymal density, partly of the consolidative type, partly of ground glass, previously present in all lung lobes bilaterally and more represented in the lower lobes. At this point, the percentage of well-aerated parenchyma was 95% and the percentage of COVID-19 pneumonia was 5% (Fig. 1c). IL-6 levels were significantly reduced (14.4 pg/mL) compared to the start of treatment with baricitinib.

The patient completed baricitinib therapy without complications. He had no fever or other signs of infection. The blood count performed at the end of therapy did not show neutrophilic leukocytosis. The inflammation indices (CRP) were significantly reduced.

The clinical and radiological evolution during sarilumab and baricitinib treatments according to respiratory, inflammatory and plasma cytokine parameters are reported in Fig. 1.

Finally, the patient was able to join a physical therapy program to overcome the negative effects of deconditioning.

Discussion

The role of baricitinib (a selective JAK1 and JAK2 inhibitor) in the treatment of COVID-19 has been suggested due to its mechanism affecting viral endocytosis, even though its real safety profile still remains to be definitively clarified. Baricitinib is approved for the treatment of moderate to severe cases of rheumatoid arthritis, at a dosage of 4 mg/day, which have not responded to one or more disease modifying anti-rheumatic drugs [10]. Some anecdotal cases have shown a promising efficacy of baricitinib in the treatment of COVID-19 patients [5], and up to 14 clinical trials worldwide are recruiting patients so far, or are near to starting. In particular, the most powerful studies are NCT04401579: Adaptive COVID-19 Treatment Trial 2 (ACTT-II), NCT04373044: baricitinib, Placebo and Antiviral Therapy for the Treatment of Patients With Moderate and Severe COVID-19, NCT04362943: Clinical–epidemiological Characterization of COVID-19 Disease in Hospitalized Older Adults (COVID-AGE). Notwithstanding, since several concerns have been raised regarding the safety of baricitinib [11] and on the correct timing of administration of baricitinib according to the phases of COVID-19 [12], it seems pivotal to understand which patients might benefit from treatment with JAK (janus kinase) inhibitors.

Some authors have raised concerns about a possible facilitating effect of baricitinib on SARS-CoV-2 infection evolution and an increased risk of concomitant infections such as herpes zoster and herpes simplex, due to an impairment of interferon-mediated antiviral response [11].

Data on clinical use of baricitinib in the treatment of COVID-19 patients are very scarce. In a recently published pilot study on 12 COVID-19 patients from Prato and Alessandria, baricitinib treatment was associated with an improvement in clinical characteristics and respiratory function parameters (fever, SpO₂, PaO₂/FiO₂, CRP, and Modified Earling Warinig Score) compared to the control group, and baricitinib was well tolerated with no serious adverse events (AEs), bacterial or opportunistic infections, thrombophlebitis or hematologic toxicity [5]. To our best knowledge, no other clinical experience with baricitinib has been reported so far.

We presented here the case of a 71-year-old male patients with COVID19, who had an incomplete response to local standardized treatment and intravenous IL-6 antagonist drug (sarilumab) who performed a successful rescue therapy with baricitinib. Notably, during baricitinib treatment, neither adverse event nor concomitant infections were observed. Interestingly, in this patient serum IL-6 levels did not significantly change after anti-IL6-R therapy, while they significantly decreased after 2 weeks of baricitinib therapy, according to clinical and radiological response, suggesting that patients with insufficient or partial response to anti-IL-6 may require treatment with a mechanism of action on a wider spectrum of cytokines.

The use of immune-mediating drugs in the treatment of pneumonia by COVID-19 is widely hypothesized [6–8]. Despite preliminary experience of efficacy [13], the latest available guidelines do not recommend such drugs except in clinical trials [4]. One of the most controversial aspects is represented by how to combine immune therapy with other anti COVID-19 drugs; in particular, regarding baricitinib, although JAK inhibition may weaken host inflammatory responses and impair hematopoiesis, combination therapy with direct-acting antivirals, including lopinavir or ritonavir and remdesivir, has been suggested [14]. Combinations of baricitinib with these direct-acting antivirals could reduce viral infectivity, viral replication, and the aberrant host inflammatory response [14]. Furthermore, another aspect that is still largely unknown is the exact positioning of the different drugs based on their potential mechanism of action in relation to the various phases of COVID-19, as well as their potential sequential role [15].

This case represents an efficacious and safe sequential treatment experience in the field of immunotherapy for the treatment of COVID-19. To find out whether baricitinib could represent a safe and efficacious treatment option in COVID-19 not responding to anti-IL-6 inhibitors, larger clinical experiences and clinical trials are warranted.

Acknowledgement COVID 2 Columbus Working Group: A. Bellieni, V. Brandi, A. Calabrese, M. R. Calvello, A. Ciccullo, A. Cingolani, M. C. Cipriani, G. Corbo, C. Falsiroli, M. Fantoni, E. Intini,

G. Landi, P. M. Leone, R. Liperoti, F. Macagno, I. Martis, G. Montemurro, R. Murri, C. Pais, G. Pasciuto, A. Potenza, S. Salini, J. Simonetti, E. Taddei, M. Tosato, A. M. Tummolo, F. Varone, G. Ventura, M. Siciliano.

References

- Zhu H, Wei L, Niu P. The novel Coronavirus outbreak in Wuhan. *China Emerg Microb Infect*. 2020;9:313–9.
- Conti P, Ronconi G, Caraffa A, et al. Induction of pro-inflammatory cytokines (IL-1 and IL6) and lung inflammation by Coronavirus-19 (COVI-19 or SARS-CoV-2): anti-inflammatory strategies. *J Biol Regul Homeost Agents*. 2020;34:1.
- Xu Z, Shi L, Wang Y, et al. Pathological findings of COVID-19 associated with acute respiratory distress syndrome. *Lancet Respir Med*. 2020. [https://doi.org/10.1016/S2213-2600\(20\)30076-X](https://doi.org/10.1016/S2213-2600(20)30076-X).
- Bhimraj A, Morgan RL, Shumaker AH, et al. Infectious diseases society of America Guidelines on the treatment and management of patients with COVID-19. 2020. www.idsociety.org/COVID19guidelines
- Le RQ, Li L, Yuan W, Shord SS, Nie L, Habtemariam BA, Przepiorka D, Farrell AT, Pazdur R. FDA approval summary: tocilizumab for treatment of chimeric antigen receptor T cell-induced severe or life-threatening cytokine release syndrome. *Oncologist*. 2018;23:943–7.
- Cantini F, Niccoli L, Matarrese D, Nicastrì E, Stobbione E, Goletti D. Baricitinib therapy in COVID-19: a pilot study on safety and clinical impact. *J Infect*. 2020. <https://doi.org/10.1016/j.jinf.2020.04.017>.
- Michael B, Emilie S, Rachel ST, Jessica JM, On behalf of the HLH Across Speciality Collaboration, UK. COVID-19: consider cytokine storm syndromes and immunosuppression. *Lancet*. 2020;395:1033–4.
- McGonagle D, Sharif K, O'Regan A, et al. The role of cytokines including interleukin-6 in COVID-19 induced pneumonia and macrophage activation syndrome-like disease. *Autoimmun Rev*. 2020;3:102537. <https://doi.org/10.1016/j.autrev.2020.102537>.
- Toniati P, Piva S, Cattalini M, et al. Tocilizumab for the treatment of severe COVID-19 pneumonia with hyperinflammatory syndrome and acute respiratory failure: A single center study of 100 patients in Brescia, Italy. *Autoimmun Rev*. 2020;3:102568. <https://doi.org/10.1016/j.autrev.2020.102568>.
- European Medicines Agency. Olumiant: summary of product characteristics. 2020. https://www.ema.europa.eu/en/documents/product-information/olumiant-epar-product-information_en.pdf. Accessed 24 Feb 2020.
- Favalli EG, Biggioggero M, Maioli G, Caporali R. Baricitinib for COVID-19: a suitable treatment? *Lancet Infect Dis*. 2020. [https://doi.org/10.1016/S1473-3099\(20\)30262-0](https://doi.org/10.1016/S1473-3099(20)30262-0).
- Richardson P, Corbellino M, Stebbing J. Baricitinib for COVID-19: a suitable treatment? *Lancet Infect Dis*. 2020. [https://doi.org/10.1016/S1473-3099\(20\)30270](https://doi.org/10.1016/S1473-3099(20)30270).
- Colombi D, Bodini FC, Petrini M, et al. Well-aerated lung on admitting chest ct to predict adverse outcome in COVID-19 pneumonia. *Radiology*. 2020. <https://doi.org/10.1148/radiol.2020.01433>.
- Stebbing J, Phelan A, Griffin I, et al. COVID-19: combining antiviral and anti-inflammatory treatments. *Lancet Infect Dis*. 2020;20:400–2.
- Richardson P, Griffin I, Tucker C, et al. Baricitinib as potential treatment for 2019-nCoV acute respiratory disease. *Lancet*. 2020;395:e30–31.