

# Prenatal hydrops fetalis associated with infantile free sialic acid storage disease due to a novel homozygous deletion in the *SLC17A5* gene

Afia Hasnain,<sup>1</sup> Sherri Burnett,<sup>2</sup> Ronald Agatep,<sup>1</sup> Elizabeth Spriggs,<sup>1,2</sup> Bernard Chodirker,<sup>1,2</sup> and Aizeddin (Aziz) A. Mhanni<sup>1,2</sup>

<sup>1</sup>Department of Biochemistry and Medical Genetics, <sup>2</sup>Department of Pediatrics and Child Health, Max Rady College of Medicine, Rady Faculty of Health Sciences, University of Manitoba, Winnipeg, Manitoba R3A 1R9, Canada

**Abstract** Nonimmune hydrops fetalis, the excessive accumulation of serous fluid in the subcutaneous tissues and serous cavities of the fetus, has many possible etiologies, providing a diagnostic challenge for the physician. Lysosomal storage diseases have been reported in up to 5%–16% of nonimmune hydrops fetalis pregnancies. Infantile free sialic acid storage disease (ISSD) (OMIM #269920) is a severe form of autosomal recessive sialic acid storage disease. ISSD is caused by mutations in *SLC17A5* (OMIM #604322), which encodes sialin, a lysosomal-membrane sialic acid transporter. We describe a case of fetal hydrops due to a novel homozygous deletion in the *SLC17A5* gene. Prenatal single-nucleotide polymorphism (SNP) array analysis was performed on amniocytes after the discovery of fetal hydrops at 24 wk gestation revealing no copy-number variants. The SNP array, however, reported several regions of homozygosity (ROHs) including one on Chromosome 6 encompassing the *SLC17A5* gene. High levels of urine sialic acid in the newborn were detected. *SLC17A5* gene sequencing was initiated with no sequence variants identified; however, the assay failed to amplify exons 8 and 9, prompting an exon-level copy-number analysis that revealed a novel homozygous deletion of exons 8 and 9, inherited from heterozygous carrier parents. ISSD should be considered in the workup of patients with nonimmune hydrops fetalis, and analysis for *SLC17A5* deletions should be carried out when variants are not detected by gene sequencing.

Corresponding author:  
amhanni@hsc.mb.ca

© 2021 Hasnain et al. This article is distributed under the terms of the Creative Commons Attribution-NonCommercial License, which permits reuse and redistribution, except for commercial purposes, provided that the original author and source are credited.

**Ontology terms:** hydrops fetalis; nonimmune hydrops fetalis; severe hydrops fetalis

Published by Cold Spring Harbor Laboratory Press

doi:10.1101/mcs.a006106

## CASE PRESENTATION

A 32-yr-old gravida 3, para 2 patient was referred at 24 wk gestation for fetal hydrops detected on ultrasound imaging. The mother has two healthy children from a previous relationship. The father of this pregnancy is a healthy 33-yr-old man. The family history was unrevealing and there is no known close consanguinity; however, the couple were of Indigenous descent from the same community. The pregnancy was otherwise unremarkable with no history of exposure to known teratogens. The prenatal ultrasound identified massive ascites and moderate body wall edema in the fetus. The cardiac anatomy and function were normal, and there were no masses to suggest a structural etiology of the hydrops. Maternal viral studies returned without evidence of active infection. An amniocentesis revealed a normal quantitative fluorescent polymerase chain reaction (QF-PCR) result. Chromosomal single-nucleotide polymorphism (SNP) array studies were performed (see the Technical Analysis section).

The patient presented at 34 wk gestation following premature rupture of membranes. Given the breech presentation, her history of having a previous Caesarean section, and parental desire for full fetal/neonatal intervention, she underwent a cesarean section. A 3230-g (97th %ile) male infant was delivered with Apgar scores of 3 at 1 min and 6 at 5 min. His length was 46 cm (50th %ile), and his head circumference was 33 cm (90th %ile). The neonate was edematous with a distended abdomen. He required immediate and ongoing support on the ventilator for respiratory failure, and repeated paracentesis was performed for removal of accumulating ascitic fluid. An abdominal ultrasound on the first day of life revealed a large amount of ascites. The liver was of normal size, shape, and echotexture. The spleen was enlarged measuring ~6 cm in length. A brain sonogram revealed some abnormalities prompting magnetic resonance imaging (MRI). The MRI revealed hypoplasia of the corpus callosum, interhemispheric cysts demonstrating mass effect on the posterior aspect of the right thalamus, and bilateral periventricular band heterotopia. The infant died at 4 wk of age.

### TECHNICAL ANALYSIS

SNP array analysis was performed on fetal amniotic fluid using a custom-designed Illumina SNP array at Invitae Corporation. This array contains >1,700,000 SNP markers covering both coding and noncoding human genome sequences and the resolution for regions of homozygosity of  $\geq 5$  Mb.

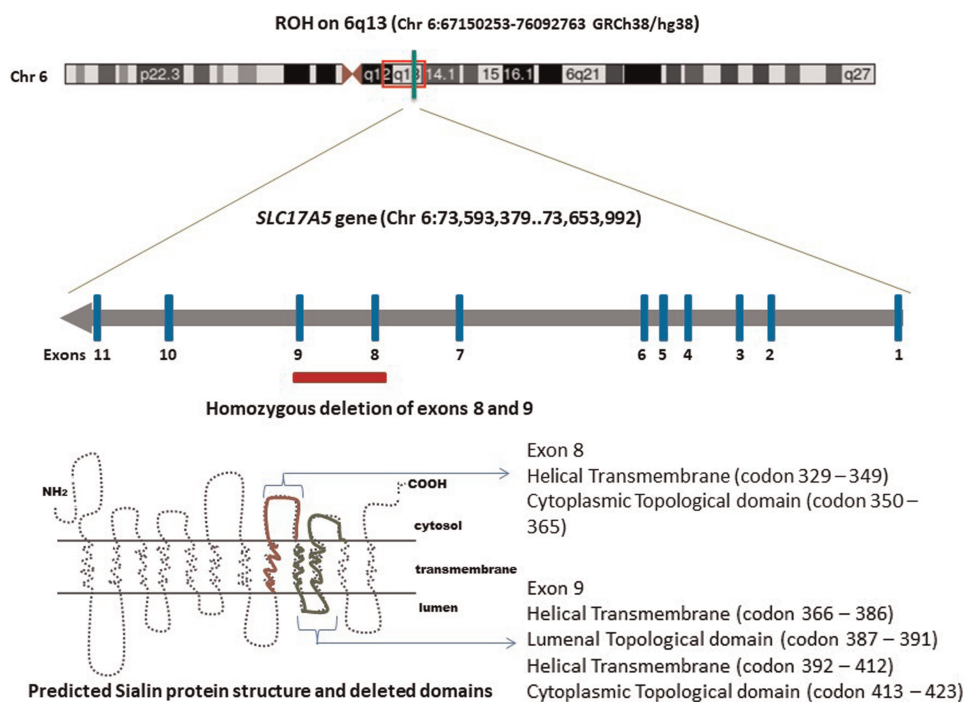
Urine sialic acid was detected using liquid chromatography-tandem mass spectrometry (LC-MS/MS) by the EGL Genetic Diagnostics.

The *SLC17A5* gene sequencing was carried out by Sanger sequencing at Prevention Genetics.

For deletion analysis, exon-level oligo array comparative genome hybridization (CGH) (ExonArrayDx) was carried out by GeneDx.

### RESULTS INTERPRETATION

The SNP array analysis on amniocytes revealed three regions of homozygosity (ROHs); however, no copy-number variants were reported. The three ROHs included one region on Chromosome 2 (2:185534691-193376100) and two regions on Chromosome 6 (6:67150253-76092763 and 6:110317723-118527953) (Fig. 1). A search for genes with autosomal recessive inheritance pattern identified 10 genes within these ROHs. The region on Chromosome 6 included the *SLC17A5* gene, which is associated with a phenotype consistent with our patient's presentation. This prompted urine sialic acid quantification, which revealed increased levels at 9570  $\mu\text{mol/g}$  creatinine for this age (normal 66–826 for age <2 yr). This was followed by molecular analysis of the *SLC17A5* gene by sequencing. No sequence variants were identified, however; the assay failed to amplify exon 8 and 9. The results were suggestive of a possible homozygous deletion of exon 8–9. Targeted array CGH with exon-level resolution indicated that the infant is homozygous for a deletion including at least exons 8–9 of the *SLC17A5* gene, based on the reference transcript and genomic sequence coordinates specific to *SLC17A5*. The deletion can also be described as NG\_008272.1:c.(978+1\_979-1)(1259+1\_1260-1)del and predicted to result in a frameshift after 25 codons (p.Asn327Valfs\*25) (Table 1). Loss of function is a known mechanism of disease for *SLC17A5* and a predicted premature stop codon may result in a truncated protein product or absent protein because of nonsense-mediated decay (PVS1). This variant is absent from population specific-databases (gnomAD) (PM2) and has not been previously reported in the medical literature, ClinVar, or LOVD disease-specific databases. The patient's phenotype



**Figure 1.** A region of homozygosity (ROH) was found in this patient on Chromosome 6 (6:67150253-76092763). The *SLC17A5* gene associated with autosomal recessive infantile free sialic acid storage disease (ISSD) is found in this region. A homozygous deletion was identified in exons 8 and 9 of the *SLC17A5* gene. The variant results in deletion of helical transmembrane and cytoplasmic domains and is predicted to result in a premature truncation of the protein.

and very high levels of urine sialic acid are consistent with infantile free sialic acid storage disease (ISSD) (PP4). Based on current available evidence, this variant is interpreted as a pathogenic variant according to the ACMG variant classification guidelines (Richards et al. 2015) and ACMG/AMP recommendations for interpreting the loss of function PVS1 variants (Abou Tayoun et al. 2018).

The parents were heterozygous for this deletion. These findings are consistent with infantile free Sialic acid storage disease.

## SUMMARY

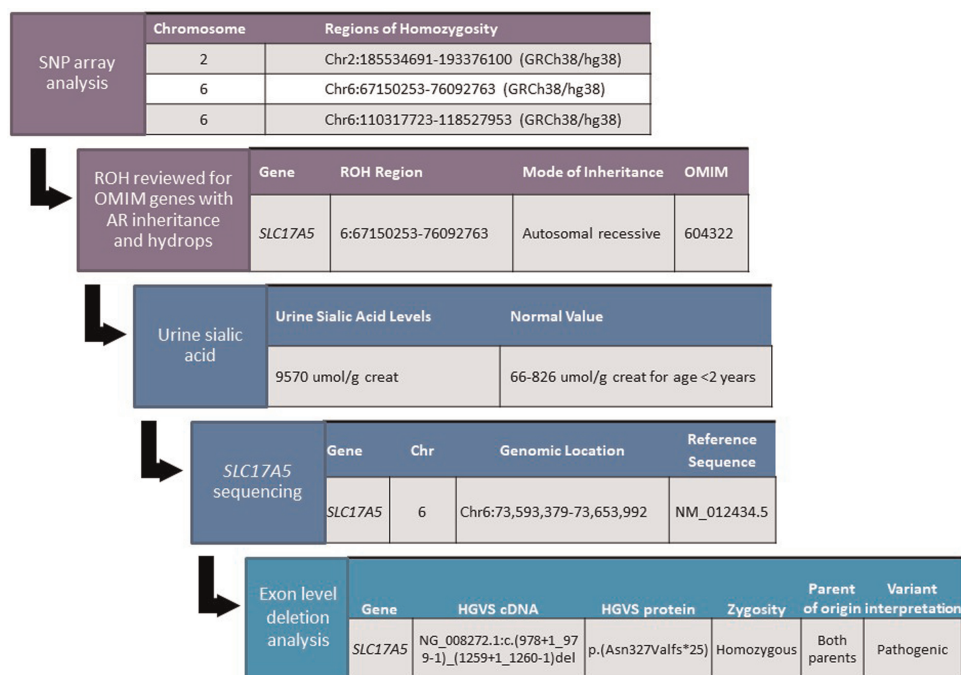
Sialic acid storage diseases (SASDs) may present in a severe form as ISSD (OMIM #269920) or as a slowly progressive adult form, Salla disease, that is prevalent in Finland (OMIM #604369) (Verheijen et al. 1999). SASDs are autosomal recessive disorders caused by mutations in *SLC17A5* (OMIM #604322), which encodes sialin, a lysosomal-membrane sialic acid

**Table 1.** Genomic findings

| Gene           | Genomics location           | HGVS cDNA  | HGVS protein       | Zygosity   | Parent of origin | Variant interpretation |
|----------------|-----------------------------|--|--------------------|------------|------------------|------------------------|
| <i>SLC17A5</i> | Chr 6:73,593,379-73,653,992 | NG_008272.1:<br>c.(978+1_979-1)<br>_(1259+1_1260-1)del | (p.Asn327Valfs*25) | Homozygous | Both parents     | Pathogenic             |

transporter (Verheijen et al. 1999). The clinical features include coarse facies, hepatosplenomegaly, and prominent psychomotor delay. The severe form presents with intrauterine hydrops fetalis, neonatal ascites, failure to thrive, and early death (<2 yr of age) (Aula et al. 2000, 2006; Froissart et al. 2005; Zielonka et al. 2019). Elevated free urine sialic acid is suggestive of ISSD, and molecular diagnosis should be considered in cases with nondiagnostic biochemical analyses (Hartley et al. 2013).

Hydrops fetalis with ISSD has been reported in patients with frameshift truncating mutations, small deletions, and an exon-level deletion involving exons 10 and 11 in *SLC17A5* (Froissart et al. 2005). Exon-level deletion has also been reported in one patient with a severe phenotype who was compound heterozygous for a deletion in exon 9 because of a splice site mutation in intron 9 and a 15-bp deletion in exon 6 (Kleta et al. 2003). Our patient presented with a severe phenotype as intrauterine hydrops fetalis. The mother's initial prenatal investigations, including QF-PCR analysis and screening for congenital viral infections, were normal. No copy-number variations were identified on the prenatal SNP array analysis; however, regions of homozygosity were identified on Chromosomes 2 and 6. These regions were analyzed for any genes associated with autosomal recessive disorders reported in OMIM. The *SLC17A5* gene was found within the region of homozygosity on Chromosome 6 and is associated with autosomal recessive ISSD. Urine sialic acid analysis showed very high levels in the patient consistent with ISSD. Subsequent *SLC17A5* gene sequencing was performed; however, the analysis did not identify any single-nucleotide variants. The sequencing analysis failed to amplify exons 8 and 9. Exon-level deletion analysis using array CGH detected



**Figure 2.** Single-nucleotide polymorphism (SNP) array analysis carried out in this patient revealed three regions of homozygosity (ROHs). The ROHs were reviewed for genes associated with autosomal recessive inheritance pattern and hydrops fetalis; one of the ROHs on Chromosome 6 was found to encompass the *SLC17A5* gene. High urine sialic acid levels were followed by *SLC17A5* gene sequencing. No variants were identified, and exon-level deletion analysis was performed. This analysis revealed a homozygous deletion of exons 8 and 9 in this gene, confirming the diagnosis of ISSD. (AR) Autosomal recessive.

homozygous deletion of *SLC17A5* exons 8 and 9 (Fig. 1). A summary of investigation in this patient is presented in Figure 2.

Homozygous deletion of the *SLC17A5* exons 8 and 9 has not been previously reported. These two exons comprise 280 bp of coding region in this gene with a total of 11 exons. The parents of this patient are nonconsanguineous; however, they are from the same Indigenous community. The parents were tested for the deletion, and both were found to be heterozygous carriers of exon 8–9 deletion.

Previous reports on frameshift-truncating mutations or small deletions in *SLC17A5* (Froissart et al. 2005) and a splice site variant leading to exon 9 deletion (Kleta et al. 2003) have been associated with severe phenotype and hydrops. This is the first case, to our knowledge, with a homozygous deletion encompassing two exons of *SLC17A5*.

ISSD should be included in the differential diagnosis of patients with nonimmune hydrops fetalis. In the absence of recurrent *SLC17A5* variants, deletion analysis should be considered in these patients.

## ADDITIONAL INFORMATION

### Data Deposition and Access

The variant was submitted to ClinVar (<https://www.ncbi.nlm.nih.gov/clinvar/>) and can be found under accession number SCV001865325.

### Ethics Statement

Verbal consent for publication was obtained from the family. We did not require Research Ethics Board approval as the molecular testing reported in this manuscript was done as part of standard clinical care.

### Acknowledgments

We thank the family for their cooperation.

### Author Contributions

A.H. and A.A.M. prepared the original draft. A.M.M., S.B. and B.C. oversaw patient care, data collection, data analysis, and genetic interpretation. R.A. and E.S. assisted with the molecular analysis. All coauthors read and approved the manuscript.

## REFERENCES

- Abou Tayoun AN, Pesaran T, DiStefano MT, Oza A, Rehm HL, Biesecker LG, Harrison SM, ClinGen Sequence Variant Interpretation Working Group (ClinGen SVI). 2018. Recommendations for interpreting the loss of function PVS1 ACMG/AMP variant criterion. *Hum Mutat* **39**: 1517–1524. doi:10.1002/humu.23626
- Aula N, Aula P. 2006. Prenatal diagnosis of free sialic acid storage disorders (SASD). *Prenat Diagn* **26**: 655–658. doi:10.1002/pd.1431
- Aula N, Salomäki P, Timonen R, Verheijen F, Mancini G, Månsson JE, Aula P, Peltonen L. 2000. The spectrum of *SLC17A5*-gene mutations resulting in free sialic acid-storage diseases indicates some genotype–phenotype correlation. *Am J Hum Genet* **67**: 832–840. doi:10.1086/303077
- Froissart R, Cheillan D, Bouvier R, Tournet S, Bonnet V, Piraud M, Maire I. 2005. Clinical, morphological, and molecular aspects of sialic acid storage disease manifesting in utero. *J Med Genet* **42**: 829–836. doi:10.1136/jmg.2004.029744
- Hartley J, Salman M, Booth F, Seargeant L, Wenger D, Wrogemann J, Mhanni A. 2013. Diagnostic challenges in Salla disease. *Open J Genet* **3**: 46–49. doi:10.4236/ojgen.2013.32A3007

### Competing Interest Statement

The authors have declared no competing interest.

### Referees

Ralph J. DeBerardinis  
Anonymous

Received May 8, 2021; accepted  
in revised form August 19, 2021.

- Kleta R, Aughton DJ, Rivkin MJ, Huizing M, Strovel E, Anikster Y, Orvisky E, Natowicz M, Krasnewich D, Gahl WA. 2003. Biochemical and molecular analyses of infantile free sialic acid storage disease in North American children. *Am J Med Genet A* **120A**: 28–33. doi:10.1002/ajmg.a.20024
- Richards S, Aziz N, Bale S, Bick D, Das S, Gastier-Foster J, Grody WW, Hegde M, Lyon E, Spector E, et al. 2015. Standards and guidelines for the interpretation of sequence variants: a joint consensus recommendation of the American College of Medical Genetics and Genomics and the Association for Molecular Pathology. *Genet Med* **17**: 405–424. doi:10.1038/gim.2015.30.
- Verheijen FW, Verbeek E, Aula N, Beerens CE, Havelaar AC, Joosse M, Peltonen L, Aula P, Galjaard H, van der Spek PJ, et al. 1999. A new gene, encoding an anion transporter, is mutated in sialic acid storage diseases. *Nat Genet* **23**: 462–465. doi:10.1038/70585
- Zielonka M, Garbade SF, Kölker S, Hoffmann GF, Ries M. 2019. A cross-sectional quantitative analysis of the natural history of free sialic acid storage disease—an ultra-orphan multisystemic lysosomal storage disorder. *Genet Med* **21**: 347–352. doi:10.1038/s41436-018-0051-3