

Available online at www.sciencedirect.com

ScienceDirect

journal homepage: www.elsevier.com/locate/radcr

Case Report

Unusual case presentation of fungal ball infection causing diabetes insipidus and seizure disorder

Ali Guy, Clinical Assistant Professor^a, Angela Guy, PhD^b, Masum Rahman^c, Marina Kokova^d, Azizjon Abdurakhimov^e, Azaliia Persits^f, Kristi Saliyaj^g, Ina Kola^h, Anisa Cobo^g, Juna Musa, MD, MSc^{i,*}

^aDepartment of Physical Medicine and Rehabilitation, New York University, School of Medicine, NYU Medical Center, New York, NY, USA

^bHealth Emphasis California School of Professional Psychology Alliant International University, Los Angeles, CA, USA

^cDepartment of Neurosurgery Mayo Clinic, Rochester, MN, USA

^dNYU Langone Hospital Brooklyn, New York, NY, USA

^ePARS Pain and Rehabilitation Services Brooklyn, New York, NY, USA

^fTraining, New York, NY, USA

^gMother Tereza Hospital, Tirana, Albania

^hDepartment of Burns and Plastic, Tirana, Albania

ⁱPhysiology and Biomedical Engineering, Mayo Clinic, Rochester, MN, USA

ARTICLE INFO

Article history:

Received 18 November 2020

Revised 8 January 2021

Accepted 11 January 2021

Keywords:

Fungal ball

Chronic rhinosinusitis

Fungal rhinosinusitis

Sphenoid sinus

Aspergillus spp

ABSTRACT

Sphenoid sinus fungal ball (FB) is a noninvasive fungal infection affecting predominantly immunocompetent middle-aged female patients. Common clinical manifestations include headaches, postnasal drip, and nasal discharge. In this case report, we present a 56-year-old female with a 10-year history of occasional dizziness, vertigo, nystagmus, feeling disoriented and feeling her eyes moving rapidly. Complaints of restlessness, insomnia, anxiety, stress and anger were also present. Due to the nonspecific nature of her symptoms, a diagnosis of sphenoid sinus FB was overlooked. Definitive diagnosis was established after performing a nasal endoscopy and subsequent histopathological examination of the collected sinus tissues. The histopathology report disclosed Aspergillus FB with chronic sinusitis. Due to the decade long delay in diagnosis and proper treatment, septal wall collapse occurred, with the patient developing diabetes insipidus with hyponatremia that led to a massive seizure and fall, resulting in multiple disc herniations. Surgical removal of the FA elicited a complete resolution of her symptoms and a full recovery.

Although fungal rhinosinusitis is a well recognized spectrum of diseases by ENT specialists, through this case report we hope to draw attention to this particular pathological entity within fungal infections, while simultaneously underlining the broad spectrum of symptoms with which it may manifest and the importance of including FA

* Corresponding author.

E-mail address: musajuna@gmail.com (J. Musa).

<https://doi.org/10.1016/j.radcr.2021.01.030>

1930-0433/© 2021 The Authors. Published by Elsevier Inc. on behalf of University of Washington. This is an open access article under the CC BY-NC-ND license (<http://creativecommons.org/licenses/by-nc-nd/4.0/>)

infections when considering the differential diagnosis in patients with long-standing chronic sinusitis.

© 2021 The Authors. Published by Elsevier Inc. on behalf of University of Washington.

This is an open access article under the CC BY-NC-ND license

(<http://creativecommons.org/licenses/by-nc-nd/4.0/>)

Introduction

Fungal rhinosinusitis encompasses a spectrum of infections, commonly affecting the paranasal sinuses. Sinonasal fungus ball is an extramucosal and noninvasive mycotic proliferation that fills one or more paranasal sinuses [1,2]. Based on histopathology, it is generally classified into invasive and noninvasive fungal infections. The pathological features of non-invasive fungal rhinosinusitis comprised of fungal ball (FB) and allergic fungal rhinosinusitis, include confinement to the paranasal sinuses, mucous membrane, and bone wall without fungal invasion [3,4]. The infectious agent in FB is usually *Aspergillus* spp. [5]. Maxillary sinus is most commonly involved followed by sphenoid sinus [6,7]. Sphenoid sinus FA comprises 4.5%-26.8% of all cases of FA infection [8]. It is usually seen in immunocompetent middle-aged patients, predominantly in females [1].

Patients with sphenoid sinus FA are almost always symptomatic [9]. They usually present with unilateral headaches that become progressively resistant to painkillers and nasal symptoms like postnasal drip, nasal discharge, cough and cosmia [3,10,11]. Visual disturbances and neurological symptoms are rarely reported in these patients [1,3]. Patients present with various nonspecific symptoms and complications due to the anatomic characteristics of the sphenoid sinus. As is the case, the sphenoid sinus lies in close proximity to important anatomic structures, such as the cavernous sinus, the pituitary gland, the internal carotid artery, and cranial nerves II, III, IV, V1, V2, and VI. The dissemination of the infection and inflammation beyond the sphenoid sinus to these structures may result in serious intracranial and orbital complications. It has been reported that 63% of FB cause bone lesions and further damage structures in close proximity [12].

Due to its nonspecific symptoms, diagnosis of a sphenoid sinus FA is often delayed until complications arise or until it's detected on a routine check-up. CT scan of paranasal sinuses plays an important role in establishing the diagnosis and is essential in clinically suspicious patients. Widespread use of CT scan in such patients has significantly increased the rates of detection. Additionally, histopathological findings are required to confirm the diagnosis.

Treatment of sphenoid sinus FA is primarily surgical by functional endoscopic sinus surgery (FESS), targeting the affected sinus and predisposing factors [11]. In the presence of an invasive infection, early initiation of antifungal therapy and reduction of immunosuppression when present, are recommended. The choice of antifungal agents depends on the patient's prior medical history and tolerance.

Case report

Herein is the case of a 56-year-old right-handed female with an unremarkable medical history. No history of diabetes mellitus or cardiac problems. The patient presents with occasional dizziness, vertigo with nystagmus, feeling disoriented and feeling her eyes moving rapidly. These complaints have been present intermittently for the past 10 years. The patient complains of restlessness, insomnia, anxiety, stress, and anger as well.

She initially saw a neurologist. A full workup was ordered. An MRI of the brain came back negative and a CT of the sinuses showed chronic sphenoid sinusitis. After a consult with an ENT specialist she was sent for a second CT scan of the sinuses and hearing testing results were borderline abnormal. The patient was diagnosed with otosclerosis that causes hearing impairment typically involving lower frequencies. However, an audiometry exam did not show a low-frequency hearing loss.

The patient continued seeing different doctors. She saw another neurologist. The neurological examination was negative except for a mild tremor and double vision. She received a diagnosis of panic disorder and was prescribed Paxil. The patient saw another ENT specialist. She had another full workup done including pure tone audiometry, tympanometry, speech in noise test, distortion product otoacoustic emissions (DPOAE) and thin section high-resolution CT of the temporal bones. Complete blood work and hormonal studies were ordered as well. She was then diagnosed as having a right chronic sphenoid sinusitis with complete sinus opacification and hyperostosis. She underwent a laser treatment for her otosclerosis.

Finally, after seeing a third ENT doctor an endoscopic examination of the nasal cavity was suggested. The pathology report of the collected specimens came back as Aspergillosis FA with chronic sphenoid sinusitis. The patient underwent an extended right image-guided sphenoidotomy. The postoperative CT-scans show the resection of the right osteomeatal unit along with a contiguous total ethmoidectomy, left osteomeatal unit resection, as well as an apparent widening of the left sphenoidal recess (Figs. 1-4). A septoplasty, right sphenoid and total ethmoid sinusitis treatment were performed.

It was subsequently determined that the fungal infection at a certain point had eroded the wall of the sphenoid sinus, spreading into the brain parenchyma and causing symptoms of headache, vertigo and nystagmus. The patient eventually developed diabetes insipidus associated with polyuria, polydipsia and hyponatremia that led to a massive seizure, which resulted in a hard fall in the patient's kitchen marble floor. She injured her lower back with multiple disc herniations present in the MRI.

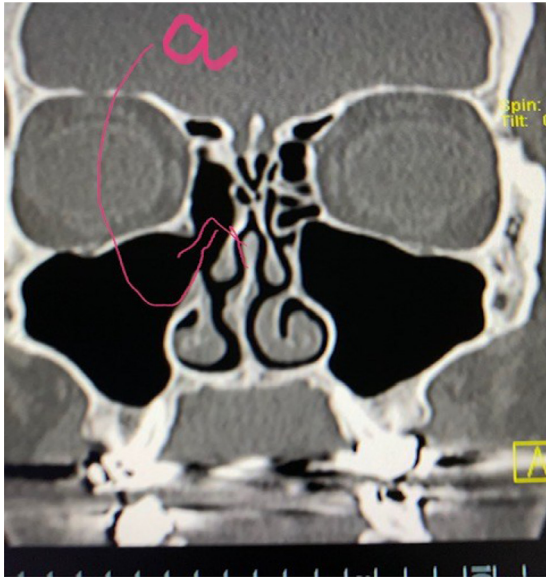


Fig. 1 – The label “a” points to prior resection of the right osteomeatal unit along with a contiguous total ethmoidectomy.

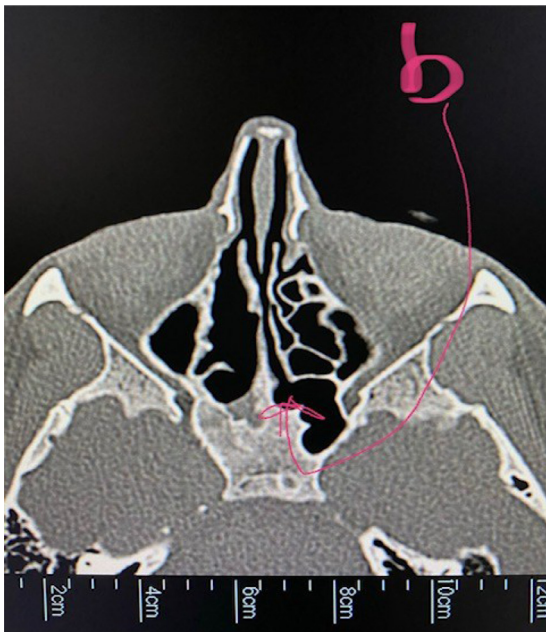


Fig. 2 – The label “b” points to a left sphenothmoidal recess.

Of note, these visits and examinations were conducted in the span of 10 years. The hospital admission due to the seizure and fall, allowed for a full workup that revealed the dilutional hyponatremia and diabetes insipidus. Further radiologic evaluation delineated the etiology, the FA, responsible for the chronic headaches, bouts of dizziness and nystagmus due to the pressure on the optic nerve, anxiety, mood changes, depression and ultimately the development of diabetes insipidus.

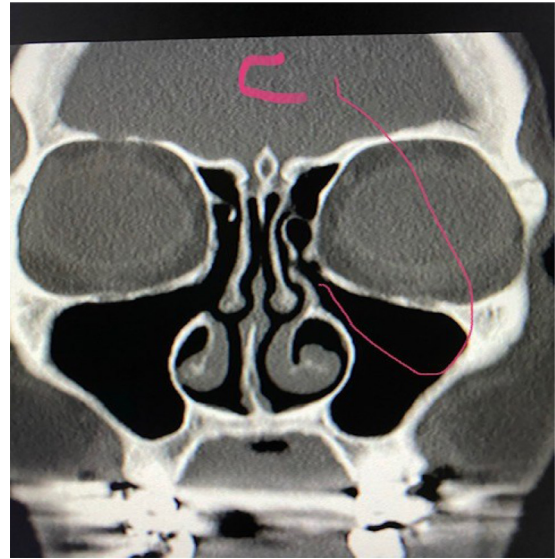


Fig. 3 – The label “c” points to an interim left osteomeatal unit resection since the first study.

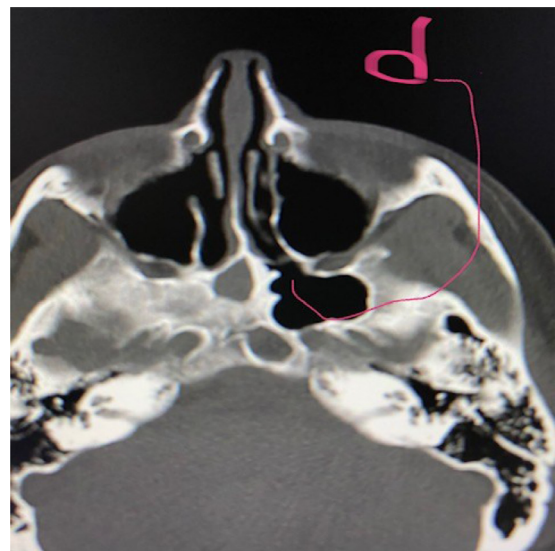


Fig. 4 – The label “d” points to an apparent widening of the left sphenothmoidal recess.

The patient was initially admitted to the ICU where she was treated for several days and afterwards had her FA adequately removed, which prompted a complete resolution of all her symptoms, apart from diabetes insipidus. She was left with permanent diabetes insipidus for which she was placed on an appropriate pharmacological therapy.

CT-scans following the right-sided sphenoidotomy

Discussion

Fungal ball is a type of noninvasive chronic rhinosinusitis defined as an extramucosal, densely compacted mass of fun-

gal hyphae associated with minimal mucosal inflammation [7,11]. Histopathological examination reveals an aggregation of tightly packed hyphae with alternating zones of dense and nondense growth, embedded in fibrinous inflammatory exudate with abundant neutrophils, causing a partial or total obstruction of the sinus cavity [3,7].

Various risk factors have been taken into consideration as potential predisposing elements in the pathogenesis of the infection, including immunologic status, professional and environmental factors and existing sinus pathology, with no association being found [3]. Anatomic variations or anomalies of the middle meatus, middle turbinate or the presence of a septal deviation have been hypothesized as possible predisposing factors, but are not supported by current data, as these anomalies are present only in a small number of patients [3,9].

The pathogenesis of FA remains elusive. It has been proposed that high quantities of fungal spores are introduced into the sinus cavity through the natural ostium by inhalation, what is known as the *aerogenic pathway* [3,11]. The *odontogenic pathway* has been put forward to explain the association with prior dental procedures as evidenced in certain cases. It has been suggested that certain components of dental fillings such as zinc oxide promote fungal growth [3,7,11]. A possible association between previous surgery or mucosal injury and the development of FA has also been proposed, as well as blockage of the sinonasal passages due to an obstructing neoplasm [7].

The clinical spectrum is heterogeneous with asymptomatic infections diagnosed as incidental findings, to symptomatic ones presenting with complaints such as purulent chronic discharge, obstruction, headache, facial pain, postnasal drip with or without nocturnal cough and cacosmia [3]. Reports have found sphenoid FA to almost always be symptomatic with frequent retro-orbital pain, postnasal discharge and cough [13,14].

Neurological symptoms such as the ones our patient manifested are rarely part of the clinical presentation and psychological symptoms are often dismissed and glossed over when considering the differential diagnosis. Consequently, through this case report we hope to draw attention to this pathological entity, while simultaneously underlining the broad spectrum of symptoms with which it may manifest.

Neuropsychological assessment

From a mental health and cognitive functioning perspective, the present case demonstrates the psychological and neurocognitive sequelae of cerebral infections. While the patient was ultimately diagnosed with chronic sinusitis, the preceding medical diagnoses and interventions warrant discussion within the scope of the patient's psychological and cognitive functioning to anchor the implications of psychological symptoms superimposed upon medical conditions.

Within the present case study, the patient's symptom presentation of altered mental status, unstable gait, confusion, irritability, personality changes, difficulty concentrating, mood changes, and depressive mood were commensurate with chronic hyponatremia (ie, low sodium concentration in the blood) [15], which she was eventually misdiagnosed with.

The severity of neurological symptomology, with respect to behavioral manifestations, has been said to be contingent upon the level of brain volume regulation [16]. More specifically, the severity of the brain volume dysregulation is positively correlated with maladaptive neurological symptoms and behavioral presentations; lower sodium levels are correlated with more significant neurological disturbances and subsequent neuropsychological pathology. Research suggests that sodium disturbances are often comorbid with neurological and neurocognitive disruptions. This is due to the detrimental effects of disequilibrium of sodium and water on the brain, wherein dysfunctions in the central nervous system are prevalent as the brain incurs changes in neuronal cellular activity [15]. Such metabolic brain distortions can have multifaceted and wide-spread effects if inappropriately treated. Notwithstanding initial unremarkable neurological impressions, the patient's medically-induced psychological effects and related cognitive-behavioral manifestations underscore the idea that mental health considerations may serve to predict health complications that may otherwise be undetectable through standard medical diagnostic protocols.

However, hyponatremia, as in such pathologic cases, has been documented as iatrogenically-induced due to fluid administration [15]. Additionally, administration of serotonin reuptake inhibitors (SSRIs; ie, the patient's prescription of Paxil) have been associated with syndromes of inappropriate antidiuretic hormone (ADH) secretion that precede hyponatremia [15]. Similarly, there are also many neurological risks to rapid correction of sodium disturbances, such as altered mental status, hence warranting enhanced attunement to detection of the underlying condition [15]. Of note, in the present case study, the patient's mood symptoms, specifically emotional dysregulation and anger, were exacerbated by her misdiagnoses and erroneous treatment protocols by her medical doctors.

Another important consideration relative to the clinical manifestations, per the present case study, is the prospect of additional insults to the central nervous system and related endocrine functionality due to sodium disruptions. Following hyponatremia, syndromes such as Cerebral Salt Wasting (CSW) have been documented, generally in the form of case reports due to their small incidence rates [17]. CSW is a rare condition of the endocrine system characterized by low sodium concentrations in the blood and subsequent dehydrations due to trauma or injury, such as an infection [15]. Decreases in sodium concentrations have been linked to cerebral edema, with symptom presentations such as irritability, altered mental status, lethargy, and seizures [16]. All of such symptoms were remarkable in the present case. Therefore, the patient within the present case may have experienced iatrogenic CSW, again underscoring the necessity for acute attention to detail relative to the patient's endorsed experience when diagnosing.

As demonstrated by this case, discerning the etiology of sodium disturbances is essential relative to the pervasive nature of metabolic imbalances on the brain and nervous system, and, hence, the importance of early diagnosis. Similarly, the psychological and neuropsychological sequelae of metabolic disruptions further underscore the importance of

alerting healthcare providers to comprehensively consider consultation and interdisciplinary collaboration to confirm or rule out diagnoses.

Regarding the finding of chronic sinusitis, research suggests that sinus disorders are often comorbid with psychological distress and mood disorders. More specifically, health disturbances related to sinus issues have been notably linked to impairment and distress in work, home, or social settings, emotional dysregulation, and sleep disturbances [18]. Studies have demonstrated that psychopathologies related to anxiety and depression are more pronounced amongst individuals suffering from chronic sinusitis relative to controls [18]. Hence, coupled with the symptom presentations within the present case study specific psychological distress (ie, irritability, anxiety, stress, insomnia), it can be deduced that such individuals are at heightened risk for experiencing anxiety and depression.

Further, sinus complications preceded by fungal infections introduce more profound mental health and cognitive concerns per the physiological mechanisms of infection. Regarding the pathophysiology of sinus disturbances, it is crucial to recognize the effects on neural plasticity. Specifically, in the presence of a pathogen or other abnormality, the synaptic networks of the brain are subject to changes in neurotransmission, ion channels, and neural synapses. Such events result in altered cortical plasticity and can lead to the development and maintenance of sinus and related functional disturbances [19]. As such, the behavioral and mood symptomology (ie, anxiety, irritability, and concentration difficulties) have been speculatively connected to functional changes in the limbic system (ie, emotion and memory) and the central nervous system [18].

From a diagnostic perspective, clinical assessment of the etiology of disease presentation is challenging as there are numerous differential diagnoses to consider due to the pervasive nature of cortical involvement and subsequent disease expression. Additionally, comorbid psychological symptomology impacts the clinical picture with respect to discerning appropriate medical interventions. Medical presentation can be complicated by psychological distress, which can manifest somatically, as evident in the present case. The patient was prescribed psychotropic medications by her neurologist secondary to mood symptoms relative to her functional impairments and negative medical examinations. Therefore, patients presenting with psychological symptoms must also be considered for psychological evaluation to diagnose and treat accompanying mental health issues, and support the management of the treatment plan.

Likewise, assessments of mental status and determination of the effects on the patient's activities of daily living and functioning are vital to consider amongst patients of this nature [20]. Therefore, psychological assessment should be incorporated to obtain information regarding emotional, attentional, and behavioral parameters. Neuropsychological assessment by a licensed neuropsychologist may also be of clinical utility for evaluations of cognitive and psychomotor functioning throughout. Psychometrically validated and empirically-based questionnaires can be particularly useful to not only reducing the impact on the patient's quality of life but also to formulating diagnoses and measuring treatment progress

relative to the above-mentioned links between psychological symptoms and disease severity.

Lastly, the inclusion of mental health providers is further warranted concerning effective treatment and mindfulness to the patient's health and wellness across lifestyle domains. Specifically, psychological comorbidities are often unattended to during pharmacological intervention, as mental health symptoms are thought to dissipate yet often persist beyond return to baseline from a medical perspective [21]. Further, psychological support is integral relative to the patient's overall well-being during the course of treatment. Mental health providers are qualified to offer psychoeducation regarding the cognitive, emotional, and behavioral byproducts to enable the patient to establish adaptive coping mechanisms and receive support related to their mood and adjustment along the treatment trajectory. As evidenced, consultation and collaboration between mental health and medical providers are crucial for effective management of symptom presentations similar or related to those presented in this case.

Conclusion

Overall, clinical findings for sphenoid sinus FA can be unreliable, and a high clinical suspicion should be maintained in middle-aged patients with progressive headaches, vertigo, and nystagmus. Therefore, it is our opinion that sinus infections when chronic and associated with these symptoms should be much more aggressively pursued and treated. CT scan of the paranasal sinuses and nasal endoscopy with pathology are useful and highly specific in determining the diagnosis. Surgical management, which consists of the removal of the FA by functional endoscopic sinus surgery (FESS), is the definitive treatment.

Patient Consent

Patient consent was obtained.

REFERENCES

- [1] Kim JS, Kim BK, Hong SD, Kim HJ, Kim HY. Clinical characteristics of sphenoid sinus fungal ball patients with visual disturbance. *Clin Exp Otorhinolaryngol* 2016;9:326–31.
- [2] Yoon YH, Xu J, Park SK, Heo JH, Kim YM, Rha KS. A retrospective analysis of 538 sinonasal fungus ball cases treated at a single tertiary medical center in Korea (1996–2015). *Int Forum Allergy Rhinol* 2017;7:1070–5.
- [3] Grosjean P, Weber R. Fungus balls of the paranasal sinuses: a review. *Eur Arch Otorhinolaryngol* 2007;264:461–70. doi:10.1007/s00405-007-0281-5.
- [4] Chakrabarti A, Denning DW, Ferguson BJ, Ponikau J, Buzina W, Kita H, et al. Fungal rhinosinusitis: a categorization and definitional schema addressing current controversies. *Laryngoscope* 2009;119:1809–18. doi:10.1002/lary.20520.
- [5] Dufour X, Kauffmann-Lacroix C, Ferrie JC, Goujon JM, Roudier MH, Karkas A, et al. Paranasal sinus fungus ball and surgery: a review of 175 cases. *Rhinology* 2005;43:34–9.

- [6] Granville L, Chirala M, Cernoch P, Ostrowski M, Truong LD. Fungal ball infection coexisting with diabetes and seizure disorders. Fungal sinusitis: histologic spectrum and correlation with culture. *Hum Pathol* Apr 2004;35(4):474–81.
- [7] Montone KT. Pathology of fungal rhinosinusitis: a review. *Head Neck Pathol* 2016;vol. 10(1):40–6. doi:10.1007/s12105-016-0690-0.
- [8] Karkas A, Rtail R, Reyt E, Timi N, Righini CA. Sphenoid sinus fungus ball. *Eur Arch Otorhinolaryngol* Mar 2013; 270(3):893–8.
- [9] Dufour X, Kauffmann-Lacroix C, Ferrie JC, Goujon JM, Rodier MH, Klossek JM. Paranasal sinus fungus ball: epidemiology, clinical features and diagnosis. A retrospective analysis of 173 cases from a single medical center in France. 1989–2002. *Med Mycol* February 2006;44(1):61–7. doi:10.1080/13693780500235728.
- [10] Kwon MO, Kim KS. Headache induced by isolated sphenoid fungal sinusitis: sinus headache? *J Headache Pain* Dec 2009; 10(6):473–6.
- [11] Deutsch Peter George, et al. Invasive and non-invasive fungal rhinosinusitis-a review and update of the evidence. *Medicina* (Kaunas, Lithuania) 2019;55(7):319. doi:10.3390/medicina55070319.
- [12] Charakorn N, Snidvongs K. Chronic sphenoid rhinosinusitis: management challenge. *J Asthma Allergy* 2016;9:199–205. doi:10.2147/JAA.S93023.
- [13] Hun-Jong Dhong MD, Jung Jae-Yun MD, Joo Hyun Park MD. Diagnostic accuracy in sinus fungus balls: CT scan and operative findings. July-August 2000;14(4).
- [14] Klossek JM, Peloquin L, Fourcroy PJ, Ferrie JC, Fontanel JP. Aspergillomas of the sphenoid sinus: a series of 10 cases treated by endoscopic sinus surgery. *Rhinology* 1996;34:179–83.
- [15] Tisdall Martin, et al. Disturbances of sodium in critically ill adult neurologic patients: a clinical review. *J Neurosurg Anesthesiol* 2006;18(1):57–63. doi:10.1097/01.ana.0000191280.05170.0f.
- [16] Pollock AS, Arieff AI. Abnormalities of cell volume regulation and their functional consequences. *Am J Physiol-Renal Physiol* 1980;239:F195–205.
- [17] Tenny S, Thorell W. Cerebral salt wasting syndrome. [Updated 2020 Jul 10]. In: StatPearls [Internet]. Treasure Island (FL): StatPearls Publishing; 2020. Jan-. Available from <https://www.ncbi.nlm.nih.gov/books/NBK534855/>.
- [18] Kim J, Kim D. Chronic rhinosinusitis and increased risk of depression and anxiety—reply. *JAMA Otolaryngol Head Neck Surg* 2019;145(7):690. doi:10.1001/jamaoto.2019.0917.
- [19] Ghadami MR. Chronic rhinosinusitis and increased risk of depression and anxiety: the role of impaired sleep quality. *JAMA Otolaryngol Head Neck Surg* 2019;145(7):689–90. doi:10.1001/jamaoto.2019.0916.
- [20] Robinson SK, McQuaid JR, Viirre ES, Betzig LL, Miller DL, et al. The relationship of tinnitus questionnaires to depressive symptoms, quality of well-being and internal focus. *Int tinnitus J* 2003;9:97–103.
- [21] Adoga AA, Obindo TJ. In: Woolfolk Robert, editor. *Mental Disorders- Theoretical and Empirical Perspectives*; 2013. p. 349–69.