



Contents lists available at ScienceDirect

International Journal of Surgery Case Reports

journal homepage: www.casereports.com

Polyorchidism with presumed contralateral intrauterine testicular torsion

B.M. Leodoro^{a,*}, S.W. Beasley^b, M.D. Stringer^b^a Department of Surgery, Vila Central Hospital, Port Vila, Vanuatu^b Department of Paediatric Surgery, Christchurch Hospital, Christchurch, New Zealand

ARTICLE INFO

Article history:

Received 16 February 2014

Received in revised form

15 September 2014

Accepted 15 September 2014

Available online 13 October 2014

Keywords:

Polyorchidism

Intrauterine testicular torsion

ABSTRACT

INTRODUCTION: Polyorchidism was first described by Blasius in 1670¹ during a routine autopsy. We report a child with unilateral polyorchidism and a contralateral absent testis, a combination not reported previously.

PRESENTATION OF CASE: A 2-year-old boy was referred to the outpatient clinic with an impalpable left testis. At laparoscopy, the left vas deferens and testicular vessels ended blindly proximal to a closed internal ring. No gonadal tissue was identified. On the right side, a single vas deferens and testicular vessels were seen entering the internal ring as normal. The right side of the scrotum was explored and two testes were identified within a single tunica vaginalis.

DISCUSSION: Polyorchidism is rare with a literature search identifying approximately 230 reported cases. Whilst prenatal testicular torsion is increasing being recognized and treated as a surgical emergency,⁹ prenatal testicular torsion in association with polyorchidism has not been previously reported.

CONCLUSION: We describe a unique case of a 2-year-old boy with right-sided polyorchidism and an absent left testis associated with a blind ending vas deferens and testicular vessels, presumed secondary to intrauterine testicular torsion.

© 2014 The Authors. Published by Elsevier Ltd. on behalf of Surgical Associates Ltd. This is an open access article under the CC BY-NC-ND license (<http://creativecommons.org/licenses/by-nc-nd/3.0/>).

1. Introduction

Polyorchidism was first described by Blasius in 1670¹ during a routine autopsy. Since then nearly 230 cases of polyorchidism have been reported with a meta-analysis revealing 140 cases of histologically confirmed polyorchidism in children and adults.² Right sided polyorchidism is less common than on the left side. We report a child with unilateral polyorchidism and a contralateral absent testis, a combination not reported previously.

2. Case report

A 2-year-old boy was referred to the outpatient clinic with an impalpable left testis. On examination, he had a normal right-sided scrotal testis and an adjacent painless smaller solid swelling. He had been born at term weighing 3.9 kg. A routine neonatal check had noted an absent left testis and a normal right testis associated with a presumed small hydrocele. An ultrasound scan demonstrated two testes in the right side of the scrotum with volumes of 0.66 cm³ and 0.22 cm³; neither testis had evidence of a focal lesion or abnormal

echogenicity or perfusion. No testis was evident in the left inguinal canal or left side of the scrotum. Crossed (transverse) testicular ectopia was suspected.

At laparoscopy, the left vas deferens and testicular vessels ended blindly proximal to a closed internal ring (Fig. 1). No gonadal tissue was identified. On the right side, a single vas deferens and testicular vessels were seen entering the internal ring as normal (Fig. 2). The right side of the scrotum was explored and two testes were identified within a single tunica vaginalis. The larger, lower testis had an apparently normal epididymis, vas deferens and vessels whereas the superior, smaller testis had an abnormally shaped epididymis, no vas deferens but an independent vascular supply (Fig. 3). Both testes had an appendix testis.

3. Discussion

Polyorchidism is rare with a literature search identifying approximately 230 reported cases. It occurs most commonly on the left side, with only a few reports of right sided polyorchidism.^{3,4} The condition arises from faulty gonadal development but its precise cause is unknown. The primordial testis develops in the embryo from the genital ridge at around the sixth week of gestation and the epididymis and vas deferens arise from the adjacent mesonephric (Wolffian) duct about two weeks later. Thus, polyorchidism is understood to arise between the sixth and eighth

* Corresponding author at: PMBag 9013, Port Vila, Vanuatu. Tel.: +678 22100; fax: +678 27618.

E-mail address: bleodoro@gmail.com (B.M. Leodoro).

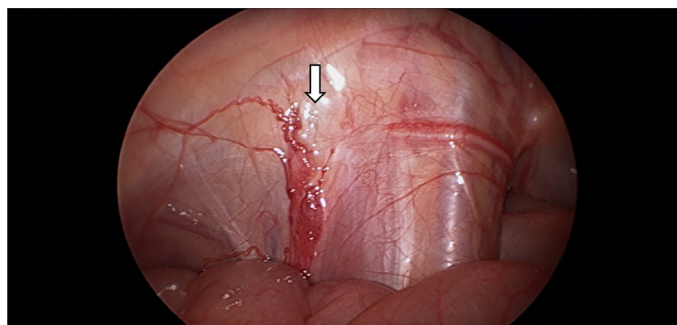


Fig. 1. Laparoscopic view of the left internal ring showing a blind ending vas deferens and testicular vessels and a closed internal inguinal ring (arrow).

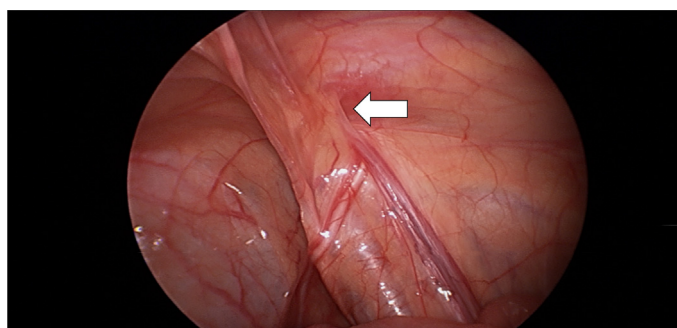


Fig. 2. Laparoscopic view of the right internal ring showing a normal vas deferens and blood vessels entering a patent internal inguinal ring (arrow).

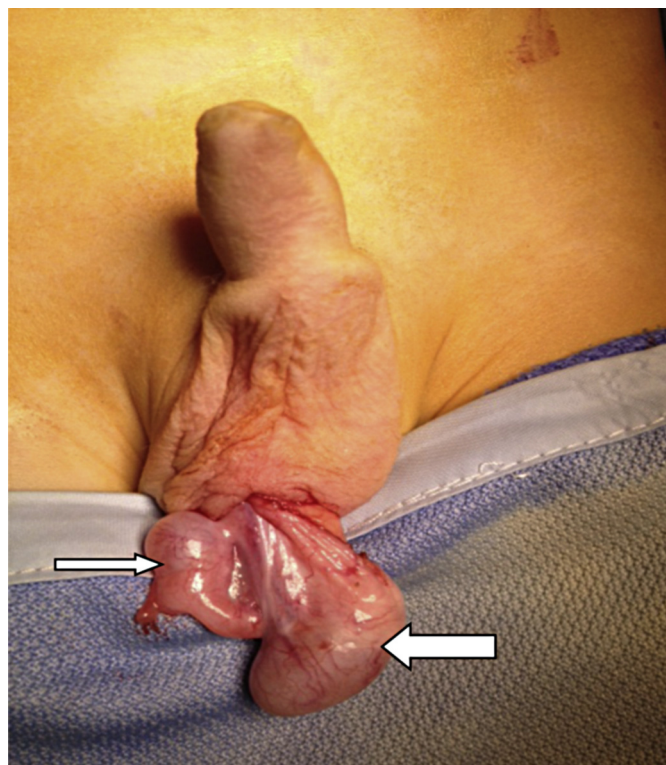


Fig. 3. Operative appearance at scrotal exploration. The lower larger testis (large arrow) was connected to a vas deferens and testicular vessels while the smaller superior testis (small arrow) had its own testicular vessels but no vas deferens.

weeks of gestation. It has been suggested that division of the genital ridge by peritoneal bands is one possible cause for the occurrence of polyorchidism.⁵ According to Leung,⁶ four main variants are recognized (Table 1). Our patient had a supernumerary testis with an abnormal epididymis and no vas deferens and probably most closely resembles type B polyorchidism.

Provisional diagnosis in our patient prior to laparoscopy was crossed (or transverse) testicular ectopia, when the testis has crossed to the contralateral side taking with it the ipsilateral vas deferens and gonadal vessels. This condition is confirmed at laparoscopy by the absence of a vas and vessels entering one internal inguinal ring and the presence of vas and vessels from both right and left sides entering the opposite internal ring. At laparoscopy in our patient, no left sided vas deferens or testicular vessels were seen crossing over to the right internal ring; rather the vas and vessels were seen to end blindly, thereby excluding crossed testicular ectopia. In our patient, the absence of a left sided testis with blind ending ipsilateral vas and vessels would most likely have arisen from torsion and subsequent infarction of an intra-abdominal testis during testicular descent to the inguinal canal (i.e. before 28 weeks of gestation). Prenatal testicular torsion reportedly

occurs in approximately 6.1 per 100,000 births.^{7,8} The frequency may be higher given that the infarcted testis gets resorbed giving rise to reports of the “vanishing testis” as is most likely in this case.⁸ Whilst prenatal testicular torsion is increasing being recognized and treated as a surgical emergency,⁹ prenatal testicular torsion in association with polyorchidism has not been previously reported.

Polyorchidism has been described in association with epididymitis, hydrocele, varicocele, infertility, retractile testis and hypospadias.¹⁰ However, the combination of testicular anomalies seen in our patient has not been described before.

Malignant transformation may occur in the supernumerary testis in polyorchidism, irrespective of its location and the age of the patient. Reported neoplasms include embryonal carcinoma, germ cell tumor, rete testis adenoma and seminoma.¹¹ Regular follow-up with clinical and ultrasound evaluation may lead to early detection of a testicular tumor. If a malignancy is suspected, ultrasound or magnetic resonance imaging may help clarify the need for surgical exploration and biopsy.¹² Other malignancies, such as extra-testicular rhabdomyosarcoma, have also rarely been associated with polyorchidism.¹³

Table 1
Types of polyorchidism (according to Leung⁶).

Type	Description	Comment
A	Commonest. The supernumerary testis lacks an epididymis and vas deferens.	The genital ridge separates without contact with the mesonephric duct.
B	The supernumerary testis has its own epididymis often connected longitudinally with the epididymis of the normal testis.	Division of the genital ridge occurs in the region where the primordial testes are attached to the mesonephric ducts.
C	The supernumerary testis has its own epididymis and shares a vas deferens with the normal testis.	There is incomplete longitudinal division of the genital ridge and the proximal part of the mesonephric duct.
D	The rarest form in which there is complete longitudinal duplication of the genital ridge and mesonephric duct, forming complete duplication of the testis, epididymis and vas deferens.	This may be associated with ipsilateral duplication of the ureter.

References

1. Ahlfeld F. *Die Missbildungen des Menschen*. Grunow, Leipzig; 1880. p. 126.
2. Bergholz R, Wenke K. Polyorchidism a meta-analysis. *J Urol* 2009;**182**:2422–7.
3. Bergholz R, Koch B, Spieker T, Lohse K. Polyorchidism: a case report and classification. *J Pediatr Surg* 2007;**42**(11):1933–5.
4. Thyoka M, Lall A, Godse A. Polyorchidism: a torted right-sided supernumerary testis. *BMJ Case Rep* 2013;**2013**, <http://dx.doi.org/10.1136/bcr-2013-008600>, pii: bcr-2013-008600.
5. Wolf B, Youngson GG. Polyorchidism. *Paed Surg Int* 1998;**13**:65–6.
6. Leung AK. Polyorchidism. *Am Fam Phys* 1988;**38**:153–6.
7. Nandi B, Murphy FL. Neonatal testicular torsion: a systematic literature review. *Pediatr Surg Int* 2011;**27**:1037.
8. John CM, Kooner G, Mathew D. Neonatal testicular torsion: a lost cause? *Acta Paediatr* 2008;**97**:502.
9. Al-Salem AH. Intrauterine testicular torsion: a surgical emergency. *J Pediatr Surg* 2007;**42**(November (11)):1887–91.
10. Jorion JL, Wese FX, Hennebert P. Polyorchidism: report of three cases and further embryological considerations. *Eur Urol* 1990;**17**:90–2.
11. Sumfest JM, Kolon TF, Rukstalis DB. Cryptorchidism. *Medscape* 2012. <http://emedicine.medscape.com/article/438378-overview> [last accessed Jan 2014].
12. Singer BR, Donaldson JG, Jackson DS. Polyorchidism: functional classification and management strategy. *Urology* 1992;**39**:384–8.
13. Thum G. Polyorchidism: case report and review of literature. *J Urol* 1991;**145**:370–2.

Open Access

This article is published Open Access at sciedirect.com. It is distributed under the [IJSCR Supplemental terms and conditions](#), which permits unrestricted non commercial use, distribution, and reproduction in any medium, provided the original authors and source are credited.