



# Sustained Control from Recurring Non-Infectious Uveitic Macular Edema with 0.19 mg Fluocinolone Acetonide Intravitreal Implant – A Case Report

Jorge Meira · Carolina Madeira · Fernando Falcão-Reis ·  
Luís Figueira

Received: August 5, 2019 / Published online: September 10, 2019  
© The Author(s) 2019

**Abstract:** In January 2013, a 54-year-old pseudophakic woman was referred to the ocular inflammation clinic with a diagnosis of panuveitis, already on oral cyclosporine (100 mg/day) since 2010. She was a monocular patient, with the left eye eviscerated due to trauma and secondary endophthalmitis in 1995. She had experienced similar recurring episodes between 2010 and 2013. Examination revealed best-corrected visual acuity (BCVA) of 20/200. The anterior segment revealed the presence of flare and absence of cells. Intraocular pressure (IOP) was 11 mmHg. Fundus examination revealed the presence of anterior

vitreous organization, exuberant cystoid macular edema (CME) and peripheral Dalen-Fuchs nodules with no activity. Systemic workup showed no changes, and a presumptive diagnosis of sympathetic ophthalmia was made. Initial therapy included topical and systemic corticosteroids. Cyclosporine was replaced with methotrexate (20 mg/week) due to nephrotoxicity. There was marked improvement in anterior inflammation and vitreous organization, but the ME remained exuberant (central ring thickness of 0.7 mm). Over the subsequent 4 years of follow-up, the patient received two intravitreal injections of a dexamethasone extended-release implant (Ozurdex®), with normalization of macular thickness and improvement in visual acuity (VA), but ME recurred around 6 months post-injection. During this period, the patient also underwent three sub-tenon injections of triamcinolone, with marked improvement of ME, but ME recurred between 4 and 6 months after treatment. She was thus recommended for treatment with a fluocinolone extended-release implant (ILUVIEN®). Post-implantation (3-year follow-up), she had controlled anterior inflammation without ME (central macular thickness of 248 μm). This case suggests that sustained control of inflammation enables better control of ME, and benefits may persist even after cessation of the direct anti-inflammatory effect of the implant.

**Enhanced digital features** To view enhanced digital features for this article, go to <https://doi.org/10.6084/m9.figshare.9741737>.

J. Meira (✉) · C. Madeira · F. Falcão-Reis ·  
L. Figueira  
Department of Ophthalmology, Centro Hospitalar  
Universitário de São João, Porto, Portugal  
e-mail: jorgesmeira@gmail.com

F. Falcão-Reis  
Department of Surgery and Physiology, Centro  
Hospitalar Universitário de São João, Porto, Portugal

L. Figueira  
Department of Pharmacology and Therapeutics,  
Faculty of Medicine, University of Porto, Porto,  
Portugal

L. Figueira  
Center for Drug Discovery and Innovative  
Medicines (MedInUP), University of Porto, Porto,  
Portugal

**Funding:** Alimera Sciences Ltd funded the Rapid Service Fees.

**Keywords:** Chronic idiopathic uveitis; Fluocinolone acetonide implant; Intraocular pressure; Macular edema; Visual acuity

## INTRODUCTION

Uveitis is a complex intraocular inflammatory condition affecting the uveal tract (which comprises the iris, the ciliary body and the choroid), as well as the retina, optic nerve and vitreous [1, 2]. Depending on the site of inflammation, uveitis can be classified as anterior, intermediate, posterior or panuveitis [1–3]. Etiology includes infection, autoimmune disease or trauma as well as idiopathic [1, 2]. Uveitis can eventually lead to the development of glaucoma, cataract and/or cystoid macular edema (CME), all of which may result in permanent loss of vision (20%) [4]. The estimated incidence of uveitis has been between 14 and 52 cases per 100,000, with an overall prevalence of 0.73% worldwide [5]. Most affected people are found to be between the ages of 20 and 50 years [5, 6].

Macular edema (ME) is one of the main causes of vision loss in patients with uveitis [2, 7]. It results from a self-amplified pro-inflammatory environment, which ultimately results in the breakdown of the internal blood–retinal barrier and accumulation of fluid in the retina [2, 7]. The degree of visual loss is influenced by the location, severity and duration of ME. The early stages of uveitic ME may be more responsive to treatment than chronic forms.

Corticosteroids (topical or systemic) remain the mainstay treatment for idiopathic uveitis [2, 5]. Other treatments used include intravitreal steroids, systemic carbonic anhydrase inhibitors, anti-VEGF drugs, immunosuppressive drugs, and biologics, mainly anti-tumor necrosis factor-alpha (TNF $\alpha$ ) agents [1–5]. However, chronic systemic therapy with corticosteroids is not devoid of adverse effects, and in situations of idiopathic noninfectious uveitis with corticosteroid-responsive ME, switching to

intraocular therapy may be beneficial in controlling inflammation and ME, without the systemic adverse effects. On the other hand, ME in noninfectious uveitis is characterized by recurrence, thus contributing to chronic external retinal damage and a decrease in the patient's visual potential [8].

An increasing number of sustained-release drug delivery devices have been developed to provide sustained control of inflammation and consequently of ME [9]. The ILUVIEN<sup>®</sup> (fluocinolone acetonide [FAC]) 0.19 mg intravitreal implant received approval in 2012 and 2019 in Europe for the treatment of persistent or recurrent diabetic ME despite prior treatment and for the prevention of relapse in recurrent noninfectious uveitis affecting the posterior segment of the eye. Submissions were based on data from phase III trials in diabetic ME [10–12] and noninfectious uveitis affecting the posterior segment of the eye [13].

The FAC intravitreal implant contains 0.19 mg of fluocinolone acetonide and is designed to release 0.2  $\mu$ g per day for up to 36 months [14].

The current article describes a single case of noninfectious uveitis accompanied by recurrent episodes of ME, and reports the outcomes achieved with the FAC implant after the patient had been treated with prior therapies (i.e. corticosteroids, nonsteroidal anti-inflammatory drugs, immunosuppressants, and intravitreal short-acting steroids). This case was also presented at Sociedad Española de Inflammaci3n Ocular (SEIOO) in 2019.

The case report complies with the guidelines for human studies and was conducted ethically in accordance with the World Medical Association Declaration of Helsinki. The patient was informed of the delicate nature of her ocular condition and she gave her consent to publish this report.

## CASE REPORT

In January 2013, a 54-year-old pseudophakic woman was referred by the internal medicine physician to the ocular inflammation clinic at the ophthalmology department due to

persistent complaints of red eye, poor vision and photophobia in her right eye since 2010. She was a monocular patient, in which the left eye was eviscerated due to trauma and secondary endophthalmitis in 1995. Since 2010, she had reported recurrent episodes of red eye, and was therefore followed by a private ophthalmologist in conjunction with an internist. When sent to our inflammation clinic, she brought with her information provided by the previous ophthalmologist with fluorescein angiography and indocyanine green angiography. Both showed no signs of vascular or choroidal inflammatory activity. She underwent cataract surgery in 2012. She was then treated by the internist with cyclosporine 100 mg/day. The patient did not show any relevant systemic change or history.

### Patient Examination and Diagnosis

Right eye examination, performed in January 2013, revealed a best-corrected visual acuity (BCVA) of 20/200 (35 Early Treatment Diabetic Retinopathy Study [ETDRS] letters), presence of flare and absence of cells in the anterior segment, and an intraocular pressure (IOP) of 11 mmHg, measured by applanation tonometry. The fundus revealed a dense vitreous organization and exuberant CME, as seen on the spectral domain optical coherence tomography (SD-OCT) scans at diagnosis (Fig. 1a). The optic nerve, vasculature and remaining retina were unchanged.

Systemic workup was performed (chest X-ray, Mantoux test, antineutrophil cytoplasmic antibody [ANCA], antinuclear antibody [ANA], angiotensin-converting enzyme, *Treponema pallidum* hemagglutination assay [TPHA]), and the results were negative.

A presumptive diagnosis of idiopathic panuveitis or sympathetic ophthalmia was made.

### Treatment History

Treatment was started with topical dexamethasone 1 mg/ml (five times a day), along with prednisolone 60 mg/day, topical ketorolac 5 mg/ml (three times a day) and cyclosporine

100 mg/day was maintained at this point. After 1 month of treatment, BCVA improved to 20/100, and biomicroscopy showed resolution of anterior inflammation. IOP was 13 mmHg. However, there was persistent vitreous traction, as well as the ME, as seen in the OCT scan 1 month after diagnosis (Fig. 1).

In June 2013, the patient received the first intravitreal injection of a dexamethasone (DEX, Ozurdex<sup>®</sup>) implant, which resulted in normalization of macular thickness and improvement in BCVA, but recurrence of edema was seen within 5 months (Fig. 1).

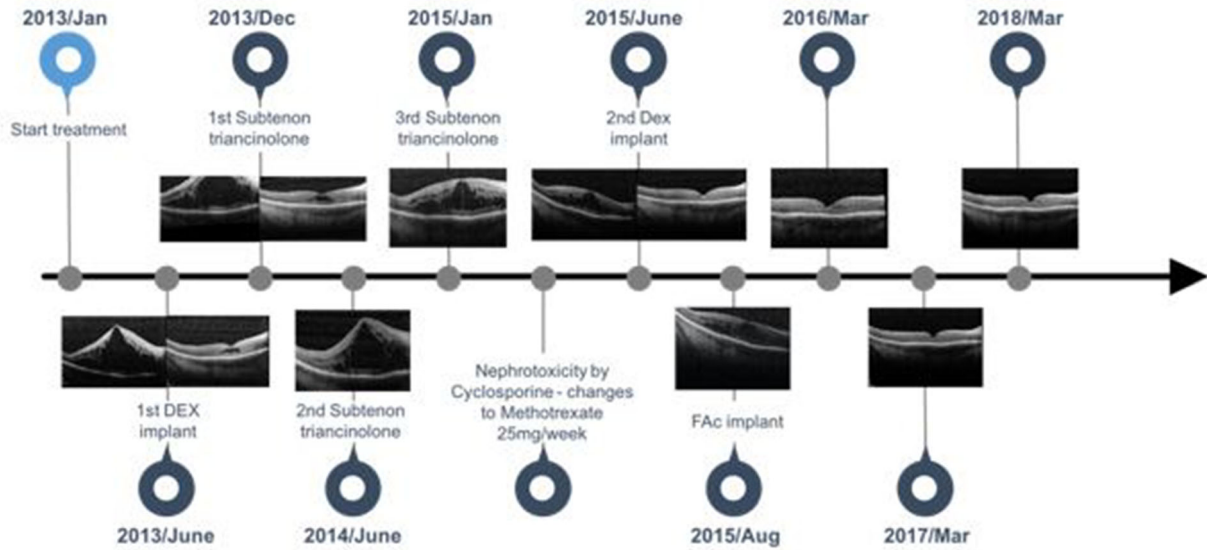
Between December 2013 and January 2015, three sub-tenon injections of triamcinolone were administered before a second DEX implant was injected in June 2015. This time, the effect on ME lasted for only about 3 months (Fig. 1). Treatment with sub-tenon triamcinolone led to a marked improvement and a reduction of ME; however, ME recurred between 4 and 6 months after treatment (Fig. 1).

Because of mounting evidence of kidney damage (increasing serum urea and creatinine) in serial routine blood tests, cyclosporine was stopped and subsequently switched to methotrexate (25 mg/week).

Throughout this period, anterior inflammation and vitreous organization were deemed stable, as well as IOP (between 13 and 15 mmHg) without the need for hypotensive eye drops.

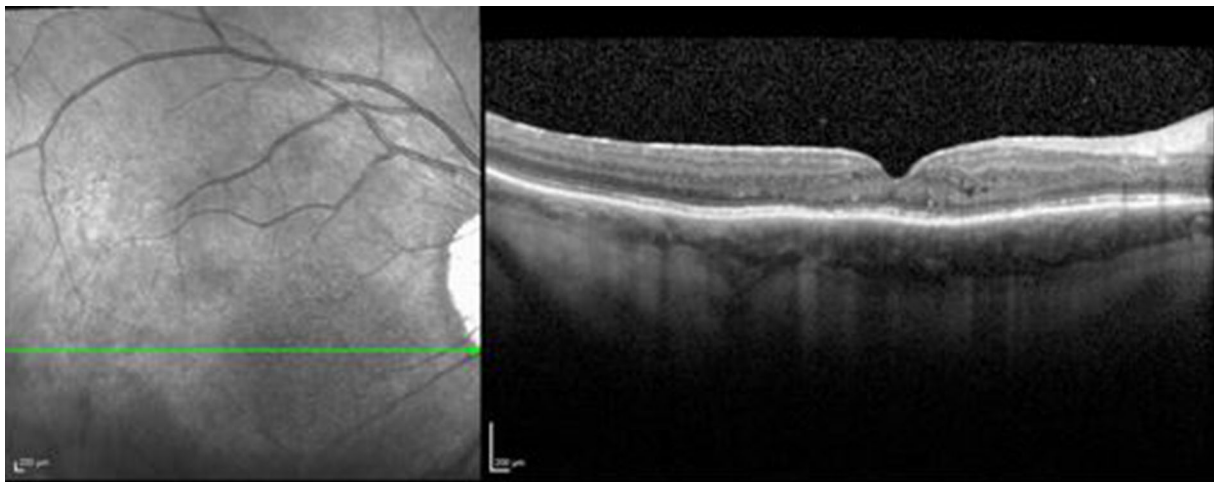
After ME had recurred within 3 months of the second DEX implant, intravitreal injection of a FAc (ILUVIEN<sup>®</sup>) implant was performed in August 2015 that led to a consistent resolution of ME. In January 2019, the patient maintained the initial improvement in BCVA (20/50 or 65 ETDRS letters), with complete resolution of anterior and posterior inflammation. The IOP was 13 mmHg, and fundus examination and OCT scans showed that ME was controlled (248  $\mu$ m central macular thickness, Fig. 2). After FAc implantation, IOP remained between 10 mmHg and 13 mmHg without the need for antihypertensive eye drops.

Prednisolone was tapered from the initial 60 mg/day to a maintenance dose of 5 mg/day until March 2016, when it was completely stopped.



**Fig. 1** Chronological evolution of macular edema during treatment. Isolated images correspond to macular edema immediately before treatment. Double images correspond

to macular edema immediately before and after treatment. *CME* central macular thickness, *DEX* dexamethasone, *FAc* fluocinolone acetonide



**Fig. 2** OCT scan of the patient's right eye showing complete resolution of inflammation following the administration of FAc implant. *FAc* fluocinolone acetonide, *OCT* optical coherence tomography

The variation in central foveal thickness (CFT) and visual acuity during the follow-up period is shown in Table 1.

## DISCUSSION

Uveitis can potentially be sight-threatening and may recur even upon adequate control of acute inflammation [1–3, 5–7]. This case describes the

effect of the FAc implant after intermittent therapies failed to control edema sustainably. Because structural damage is related to the amount of time ME is present, rapid intervention is important in order to preserve the patient's visual potential at its best [5, 7, 9].

This case demonstrates the usefulness and therapeutic advantage of sustained suppression of inflammation for two main reasons. Firstly, it allows for a long period without disease

**Table 1** Chronological evolution of visual acuity (VA) and central foveal thickness (CFT) during treatment

	CFT pre-treatment	VA pre-treatment	CFT post-treatment	VA post-treatment
June 2013	1290	20/100	282	20/80
Dec 2013	> 941	20/200	312	20/160
June 2014	1250	20/200	260	20/160
Jan 2015	679	20/200	159	20/125
June 2015	588	20/200	179	20/100
Aug 2015	490	20/200	259	20/80
Mar 2016	164	20/63	–	–
Mar 2017	163	20/50	–	–
Mar 2018	153	20/50	–	–

recurrence, and secondly, without the need for retreatment strategies. In the case presented, we observed remission of CME over a period longer than the 36-month expected drug release by the FAc implant. It was possible to control ME beyond the 3 year action of the FAc implant. Based on this fact, it can be speculated that sustained and prolonged control of the inflammatory process by the implant allows for a structural and functional recovery from the damages caused by the inflammatory process and a functional reconstitution of the internal and external blood–retinal barriers.

In Europe, the FAc implants is indicated for the treatment of vision impairment associated with persistent or recurrent diabetic ME despite treatment [10, 11, 15–17]. The implant was recently approved for use in the prevention of relapse in recurrent non-infectious uveitis affecting the posterior segment of the eye. This is based on study data in posterior uveitis that shows the FAc implant can significantly reduce disease recurrence, increase disease-free periods, reduce the area of CME, improve VA and provide sustained benefits in these patients [13, 18, 19]. The implant was seen to improve uveitic ME in most cases, concurrently enabling reduction of systemic and periocular treatment [12, 18]. It has also shown the ability to significantly reduce disease recurrence in patients for up to 36 months while enabling a much longer time to first recurrence as well as lower severity of recurrence in most patients [13, 19]. Thus,

our case report confirms the advantage of the FAc implant in the control of noninfectious uveitic macular edema. The FAc implant is the only long-acting implant that has been designed to dilute a low dose of FAc every day to reduce inflammation and recurrences of uveitis. Because it requires fewer injections than other alternative treatments, it brings additional benefits to the patient with reduced risk of injection-associated adverse events, lower treatment burden, increased adherence and improved disease control [20].

## CONCLUSIONS

Intraocular sustained drug release via implantable devices has shown promising efficacy for ME associated with retinal diseases. This case suggests that close and prolonged control of inflammation can lead to structural regulation and complete resolution of macular edema, and that the FAc implant may be effective for in excess of 3 years.

The control exerted by the FAc implant led to structural improvements and significant gains in VA, thus avoiding the potential damaging effects from uveitis recurrence.

## ACKNOWLEDGEMENTS

**Funding.** The authors declare that this case study did not receive any funding. The Rapid Service Fees were funded by Alimera Sciences Ltd. All the authors had full access to all the data in this case report and take full responsibility for the integrity of the data and the accuracy of the data analysis.

**Authorship.** All named authors meet the International Committee of Medical Journal Editors (ICMJE) criteria for authorship for this article, take responsibility for the integrity of the work as a whole, and have given their approval for this version to be published.

**Medical Writing and/or Editorial Assistance.** Medical writing and editorial assistance for this study was provided by Rhutika Dessai of Prescript Communications, Letchworth Garden City, UK. Support for this assistance was funded by Alimera Sciences Ltd.

**Disclosures.** Jorge Meira, Carolina Madeira, Fernando Falcão-Reis and Luís Figueira have no conflicts of interest to declare.

**Compliance with Ethics Guidelines.** The case report complies with the guidelines for human studies and was conducted ethically in accordance with the World Medical Association Declaration of Helsinki. The patient was informed of the delicate nature of her ocular condition and she gave her consent to publish this report.

**Open Access.** This article is distributed under the terms of the Creative Commons Attribution-NonCommercial 4.0 International License (<http://creativecommons.org/licenses/by-nc/4.0/>), which permits any noncommercial use, distribution, and reproduction in any medium, provided you give appropriate credit to the original author(s) and the source, provide a link to the Creative Commons license, and indicate if changes were made.

## REFERENCES

1. Tsirouki T, Dastiridou A, Symeonidis C, et al. A focus on the epidemiology of uveitis. *Ocul Immunol Inflamm.* 2018;26(1):2–16.
2. Goldhardt R, Rosen BS. Uveitic macular edema: treatment update. *Curr Ophthalmol Rep.* 2016;4(1):30–7.
3. National Institute for Health and Care Excellence (NICE) 2018. Final scope for the appraisal of fluocinolone acetonide ocular implant for treating recurrent non-infectious uveitis. <https://www.nice.org.uk/guidance/gid-ta10368/documents/final-scope>. Accessed 4 Jul 2019
4. Durani OM, Tehrani NN, Marr JE, Moradi P, Stavrou P, Murray PI. Degree, duration, and causes of visual loss in uveitis. *Br J Ophthalmol.* 2004;88(9):1159–62.
5. Koronis S, Stavrakas P, Balidis M, Kozeis N, Tranos PG. Update in treatment of uveitic macular edema. *Drug Des Devel Ther.* 2019;13:667–80.
6. Miserocchi E, Fogliato G, Modorati G, Bandello F. Review on the worldwide epidemiology of uveitis. *Eur J Ophthalmol.* 2013;23(5):705–17.
7. Dick AD. The treatment of chronic uveitic macular oedema. *Br J Ophthalmol.* 1994;78(1):1–2.
8. Nguyen QD, Callanan D, Dugel P, Godfrey DG, Goldstein DA, Wilensky JT. Treating chronic non-infectious posterior segment uveitis: the impact of cumulative damage Proceedings of an expert panel roundtable discussion. *Retina.* 2006;26(8):1–16.
9. Cabrera M, Yeh S, Albin TA. Sustained-release corticosteroid options. *J Ophthalmol.* 2014;2014:164692.
10. Campochiaro PA, Brown DM, Pearson A, et al. Long-term benefit of sustained-delivery fluocinolone acetonide vitreous inserts for diabetic macular edema. *Ophthalmology.* 2011;118(4):626.e2–635.e2.
11. Campochiaro PA, Brown DM, Pearson A, et al. Sustained delivery fluocinolone acetonide vitreous inserts provide benefit for at least 3 years in patients with diabetic macular edema. *Ophthalmology.* 2012;119(10):2125–32.
12. ClinicalTrials.gov Identifier: NCT00344968. Fluocinolone acetonide implant compared to sham injection in patients with diabetic macular edema (FAME).

13. ClinicalTrials.gov Identifier: NCT01694186. Safety and efficacy of an injectable fluocinolone acetonide intravitreal insert.
14. Campochiaro PA, Nguyen QD, Hafiz G, et al. Aqueous levels of fluocinolone acetonide after administration of fluocinolone acetonide inserts or fluocinolone acetonide implants. *Ophthalmology*. 2013;120(3):583–7.
15. National Institute for Health and Care Excellence (NICE) guidelines [TA301]; 2013. <https://www.nice.org.uk/guidance/TA301/chapter/1-Guidance>. Accessed 4 July 2019
16. Alimera Sciences, Inc. ILUVIEN® (fluocinolone acetonide intravitreal implant) 0.19 mg for diabetic macular edema (DME)—product overview. <https://alimerasciences.com/products/iluvien-for-diabetic-macular-edema-dme/>. Accessed 4 July 2019
17. Singh P, Chedid A, Deuchler SK, Kohnen T, Müller M, Koch FH. The efficacy and safety outcomes of the 0.19 mg fluocinolone acetonide implant after prior treatment with the 0.7 mg dexamethasone implant in patients with diabetic macular edema. *Int Med Case Rep J*. 2018;11:265–9.
18. Jaffe GJ, Martin D, Callanan D, Pearson PA, Levy B, Comstock T. Fluocinolone acetonide implant (Retisert) for noninfectious posterior uveitis: thirty-four-week results of a multicenter randomized clinical study. *Ophthalmology*. 2006;113(6):1020–7.
19. Jaffe GJ, Foster CS, Pavesio CE, Paggiarino DA, Riedel GE. Effect of an injectable fluocinolone acetonide insert on recurrence rates in chronic noninfectious uveitis affecting the posterior segment: twelve-month results. *Ophthalmology*. 2019;126(4):601–10.
20. Summary of Product Characteristics for ILUVIEN. <https://www.medicines.org.uk/emc/medicine/27636>. Accessed 4 Jul 2019