

# Comparison of erector spinae plane block and local anaesthetic infiltration of the incision site for postoperative analgesia in percutaneous nephrolithotomy - A randomised parallel-group study

## Address for correspondence:

Dr. Krishna P Ramaraj,  
Clinical Department,  
Hospital Block, Department  
of Anaesthesiology, Sri  
Manakula Vinayagar Medical  
College and Hospital,  
Puducherry - 605 107, India.  
E-mail: drkrishnaprabu@gmail.com

Submitted: 19-Dec-2020

Revised: 08-Jan-2021

Accepted: 14-Apr-2021

Published: 20-May-2021

**Srinivasan Ramachandran, Krishna P Ramaraj, Savitri Velayudhan<sup>1</sup>, Balasubramanian Shanmugam, Sureshkumar Kuppusamy, Suneeth P Lazarus**  
Department of Anaesthesiology, Sri Manakula Vinayagar Medical College and Hospital, <sup>1</sup>Department of Anaesthesiology, Indira Gandhi Medical College and Research Institute, Puducherry, India

## ABSTRACT

**Background and Aims:** Erector spinae plane block (ESPB) has been found effective in providing postoperative analgesia following a myriad of surgeries. This study was designed to evaluate the effectiveness of ultrasonography (USG) guided erector spinae plane block to provide postoperative analgesia following percutaneous nephrolithotomy (PCNL). **Methods:** This was a prospective, double-blinded, randomised parallel-group study conducted in patients undergoing PCNL. Patients in Group C (n = 33) received subcutaneous infiltration of 20 mL of 0.25% bupivacaine at the incision site and Group B (n = 33) received USG guided ESPB with 20 mL of 0.25% bupivacaine postoperatively. Numeric rating scale (NRS) scores were assessed at intervals of 30 min, 60 min, then hourly for six h, followed by four-hourly up to 24 h. The primary objective of the study was to compare postoperative pain relief using the NRS score between the two groups. Secondary objectives were to compare the analgesic requirement and to assess the incidence of complications. Normally distributed data were expressed as mean and standard deviation and analysed using Student's t-test. Data following non-normal distribution were expressed as median and interquartile range and analysed using Mann-Whitney U-test. For categorical data, the Chi-square test was used. **Results:** NRS scores were lower in Group B than Group C. There was significant prolongation in time for first analgesia in Group B (12 h) compared to Group C (30 min). There was a significant reduction in total tramadol consumption at 24 h postoperatively in the ESPB group. **Conclusion:** Ultrasound-guided ESPB is an efficacious analgesic technique with an opioid-sparing effect following PCNL.

**Key words:** Erector spinae plane block, interventional ultrasonography, percutaneous nephrolithotomy, postoperative pain

## Access this article online

Website: [www.ijaweb.org](http://www.ijaweb.org)

DOI: 10.4103/ijja.IJA\_1450\_20

Quick response code



## INTRODUCTION

Percutaneous nephrolithotomy (PCNL) is a minimally invasive surgical technique for treating complicated renal stones. It offers less morbidity, a shorter hospital stay and early recovery after surgery. Pain after PCNL is caused by dilatation of the renal capsule and the parenchymal tract and from the incision of the skin, subcutaneous tissue and muscle layer, and the presence of nephrostomy tube.<sup>[1]</sup> Intense postoperative pain and

This is an open access journal, and articles are distributed under the terms of the Creative Commons Attribution-NonCommercial-ShareAlike 4.0 License, which allows others to remix, tweak, and build upon the work non-commercially, as long as appropriate credit is given and the new creations are licensed under the identical terms.

**For reprints contact:** [WKHLRPMedknow\\_reprints@wolterskluwer.com](mailto:WKHLRPMedknow_reprints@wolterskluwer.com)

**How to cite this article:** Ramachandran S, Ramaraj KP, Velayudhan S, Shanmugam B, Kuppusamy S, Lazarus SP. Comparison of erector spinae plane block and local anaesthetic infiltration at the incision site for postoperative analgesia in percutaneous nephrolithotomy – A randomised parallel-group study. *Indian J Anaesth* 2021;65:398-403.

discomfort necessitate the administration of opioids.<sup>[2]</sup> Providing adequate analgesia is a prerequisite for early recovery.

Currently, there are several systemic analgesics [opioids, non-steroidal anti-inflammatory drugs (NSAIDs)], paracetamol, and regional techniques (subcutaneous infiltration, peritubal infiltration, intercostal nerve block (ICNB), paravertebral block (PVB), epidural analgesia) that have been tried for providing postoperative analgesia.<sup>[2-5]</sup> While NSAIDs can have potential systemic side effects in these patients with possible kidney injury, other regional techniques like epidural and paravertebral blocks can be pretty invasive. Erector spinae plane block (ESPB) is a novel technique with versatile applications. Its use for postoperative analgesia following PCNL has already been documented in case reports.<sup>[6]</sup> Though beneficial, only a few randomised trials prove its efficacy. Hence, this study was designed to compare the efficacy of ultrasonography (USG) guided ESPB with local anaesthetic infiltration at the incision site in providing postoperative analgesia following PCNL. The primary objective of the study was to compare postoperative pain relief using the Numeric rating scale (NRS) score between the two groups. Secondary objectives were to compare the time of the first analgesic requirement, tramadol consumption in 24 h, and the occurrence of complications.

## METHODS

This prospective, double-blinded, randomised parallel-group study was conducted after obtaining approval from the Institute Ethics Committee and was registered in the Clinical Trials Registry-India (Registration No: CTRI/2019/06/019888). After obtaining written informed consent, the study was conducted in sixty-six participants undergoing PCNL under general anaesthesia (GA) between July 2019 to December 2019 in a tertiary care teaching institute. Patients of both genders belonging to the American Society of Anesthesiologists physical status I and II, between 18 to 70 years of age, were included. Exclusion criteria included contraindications to peripheral nerve blocks, body mass index  $>35$  kg/m<sup>2</sup>, uncontrolled co-morbid illnesses, sepsis or bacteraemia, and cognitive disability.

Patients were sorted into two groups of 33 each, Group C (received subcutaneous infiltration at the incision site) and Group B (received ESPB) using a

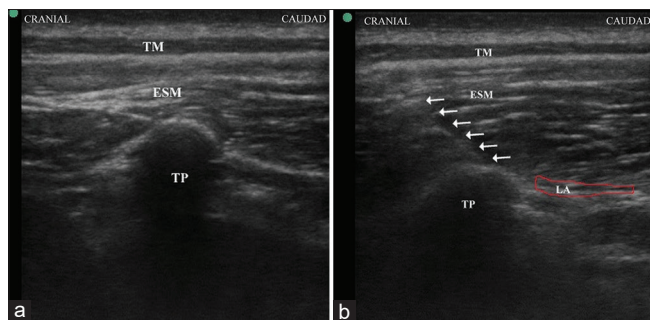
sealed opaque, sequentially numbered envelope for allocation concealment with the help of block (created by an external person) randomisation technique.

All the participants were explained about the procedure and how to respond to the NRS. NRS is an 11-point scale ranging from 0 (no pain) to 10 (worst possible pain) and recorded in whole numbers.<sup>[7]</sup> After ensuring adequate fasting status and written consent, patients were shifted into the operating theatre. Standard monitoring with electrocardiography, non-invasive blood pressure, and pulse oximeter was applied, and baseline readings obtained. The anaesthetic technique and surgical procedure were identical in both groups. An 18-G intravenous (IV) line was secured, and general anaesthesia was administered with IV fentanyl 2 µg/kg, propofol 2 mg/kg, and paralysed with atracurium 0.5 mg/kg. Patients were intubated with an appropriate size endotracheal tube after 3 min of mask ventilation. After confirming the endotracheal tube position, the patients were connected to the anaesthesia workstation. Maintenance of anaesthesia was done using air and oxygen mixture, and isoflurane concentration adjusted to maintain minimum alveolar concentration (MAC) of 1- 1.3. IV dexamethasone 4 mg was administered. Patients were positioned prone for surgery with appropriate padding. Intraoperative tachycardia despite adequate anaesthetic depth and muscle relaxation was treated with IV fentanyl bolus of 0.5 µg/kg. At the end of the procedure, subcutaneous infiltration (20 mL of bupivacaine was infiltrated around the incision site in the subcutaneous plane involving the skin and subcutaneous tissue with a 38 mm 21G hypodermic needle) by the surgeon for participants of Group C. Group B received ESPB at the level of T10. The block was administered by the same investigator, who had three years of experience in USG guided regional anaesthesia and had performed at least 50 ESPBs before the study. The T10 level was identified and marked by counting from above using bony landmarks. A linear (6-13 MHz) ultrasound probe (M-Turbo, Fujifilm Sonosite, Inc., Bothell, WA, USA) was placed in transverse orientation in the midline and T10 spinous process was identified. Then the probe was moved laterally until the transverse process (TP) was visualised on the side of surgery. The probe was rotated 90°, and the sonographic landmarks, including the TP overlying erector spinae muscles and trapezius (thin hypoechoic layer), were identified [Figure 1a]. Under aseptic conditions, an 8 cm 23-gauge Quincke spinal needle (BD™, NJ, USA) was inserted parallel to the USG beam at an angle

of 30–45° in the craniocaudal direction until the tip contacted the corresponding TP. Once the transverse process was contacted, the needle was withdrawn a few millimetres, and 2–3 mL of isotonic saline solution was injected to ascertain the correct plane, following which 20 mL of 0.25% bupivacaine was injected between the TP and erector spinae muscle [Figure 1b].

Dynamic local anaesthetic spread in a longitudinal pattern (2-3 segments above and below the T10 level) deep to the erector spinae muscle was visualised using sonographic guidance. Then the patient was turned supine and extubated. After extubation, NRS scores were assessed at intervals of 30 min, 60 min, then hourly for 6 hours followed four-hourly up to 24 h postoperatively by an independent observer who was blind to the group assignment. If the NRS score was  $\geq 4$ , tramadol 50 mg IV was given. If the pain persisted (NRS  $\geq 4$ ) after 30 min of tramadol administration, paracetamol 1 gram IV was administered as the second analgesic. The NRS scores were further assessed according to the timeline given in the protocol. The tramadol and paracetamol doses were re-administered if NRS  $\geq 4$  after 6 h of the previous administration. If a NRS score of  $\geq 4$  was recorded in the intervening period, IV fentanyl bolus (0.5  $\mu\text{g}/\text{kg}$ ) was administered. The patients were monitored for complications during block performance and postoperatively (local anaesthetic toxicity, pneumothorax, nausea, vomiting). Patients who had nausea and vomiting were treated with ondansetron 4 mg IV.

The sample size was calculated to be 66 (33 in each group) using the software OpenEpi version 3.0 taking into consideration an assumed 33% reduction in postoperative pain scores, based on the NRS between the two groups at 4 h with 95% confidence interval,



**Figure 1:** (a) Sonographic landmarks at the level of T10. (b) Image showing needle advancement towards transverse process and local anaesthetic spread below erector spinae muscle. (TM- Trapezius muscle, ESM- Erector spinae muscle, TP- Transverse process. LA- Local anaesthetic, arrows indicate needle path)

80% power and 1:1 ratio of allocation. The Shapiro Wilk test was used to check normality. Data were expressed as mean and standard deviation (SD) and analysed using Student’s t-test when they followed a normal distribution. Data following non-normal distribution were expressed as median and interquartile range (IQR) and analysed using the Mann-Whitney U-test. For categorical data, the Chi-square test was used. The data were analysed using Statistical Package for the Social Sciences (SPSS version 24.0, Chicago, Illinois). A *P* value less than 0.05 was considered statistically significant.

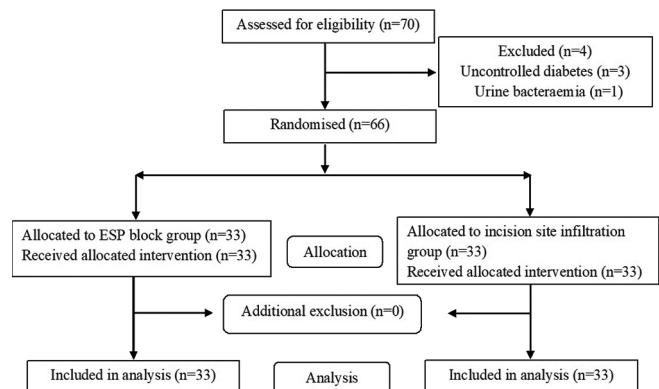
**RESULTS**

The patient flow is summarised in the CONSORT diagram [Figure 2]. There were no significant differences in the patients’ baseline features, duration of surgery and intraoperative fentanyl consumption in both groups [Table 1]. NRS scores were statistically lesser in Group B than Group C for up to 8 h (*p* = 0.000) [Table 2]. The median time for first analgesia in Group C was 30 min, and in Group B was 12 h, which was statistically significant. The

**Table 1: Baseline Characteristics of the Patients and Intraoperative Parameters**

	Group B (n=33)	Group C (n=33)	P
Sex (Male/Female), n	22/11	24/9	0.592
Age, years*	46.64±13.5	44.15±14.5	0.475
Height, m*	1.62±0.08	1.62±0.08	0.888
Weight, kg*	62.15±8.8	64.03±8.8	0.392
BMI, kg/m <sup>2</sup> *	23.83±3.94	24.38±3.43	0.548
ASA (I/II), n	17/16	20/13	0.457
Duration of surgery, min*	77.84±11.04	79.36±11.7	0.591
Intraoperative Fentanyl consumption, $\mu\text{g}^\dagger$	120 (105-135)	120 (120-140)	0.159

Data presented as \*mean±SD, number of patients, †median (IQR), BMI - Body Mass Index, ASA - American Society of Anesthesiologists, SD - Standard Deviation, IQR - Inter quartile range.



**Figure 2:** CONSORT flow diagram

total (median) tramadol and paracetamol consumption at 24 h postoperatively were significantly lower in Group B compared to Group C ( $p = 0.000$ ) [Table 3]. No patients belonging to either group needed additional analgesia. In all the patients, the block was performed successfully without complications. Postoperatively, three patients belonging to Group C and four patients in Group B had nausea; two patients in Group C and one patient belonging to Group B had vomiting. However, it was not statistically significant.

## DISCUSSION

We compared ESPB with local anaesthetic infiltration at the incision site for postoperative analgesia following PCNL. We found that patients receiving the block had significantly lower NRS scores, longer duration to first analgesic requirement and significantly lower opioid consumption.

Pain following PCNL is conducted through T10 to L2 nerves.<sup>[8]</sup> Complete analgesia can be provided by unilateral blockade of these nerves. ESPB, a myofascial plane block, is less invasive and is relatively safe because of the lack of vascular and other significant structures in the vicinity and because the end-point of needle contact is a bony landmark. All patients randomised to the block group successfully received

the block in this study. In a review of the ESPB by De Cassai *et al.*,<sup>[9]</sup> it was concluded that the median volume required to cover one dermatome would be 3.4 mL. In the case report by Kim *et al.*,<sup>[6]</sup> 20 mL of 0.375% ropivacaine was administered for the ESPB and was found to provide adequate postoperative analgesia after PCNL. Based on these findings, 0.25% bupivacaine 20 mL was administered at the level of T10, and adequate pain relief was achieved for both subcostal and supracostal access for the surgery.

ESPB has been used in various contexts like in the emergency room for analgesia following rib fractures, intraoperative and postoperative analgesia following laparotomy, laparoscopic cholecystectomy, breast surgery, scapula resection, thoracotomy, sternotomy and chronic pain.<sup>[7,10-16]</sup> Though the mechanism of action is still not fully understood, it has been demonstrated in cadaveric and *in vivo* studies that one of the prime mechanisms is by drug penetration into the paravertebral region.<sup>[17-19]</sup> A study by Ivanusic *et al.*,<sup>[20]</sup> failed to demonstrate any spread into the paravertebral space.

In a case report, wherein the authors studied the efficacy of ESPB for renal colic, it was found that ESPB provided adequate analgesia [VAS (Visual analogue scale) scores of 0/10, 2/10, and 2/10] with no further need for analgesia up to 8-10 h.<sup>[21]</sup> In a case series where ESPB with GA was evaluated for analgesia following PCNL, the authors found that VAS scores remained less than 3 for 24 h postoperatively with almost no additional analgesic requirement.<sup>[22]</sup> Only one patient out of 5 had a VAS score of 6 and required a single dose of tramadol in the entire study period. The block was performed at T10, T11 and T12 levels using 20 mL of 0.375% ropivacaine with 25 µg dexmedetomidine.

In a study by Ibrahim *et al.*,<sup>[23]</sup> the efficacy of ESPB for intraoperative and postoperative analgesia for PCNL was evaluated. The block was performed preoperatively at the level of T11, and 30 mL of 0.5% bupivacaine was injected. It produced lower intraoperative fentanyl consumption, reduced postoperative pain

**Table 2: Postoperative Numeric Rating Scale (NRS) Score Over 24 h**

Time	Group B (n=33)	Group C (n=33)	P
30 min	3 (2-3)	5 (3-7)	0.000*
1 h	2 (0-2)	5 (4-5)	0.000*
2 h	2 (0-2)	3 (2.5-3.5)	0.000*
3 h	0 (0-2)	3 (2-3)	0.000*
4 h	0 (0-2)	3 (2-3)	0.000*
5 h	0 (0-2)	3 (2-3)	0.000*
6 h	2 (0-2)	3 (2-3)	0.000*
8 h	2 (2-3)	5 (4-5)	0.000*
12 h	4 (3-4)	3 (2-4.5)	0.171
16 h	3 (3-3)	3 (3-4)	0.155
20 h	3 (3-4)	3 (3-4)	0.270
24 h	3 (2-3)	3 (3-3)	0.293

Data presented as median (interquartile range); Median compared using Mann-Whitney U-test; \* $P < 0.05$

**Table 3: Postoperative Analgesia Requirement**

Parameter	Group B (n=33)	Group C (n=33)	P
Time to first rescue analgesia, h*	12 (12-12)	0.5 (0.5-1)	0.000‡
Total tramadol requirement in 24 h, mg*	100 (50-100)	150 (100-150)	0.000‡
Number of patients requiring second analgesia, n (%)†	19 (57)	33 (100)	0.000‡
Total paracetamol requirement in 24 h, g*	1 (0-1)	2 (2-2)	0.000‡

Data presented as \*median (interquartile range) or †number of patients (percentage), Median compared using Mann-Whitney U-test and proportions compared using Chi-square test. ‡ $P < 0.05$



score, longer time to first analgesia and lower opioid consumption postoperatively. Glutekin MH *et al.*,<sup>[24]</sup> evaluated ESPB for analgesia following PCNL by performing the block at T8 level using 20 mL of 0.5% bupivacaine and obtained similar results. In the current study, though there was a significant reduction in postoperative opioid consumption, the intraoperative consumption was comparable. In another study wherein fluoroscopy-guided ESPB for postoperative analgesia following PCNL was evaluated, the results were similar.<sup>[25]</sup> However, we gave the block under USG guidance, and this offers better accuracy and safety.

In the current study, the patients receiving the ESPB had lower NRS scores which is identical to the results obtained in the three randomised controlled trials (RCTs), which assessed ESP block for analgesia following PCNL.<sup>[23-25]</sup> Although the patients were permitted movements as was possible, the NRS scores were assessed with the patient at rest. Dynamic analgesia scores were not assessed in any of the studies; these would have been more valuable to assess the early recovery profile.

Duration of analgesia following ESPB has been assessed in multiple studies with a vast extent of 6 h up to 24 h<sup>[9]</sup> In our study, NRS scores were significantly less up to 8 h, and the median time for first analgesic requirement was 12 h. There is a wide variation in the time to first analgesic requisite in the three studies evaluating ESP for analgesia following PCNL.<sup>[23-25]</sup> In the studies by Ibrahim *et al.*,<sup>[23]</sup> and Gultekin *et al.*,<sup>[24]</sup> the mean time to first analgesia was 166.6 min and  $172.33 \pm 180.5$  min, respectively. This discrepancy could be because the block was performed preoperatively in those studies, shortening the postoperative duration. In the study by Prasad MK *et al.*,<sup>[25]</sup> and the case series by Kumar *et al.*,<sup>[22]</sup> a similar prolonged duration to first analgesia was observed. RCTs with an identical study design or a possible systematic review on this topic could throw more light on the exact duration of ESPB.

In a meta-analysis published on the effectiveness of ESPB for postoperative analgesia, despite the heterogeneity of the surgeries, the common finding was a significant reduction in opioid consumption.<sup>[26]</sup> The findings of the current study reiterate the same. The prolonged duration of action combined with a reduced opioid requirement makes ESPB an intrinsic part of multimodal analgesia, essential for enhanced recovery programmes. None of the studies included

in the meta-analysis was powered enough to comment on the block's safety.<sup>[26]</sup> There have been two reports of pneumothoraces and one report of the unintended motor block following ESPB.<sup>[27-29]</sup> Recently, Missair *et al.*,<sup>[30]</sup> hypothesised about the possibility of spinal instability following ESPB by multiple mechanisms which disrupt the active and passive spinal stabilising systems. Closer scrutinisation of the patients receiving ESPB can provide more insight into this complication. Though there were no complications relating to the ESPB in this study, it was not powered enough to conclude on the block's safety.

Our study had several limitations. Dermatome levels following the ESPB block are still being studied extensively. We could not provide that information in this study as the block was given after surgery under general anaesthesia, and the excessive movements required for formal sensory assessments would have resulted in spuriously high at-rest NRS scores. We did not assess dynamic NRS scores. The control group in our study received incision site infiltration, which was the conventional analgesia used in our institute following PCNL, instead of a sham block, as it was unacceptable for the institute ethics committee to deny the study participants the conventional analgesic technique. The use of patient-controlled analgesia would have enabled us to determine opioid consumption more accurately; nevertheless, we recommend further research wherein ESPB can be compared with other regional anaesthesia techniques in terms of safety and efficacy, dermatomes that are blocked can be mapped to provide further insight. Research is also needed to determine the use of additives in this block.

## CONCLUSION

We conclude on the basis of our study that USG guided ESPB is a technique that can provide adequate analgesia and has an opioid-sparing effect following PCNL.

### Declaration of patient consent

The authors certify that they have obtained all appropriate patient consent forms. In the form the patient(s) has/have given his/her/their consent for his/her/their images and other clinical information to be reported in the journal. The patients understand that their names and initials will not be published and due efforts will be made to conceal their identity, but anonymity cannot be guaranteed.

## Acknowledgement

We sincerely thank Dr. Vinayagamoorthy V, Epidemiology Unit of Community Medicine Department, for guiding us in designing the study and with statistical analysis.

## Financial support and sponsorship

Nil.

## Conflicts of interest

There are no conflicts of interest.

## REFERENCES

- Wang J, Zhang C, Tan D, Tan G, Yang B, Chen W, *et al.* The effect of local anesthetic infiltration around nephrostomy tract on postoperative pain control after percutaneous nephrolithotomy: A systematic review and meta-analysis. *Urol Int* 2016;97:125-33.
- Parikh GP, Shah VR, Vora KS, Parikh BK, Modi MP, Kumari P. Ultrasound guided peritubal infiltration of 0.25% Bupivacaine versus 0.25% Ropivacaine for postoperative pain relief after percutaneous nephrolithotomy: A prospective double blind randomised study. *Indian J Anaesth* 2014;58:293-7.
- Jonnvithula N, Chirra RR, Pasupuleti SL, Devraj R, Sriramoju V, Pisapati MV. A comparison of the efficacy of intercostal nerve block and peritubal infiltration of ropivacaine for postoperative analgesia following percutaneous nephrolithotomy: A prospective randomised double-blind study. *Indian J Anaesth* 2017;61:655-60.
- Hatipoglu Z, Gulec E, Turkcan M, Izol V, Aridogan A, Gunes Y, *et al.* Comparative study of ultrasound-guided paravertebral block versus intravenous tramadol for postoperative pain control in percutaneous nephrolithotomy. *BMC Anesthesiol* 2018;18:24.
- Parikh DA, Patkar GA, Ganvir MS, Sawant A, Tendolkar BA. Is segmental epidural anaesthesia an optimal technique for patients undergoing percutaneous nephrolithotomy? *Indian J Anaesth* 2017;61:308-14.
- Kim E, Kwon W, Oh S, Bang S. The erector spinae plane block for postoperative analgesia after percutaneous nephrolithotomy. *Chin Med J (Engl)* 2018;131:1877-8.
- Tulgar S, Kapakli MS, Senturk O, Selvi O, Serifsoy TE, Ozer Z. Evaluation of ultrasound-guided erector spinae plane block for postoperative analgesia in laparoscopic cholecystectomy: A prospective, randomized, controlled clinical trial. *J Clin Anesth* 2018;49:101-6.
- Malhotra V, Sudheendra V, O'Hara J, Malhotra A. Anesthesia and the renal and genitourinary systems. In: Miller RD, Eriksson LI, Fleisher LA, Wiener-Kronish JP, Young WL, editors. *Miller's Anesthesia*. 8<sup>th</sup> ed.. Philadelphia: Elsevier Saunders; 2015. p. 2217-43.
- De Cassai A, Bonvicini D, Correale C, Sandei L, Tulgar S, Tonetti T. Erector spinae plane block: A systematic qualitative review. *Minerva Anesthesiol* 2019;85:308-19.
- Diwan S, Nair A. Unilateral erector spinae plane block for managing acute pain arising from multiple unilateral injuries: A case report. *Indian J Anaesth* 2020;64:79-80.
- Restrepo-Garcés CE, Chin KJ, Suarez P, Diaz A. Bilateral continuous erector spinae plane block contributes to effective postoperative analgesia after major open abdominal surgery: A case report. *A A Case Rep* 2017;9:319-21.
- Malawat A, Jethava D, Sachdev S, Jethava DD. Erector spinae plane block for breast oncological procedure as a surrogate to general anaesthesia: A retrospective study. *Indian J Anaesth* 2020;64:328-33.
- Syal R, Vaishnavi BD, Kumar R, Kamal M. Utility of erector spinae plane block in a complex scapular resection. *Indian J Anaesth* 2020;64:731-3.
- Fang B, Wang Z, Huang X. Ultrasound-guided preoperative single-dose erector spinae plane block provides comparable analgesia to thoracic paravertebral block following thoracotomy: A single center randomized controlled double-blind study. *Ann Transl Med* 2019;7:174.
- Krishna SN, Chauhan S, Bhoi D, Kaushal B, Hasija S, Sangdup T, *et al.* Bilateral erector spinae plane block for acute post-surgical pain in adult cardiac surgical patients: A randomized controlled trial. *J Cardiothorac Vasc Anesth* 2019;33:368-75.
- Forero M, Adhikary SD, Lopez H, Tsui C, Chin KJ. The erector Spinae plane block: A novel analgesic technique in thoracic neuropathic pain. *Reg Anesth Pain Med* 2016;41:621-7.
- Diwan S, Garud R, Nair A. Thoracic paravertebral and erector spinae plane block: A cadaveric study demonstrating different site of injections and similar destinations. *Saudi J Anaesth* 2019;13:399-401.
- Ueshima H, Hiroshi O. Spread of local anesthetic solution in the erector spinae plane block. *J Clin Anesth* 2018;45:23.
- Schwartzmann A, Peng P, Maciel MA, Forero M. Mechanism of the erector spinae plane block: Insights from a magnetic resonance imaging study. *Can J Anaesth* 2018;65:1165-6.
- Ivanusic J, Konishi Y, Barrington MJ. A cadaveric study investigating the mechanism of action of erector spinae blockade. *Reg Anesth Pain Med* 2018;43:567-71.
- Aydin ME, Ahiskalioglu A, Tekin E, Ozkaya F, Ahiskalioglu EO, Bayramoglu A. Relief of refractory renal colic in emergency department: A novel indication for ultrasound guided erector spinae plane block. *Am J Emerg Med* 2019;37:794.e1-3.
- Kumar GSS, Balakundi P, Deo A. ESRA19-0663 A new indication of erector spinae plane block for perioperative analgesia is percutaneous nephrolithotomy (PCNL) surgery: Case series. *Reg Anesth Pain Med* 2019;44:A254-5.
- Ibrahim M, Elnabtity AM. Analgesic efficacy of erector spinae plane block in percutaneous nephrolithotomy. *Anaesthesist* 2019;68:755-61.
- Gultekin MH, Erdogan A, Akyol F. Evaluation of the efficacy of the erector spinae plane block for postoperative pain in patients undergoing percutaneous nephrolithotomy: A randomized controlled trial. *J Endourol* 2020;34:267-72.
- Prasad MK, Varshney RK, Jain P, Choudhary AK, Khare A, Jheetay GS. Postoperative analgesic efficacy of fluoroscopy-guided erector spinae plane block after percutaneous nephrolithotomy (PCNL): A randomized controlled study. *Saudi J Anaesth* 2020;14:480-6.
- Huang J, Liu JC. Ultrasound-guided erector spinae plane block for postoperative analgesia: A meta-analysis of randomized controlled trials. *BMC Anesthesiol* 2020;20:83.
- Ueshima H. Pneumothorax after the erector spinae plane block. *J Clin Anesth* 2018;48:12.
- Hamilton DL. Pneumothorax following erector spinae plane block. *J Clin Anesth* 2019;52:17.
- Selvi O, Tulgar S. Ultrasound-guided erector spinae plane block as a cause of unintended motor block. *Rev Esp Anesthesiol Reanim* 2018;65:589-92.
- Missair A, Flavin K, Paula F, Benedetti de Marrero E, Benitez Lopez J, Matadial C. Leaning tower of Pisa? Avoiding a major neurologic complication with the erector spinae plane block. *Reg Anesth Pain Med* 2019;44:713-4.