

Scrotoscopy exploration of testicular rupture

A pilot study

Yongbao Wei, MD^{a,b}, Jinrui Yang, PhD^c, Huaishan Hong, MD^{a,b}, Yunliang Gao, MD^c, Jinfeng Wu, MD^{a,b}, Xiang Wu, MD^{a,b}, Ruochen Zhang, MD^{a,b}, Le Lin, MD^{a,b}, Tao Li, MD^{a,b}, Fengguang Yang, MD^{a,b}, Liefu Ye, PhD^{a,b}, Qingguo Zhu, PhD^{a,b,*}

Abstract

To examine whether scrotoscopy could be used to diagnose testicular rupture (TR) with accuracy.

This retrospective study included all patients receiving scrotoscopy followed by immediate open exploration (OE) for suspected TR at two Chinese tertiary care centers between March 2014 and March 2018.

Fifteen patients suspected of having TR were included. TR was considered in 8 patients (8/15) *via* emergency scrotal ultrasound (ESU) examination. Of these 8 patients, 6 cases as well as 3 other cases, a total of 9 cases (9/15) were confirmed TR by scrotoscopy and OE; the remaining 6 patients (6/15) were found disease free. The presence/absence of TR was identified correctly with scrotoscopy in all 15 cases. The rupture size of the testicular tunica albuginea (TTA) varied from 0.5 to 2 cm. Only 3 cases (3/15) had scrotal wall edema and all quickly recovered. The testis was normal in size and blood flow at 6-month follow-up visit.

Scrotoscopy accurately diagnoses TR, and may avoid unnecessary OE, especially for the patients confirmed free of disease.

Abbreviations: ESU = Emergency scrotal ultrasound, OE = open exploration, TR = testicular rupture, TTA = testicular tunica albuginea.

Keywords: emergency ultrasound, minimally invasive surgery, Scrotoscopy, testicular rupture

1. Introduction

TR is a medical emergency that requires immediate repair.^[1] ESU is the preferred auxiliary examination in patients suspected of TR. Open surgical exploration and repair is the standard protocol in patients with definite or suspected testicular contusion or rupture.^[2] However, this traditional surgical

procedure is invasive, and may cause chronic scrotal pain or discomfort after surgery.^[3,4]

Recently, scrotoscopy has been increasingly used to manage a variety of conditions, including vaginectomy and epididymal cystectomy as well as diagnosis of testicular torsion.^[5–8] Scrotoscopy is a minimally invasive approach for managing scrotal diseases by allowing direct observation of intra-scrotal lesions. In the present retrospective case series from two tertiary care centers in China, we report on the diagnostic accuracy and surgical outcome of a minimally invasive approach *via* scrotoscopy for diagnosing TR followed by surgical exploration.

2. Patients and methods

2.1. Patients

This retrospective case series included patients who underwent OE for suspected TR at Fujian Provincial Hospital, Fuzhou, Fujian, China and the Second Xiangya Hospital, Changsha, Hunan, China between March 2014 and March 2018. Patients who underwent scrotoscopy were included. We excluded patients with other diseases in the scrotum, testis or epididymis, such as acute infection, communicating hydrocele, or tuberculosis of the epididymis of the testis. Patients with open wound on the scrotum or with a history of surgery ipsilateral to the lesion were also excluded. Before surgery, all patients had accepted color Doppler ultrasound examination (color Doppler ultrasound system: PhilipsIU, #22, US, or ALOKA, #α10, Japan; Probe frequency range: 5–17 MHz) by two experienced radiologists (both of them had worked in ultrasound examination for over 5 years).

The study was approved by the local Ethics Committee of the two participating centers (No.Y-20140307, the Second Xiangya Hospital, March 2014; No.2016-K-01-03, Fujian Provincial

Editor: Apul Goel.

WY and JY contributed equally to this work.

The authors have no conflicts of interest to disclose.

The research involves human participants and the study was approved from by the ethics committee of the corresponding author's center. The methods were performed in accordance with the ethical standards of the institutional and/or national research committee and with the 1964 Helsinki declaration and its later amendments or comparable ethical standards.

Written informed consent was all obtained from all parents.

^a Shengli Clinical Medical College of Fujian Medical University, ^b Department of Urology, Fujian Provincial Hospital, Fuzhou, ^c Department of Urology, The Second Xiangya Hospital, Central South University, Changsha, China.

* Correspondence: Qingguo Zhu, Provincial Clinical Medical College of Fujian Medical University, Fuzhou 350001, China (e-mail: zqg_1969@126.com).

Copyright © 2019 the Author(s). Published by Wolters Kluwer Health, Inc. This is an open access article distributed under the terms of the Creative Commons Attribution-Non Commercial-No Derivatives License 4.0 (CCBY-NC-ND), where it is permissible to download and share the work provided it is properly cited. The work cannot be changed in any way or used commercially without permission from the journal.

How to cite this article: Wei Y, Yang J, Hong H, Gao Y, Wu J, Wu X, Zhang R, Lin L, Li T, Yang F, Ye L, Zhu Q. Scrotoscopy exploration of testicular rupture. *Medicine* 2019;98:41(e17389).

Received: 10 June 2019 / Received in final form: 28 August 2019 / Accepted: 6 September 2019

<http://dx.doi.org/10.1097/MD.00000000000017389>

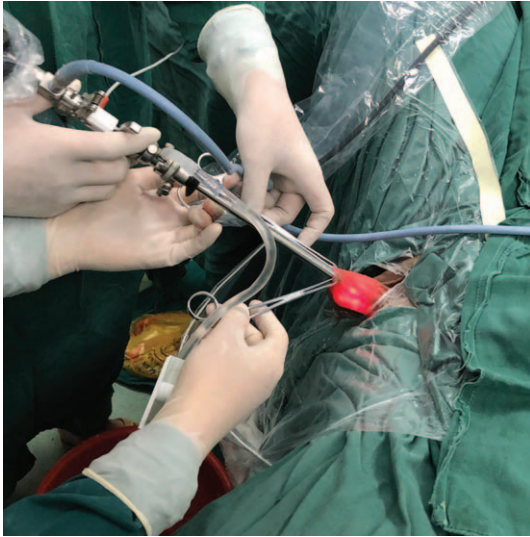


Figure 1. The patient is placed in a lithotomy position. the main procedure is as follows: after a 1-cm incision was made in the anterior scrotal wall, two Allis clamps are used to clamp the entire layer of the wall along the incision, then the scrotoscope is inserted testicular vaginal cavity and it offers a panoramic view of the scrotal contents.

Hospital, January 2016). Informed consent for surgery was obtained from all patients. No consent was required for the study because of its retrospective nature. Patient data were anonymized in this report.

2.2. Scrotoscopy

Intravenous prophylactic cephalosporins or quinolones were administered 30 min to 2 h before surgery. Scrotoscopy was conducted using either Fr 17-Fr 22 Storz (Tuttlingen, Germany) cystoscope or Fr 26 Olympus (Tokyo, Japan) plasma resectoscope under epidural, spinal or general anesthesia, or *via* spermatic cord seal-up injection with local infiltration anesthesia. Briefly, the patient was placed in a lithotomy position. Perfusion/

irrigation was carried out using sterile saline at 60–80 cm H₂O pressure in a continuous low-flow maintenance mode. A 1-cm incision was made in the anterior scrotal wall. Upon reaching the perididymis, bloody turbid liquid was released. Two Allis clamps were used to clamp the entire layer of the wall along the incision. The scrotoscope was then inserted (Fig. 1). The testicular vaginal cavity was thoroughly irrigated and repeatedly flushed with sterile saline to allow for a clear view. The testis, epididymis, the gubernaculum testis, the testicular vaginal cavity, and the sheath surface of the spermatic cord were carefully inspected. Upon completion of examination, the scrotoscope was withdrawn.

2.3. Surgery

Surgery was performed by two surgeons who had at least 3 years of experience in scrotoscopy surgery. The incision for scrotoscopy was extended during OE and repair. The testicles were pulled out of the scrotal incision. For patients with confirmed TR, the TTA was repaired. Then, the incision was closed. For patients with no TR, the incision was closed immediately. A rubber drainage plate was placed postoperatively, which was removed within 24 to 48 h postoperatively. All patients underwent postoperative prophylactic intravenous antibiotics for 24 to 72 h. The patients were followed up after discharge from the hospital.

3. Results

3.1. Patient demographic and baseline characteristics

In total, 15 patients (age: 18–36 years) underwent scrotoscopy followed by OE. Patient demographic and baseline are shown in Table 1. Fourteen patients had a history of trauma and the median duration from injury to treatment was 3 h (range 1.5–9 h). Five patients accepted spermatic cord seal-up injection with local infiltration anesthesia. Routine ESU diagnosed TR in 8 patients (8/15).

3.2. Outcome of scrotoscopy and OE/repair

The median duration of scrotoscopy was 8 min (range 5–13 min). Six of 8 cases of TR identified by ESU were confirmed by

Table 1
Diagnostic outcome of ESU, scrotoscopy and OE in 15 patients with suspected TR.

Case No.	Age (years)	Manifestations	ESU	Scrotoscopy	OE	Complications
1	21	Pain, swelling	–	+	+	/
2	28	Pain, bruise, scratches and swelling	+	+	+	/
3	23	Pain, bruise	+	+	+	Edema
4	27	Pain, scratches	–	–	–	/
5	31	Pain, bruise	+	–	–	/
6	18	Pain, swelling	–	+	+	Edema
7	24	Pain, scratches	–	–	–	/
8	29	Pain, bruise	+	+	+	/
9	33	Pain, bruise and swelling	+	+	+	/
10	25	Pain, scratches & swelling	–	–	–	/
11	34	Pain, swelling	+	+	+	/
12	31	Pain, bruise	+	–	–	Edema
13	36	Pain, scratches and swelling	–	+	+	/
14	26	Pain, bruise	–	–	–	/
15	32	Pain, swelling	+	+	+	/

–, Hematoma in the cavity of the perididymis, and/or testicular contusion.

+, TR, accompanied with hematoma in the cavity of perididymis, and/or testicular contusion.

ESU=emergency scrotal ultrasound, OE=open exploration, TR=testicular rupture.

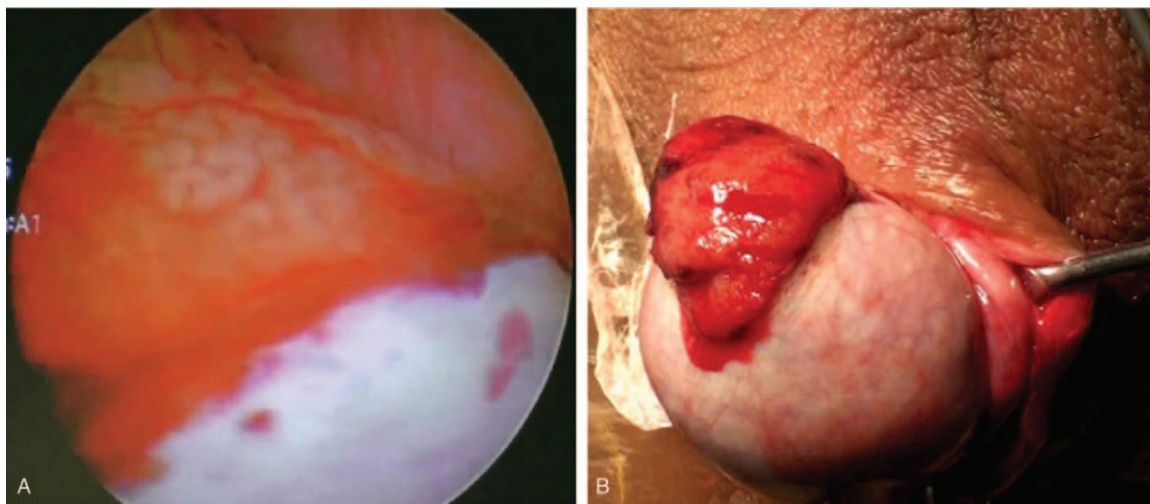


Figure 2. Scrotoscopic and OE findings of TR. (A) The TTA is discontinuous and small seminiferous tubules spill out of the testicular laceration. TR is confirmed by scrotoscope. (B) Features of TR under the scrotoscope are confirmed by OE.

scrotoscopy. Furthermore, scrotoscopy identified 3 additional cases of TR which ESU failed to diagnose.

The median duration of OE and/or repair was 26 min (range 15–35 min). The length of incision of OE ranged between 2.5 and 4.5 cm. OE confirmed all 9 cases of TR identified by scrotoscopy. The TR was unilateral in all 9 patients and on the left in 4 patients, and on the right in 5 patients. Rupture of the TTA was characterized by a small, bloody clot; seminiferous tubules were observed spilling out of the testicular laceration after blood clot was removed (Fig. 2). The rupture size of the TTA varied from 0.5 to 2 cm.

3.3. Complications

Three (3/15) cases had scrotal wall edema and all quickly recovered without specific treatment. Ultrasonography revealed that the testis and epididymis were normal in size and blood flow at 6 months of follow-up. No other remarkable abnormality was present.

4. Discussion

TR is a common consequence of scrotal trauma, resulting from motor vehicle accidents, sports injury, blunt injury, avulsion, and electrical burn injury.^[9] Regardless its causes, ESU is a routine procedure in cases of suspected TR. Typical signs of TR or testicular contusion under ESU include irregular testicular contours and disordered testicular parenchyma.^[10,11] Occasionally, testicular tissue protruding from the tunica could be seen under ultrasound.^[10,11] Furthermore, ESU could reveal testicular blood supply and discriminate TR from testicular torsion or inflammation.^[10,11] Ultrasound has high sensitivity (93–100%), but lacks specificity (65–83%) in diagnosing TR.^[10,11] Ultrasound could also be used to diagnose TR with penetrating trauma. In patients with a gunshot wound, the sensitivity of ultrasound in diagnosing TR was very low (60%), even though its specificity was as high as 95%.^[12] Thus, ultrasound diagnosis of TR still has obvious deficiency, and many cases of TR are still misdiagnosed as TR often presents with scrotal wall swelling, scrotal hematoma and other findings mimicking TR, its severity

becomes very difficult to be assessed.^[8,10–14] In some difficult cases, other imaging techniques, such as CT or MRI, may be necessary^[14,15]; however, this may delay the best time of treatment; furthermore, in underdeveloped countries or regions, the application of these auxiliary examinations is usually not immediately available.

A misdiagnosis and/or delayed treatment, as well as intended conservative treatment may lead to serious complications, such as infection, testicular ischemia and necrosis and delayed testicular resection.^[8,10,12,16] Therefore, a rapid, effective and minimally invasive diagnostic method like scrotoscopy may offer an alternative technique. In the present study, all 15 patients with suspicious TR had hemorrhage or effusion in the lesion in the scrotum by ESU, of which TR was confirmed in only 9 (9/15, 60.0%) cases by both scrotoscopy and OE, indicating a complete agreement between scrotoscopy and OE. Thus, both the sensitivity and specificity of scrotoscopy was 100% for diagnosing TR, indicating that scrotoscopy may have a much higher diagnostic value than ESU.

Surgical exploration followed by repair if necessary is the standard treatment for patients having suspected TR. Currently, surgical exploration of the scrotum may have its limitations, as it requires a larger incision,^[4] which seems unnecessary, especially to patients with suspected TR but who are finally confirmed free of TR. Scrotoscopy is a minimally invasive procedure, and has been increasingly used in scrotal diseases.^[5,7,8,17] In the present study, scrotoscopic examination successfully identified TR in all 9 patients, without a false positive case (0/6). The operation did not take much time, taking only 5–13 min. Once the diagnosis of TR was confirmed by scrotoscopy, the primary small incision could also be extended to achieve testicular repair; meanwhile, for patients free of TR confirmed by scrotoscopy, only a 1-cm incision and brief surgery are sufficient, while a larger trauma and longer operation may be unnecessary in future clinical practice.

In terms of safety, only 3 cases (3/15, 20.0%) had scrotal wall edema. Both quickly recovered without any specific treatment apart from mild pressure dressing on the scrotum. This kind of complication was minor and was graded Grade I.^[18] Scrotal hematoma, wound infection, spermatic cord injury, testicular torsion, chronic testicular pain and testicular atrophy were not

observed after scrotoscopy. Scrotal edema is one of the most common complications of scrotoscopy; it can also be seen in traditional surgical exploration.^[5,7] The main cause of scrotal edema in patients receiving scrotoscopy is damage to the testicular tunica vaginalis or infiltration of perfusate alongside the scrotal incision into the sandwiched scrotal wall. Intraoperatively, the tissue forceps should hold the entire layer of the scrotal wall to prevent the scrotoscope or perfusate from reaching into the intermediate layer of the scrotal wall. Furthermore, attention should be paid to controlling the rate and pressure of the perfusion fluid, minimizing perfusion and reducing unnecessary procedures during the operation. Once edema occurs, the operative time should be reduced to the shortest extent possible, which could effectively reduce the severity of edema. In addition, there seems no need to panic if scrotal edema occurs despite all measures. Generally, the scrotum is wrapped with an appropriate pressure dressing, and most of the edema is expected to subside within 24 to 48 h.

This study has several limitations. It is only a retrospective study. Furthermore, the sample size is small. It brings a limited and low level of evidence of the clinical application of scrotoscope for diagnosing TR. In future, multi-center clinical studies with larger sample sizes may be needed to further validate its application value and assess its safety.

In conclusion, to our knowledge, this is the first report of the clinical application of scrotoscope in the diagnosis of TR. According to our findings, scrotoscopic exploration is superior to ESU for the diagnosis of TR. It may offer a novel safe and effective method to diagnose patients suspected as having TR and avoids unnecessary OE if TR is excluded under scrotoscopy. Further clinical studies to verify its application value are warranted in future.

Acknowledgment

This study was supported by the Joint Funds for the Innovation of Science and Technology, Fujian Province (2017Y9064) and high-level hospital foster grants from Fujian Provincial Hospital, Fujian province, China (2019HSJJ29).

Author contributions

YB Wei and JR Yang: Manuscript writing; HS Hong, YL Gao, JF Wu and X Wu: Data collection; RC Zhang and L Lin: Data analysis; FG Yang, LF Ye and T Li: Manuscript editing; QG Zhu: Project sponsor and paper revised.

Data curation: Yunliang Gao, Jinfeng Wu, Le Lin.

Formal analysis: Liefu Ye, Qingguo Zhu.

Funding acquisition: Yongbao Wei.

Investigation: Yongbao Wei, Yunliang Gao, Jinfeng Wu, Xiang Wu, Le Lin, Ruochen Zhang, Tao Li, Fengguang Yang, Qingguo Zhu.

Methodology: Yunliang Gao, Xiang Wu, Ruochen Zhang, Fengguang Yang.

Project administration: Jirui Yang, Liefu Ye.

Supervision: Jirui Yang.

Validation: Tao Li.

Writing – original draft: Huaishan Hong.

Writing – review & editing: Yongbao Wei, Jirui Yang.

References

- [1] Cass AS, Luxenberg M. Testicular injuries. *Urology* 1991;37:528–30.
- [2] Cass AS, Luxenberg M. Value of early operation in blunt testicular contusion with hematocele. *J Urol* 1988;139:746–7.
- [3] Darzi A, Mackay S. Recent advances in minimal access surgery. *BMJ* 2002;324:31–4.
- [4] Onol SY, Ilbey YO, Onol FF, et al. A novel pull-through technique for the surgical management of idiopathic hydrocele. *J Urol* 2009;181:1201–5.
- [5] Bin Y, Yong-Bao W, Zhuo Y, et al. Minimal hydrocelectomy with the aid of scrotoscope: a ten-year experience. *Int Braz J Urol* 2014;40:384–9.
- [6] Wang Z, Wei YB, Yin Z, et al. Diagnosis and management of scrotal superficial angiomyxoma with the aid of a scrotoscope: case report and literature review. *Clin Genitourin Cancer* 2015;13:e311–3.
- [7] Yang JR, Wei YB, Yan B, et al. Comparison between open epididymal cystectomy and minimal resection of epididymal cysts using a scrotoscope: a clinical trial for the evaluation of a new surgical technique. *Urology* 2015;85:1510–4.
- [8] Wang Z, Yang JR, Huang YM, et al. Diagnosis and management of testicular rupture after blunt scrotal trauma: a literature review. *Int Urol Nephrol* 2016;48:1967–76.
- [9] Deurdulian C, Mittelstaedt CA, Chong WK, et al. US of acute scrotal trauma: optimal technique, imaging findings, and management. *Radiographics* 2007;27:357–69.
- [10] Guichard G, El AJ, Del CC, et al. Accuracy of ultrasonography in diagnosis of testicular rupture after blunt scrotal trauma. *Urology* 2008;71:52–6.
- [11] Buckley JC, McAninch JW. Use of ultrasonography for the diagnosis of testicular injuries in blunt scrotal trauma. *J Urol* 2006;175:175–8.
- [12] Powers R, Hurley S, Park E, et al. Usefulness of preoperative ultrasound for the evaluation of testicular rupture in the setting of scrotal gunshot wounds. *J Urol* 2018.
- [13] Munter DW, Faleski EJ. Blunt scrotal trauma: emergency department evaluation and management. *Am J Emerg Med* 1989;7:227–34.
- [14] Avery LL, Scheinfeld MH. Imaging of penile and scrotal emergencies. *Radiographics* 2013;33:721–40.
- [15] Kim SH, Park S, Choi SH, et al. The efficacy of magnetic resonance imaging for the diagnosis of testicular rupture: a prospective preliminary study. *J Trauma* 2009;66:239–42.
- [16] Gadda F, Spinelli MG, Cozzi G, et al. Emergency testicular sperm extraction after scrotal trauma in a patient with a history of contralateral orchiopexy for cryptorchidism: case report and review of the literature. *Fertil Steril* 2012;97:1074–7.
- [17] Ye H, Liu Z, Wang H, et al. A minimally invasive method in diagnosing testicular torsion: the initial experience of scrotoscope. *J Endourol* 2016;30:704–8.
- [18] Dindo D, Demartines N, Clavien PA. Classification of surgical complications: a new proposal with evaluation in a cohort of 6336 patients and results of a survey. *Ann Surg* 2004;240:205–13.