

# Simplified treatment mechanics with a miniscrew for a case of canine impaction

Zuhair Bakhsh

## ABSTRACT

With the introduction of miniscrews into the orthodontic field, the efficiency and effectiveness of treating complex cases have significantly improved. Biomechanical considerations, especially relating to anchorage control have become less of a concern and side effects, as a consequence, have become minimal. This article reports on a canine impaction case in which an orthodontic miniscrew has been used to effectively and efficiently pull the canine, thereby reducing anchorage unit side effects and simplifying treatment mechanics.

**Key words:** Biomechanics, canine impaction, miniscrew

## INTRODUCTION

Following third molars, maxillary canines have the highest rate of impaction. The prevalence of canine impactions in the Western region of Saudi Arabia was found to be 3.3%.<sup>[1]</sup> Labial impactions are generally caused by crowding<sup>[2]</sup> while palatal impactions are caused by factors such as failure of primary canine root resorption, malformed, or missing lateral incisor, and genetics.<sup>[3]</sup>

Because of their large root, crown shape, and location at the corner of the mouth, canines serve an important esthetic and functional purpose. Thus, an important objective during orthodontic treatment of impacted canines is frequently their alignment into their position. However, this treatment requires a combined surgical and orthodontic approach that extends over a lengthy period of time.<sup>[4]</sup>

Traditionally, treatment of maxillary impacted canines involves the use of an orthodontic multibracket fixed appliance system to

create space, pull, and then align the canine.<sup>[5]</sup> Many techniques have been described, all aiming at minimizing the side effects, which are frequently encountered within the anchor unit and on the adjacent teeth.<sup>[6,7]</sup> With the introduction of the miniscrews, it has become possible to reduce and avoid such biomechanical side effects while increasing efficiency and effectiveness of treatment.

Orthodontic miniscrews come in a variety of shapes, diameters, and lengths. A major advantage of these screws is the ability of an orthodontist to place it himself. Failure of the miniscrew, however, is still a concern. In a review of miniscrew clinical trials, it was found that miniscrews have a success rate of 84%.<sup>[8]</sup> An increase in the success rate was found when screws with a diameter of at least 1.2 mm and a length of  $\geq 8$  mm were used.<sup>[8]</sup>

The following case aims at providing a simple technique for the treatment of impacted maxillary canines with the use of an orthodontic miniscrew.

## CASE REPORT

An 11-year-old female presented to the clinic with her parents being concerned about her crooked front teeth. Her medical history was nonsignificant, and her dental history revealed several visits for dental fillings.

Department of Orthodontics, King Abdulaziz University, Jeddah, Saudi Arabia

**Address for correspondence:** Dr. Zuhair Bakhsh, King Abdulaziz University, P. O. Box 10703, Jeddah 21443, Saudi Arabia.  
E-mail: zbakhsh@kau.edu.sa

### Access this article online

#### Quick Response Code:



#### Website:

www.jorthodsci.org

#### DOI:

10.4103/2278-0203.176656

This is an open access article distributed under the terms of the Creative Commons Attribution-NonCommercial-ShareAlike 3.0 License, which allows others to remix, tweak, and build upon the work non-commercially, as long as the author is credited and the new creations are licensed under the identical terms.

**For reprints contact:** reprints@medknow.com

**How to cite this article:** Bakhsh Z. Simplified treatment mechanics with a miniscrew for a case of canine impaction. J Orthodont Sci 2016;5:30-4.

### Clinical Examination

Facial examination [Figure 1] revealed a symmetric mesofacial head shape with a slightly convex facial profile and an obtuse nasolabial angle. The upper midline was deviated 3 mm to the left with regards to the face while the lower midline was centered.

Intraorally, the patient has Class II molars with normal overjet and overbite. There was severe upper space deficiency and mild lower space deficiency. Slight canting of the anterior teeth was noted. The upper right primary canine and lower primary second molars were still present. The upper left primary canine was lost, and space had completely closed. Palpation of the canine area revealed a labial bulge in the vestibule related to the canine.

### Radiographic Examination

The panoramic radiograph [Figure 2] shows that all permanent teeth are present and in their normal eruptive path except for the upper left permanent canine that is horizontally impacted

with the tip of the canine reaching the apex of the central incisor, which is further seen in the periapical radiographs [Figure 3]. All other findings were within normal.

Cephalometric radiograph and analysis [Figure 4] revealed a Class I skeletal pattern with an average mandibular plane angle and lower anterior face height. The upper incisors are proclined and protrusive while the lower are within normal.

### Treatment Objectives and Treatment Plan

Treatment objectives were (1) expose, extrude, and align the impacted canine, (2) maintain the molar Class II relationship and achieve Class I canines, and (3) slightly retrocline and retract upper incisor while correcting the midline discrepancy.

The treatment plan was to extract the upper first premolars and utilize an orthodontic miniscrew to pull the canine following exposure during the initial phase. Later, bond the upper and lower arches with 0.022 brackets to align the teeth and achieve the objectives.

### Treatment Progress

Following extraction of the upper first premolars, the patient was referred to the periodontist for a closed exposure of the upper

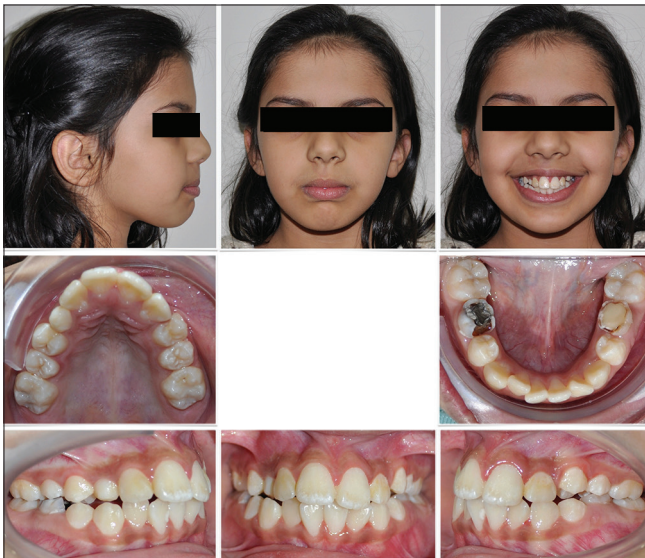

Figure 1: Pretreatment facial and intraoral photographs

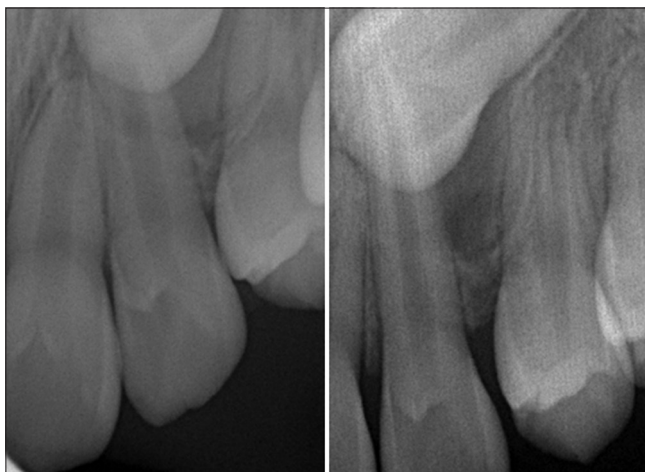

Figure 3: Pretreatment periapical radiographs for impacted canine

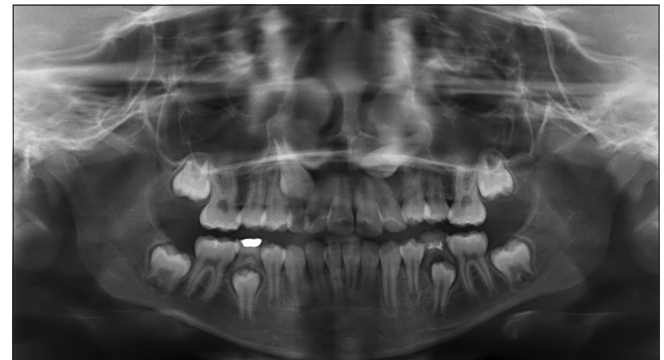


Figure 2: Pretreatment panoramic radiograph

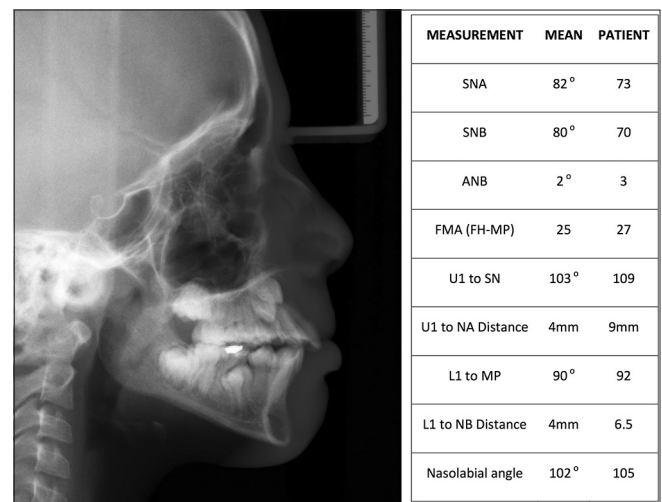
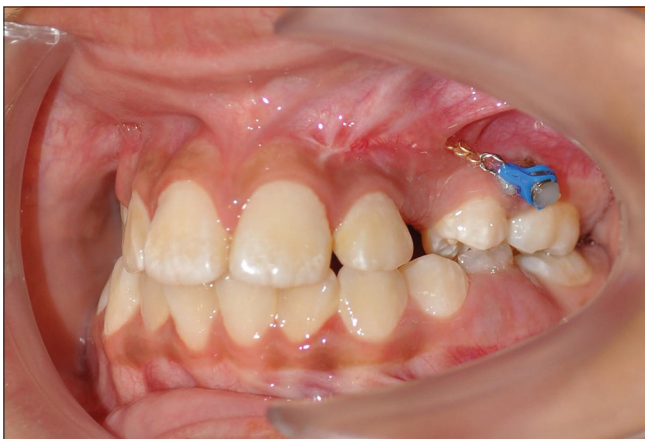

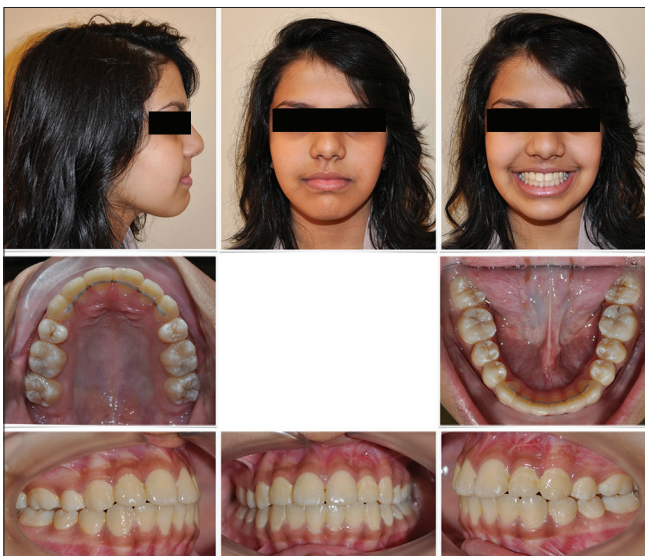Figure 4: Pretreatment cephalometric radiograph and measurements

left canine and bonding of a gold chain (Ortho Technology, Tampa, Florida, USA). An 8 mm long and 1.7 mm diameter orthodontic miniscrew (Ortho Easy, Forestadent, Pforzheim, Germany) was placed at 45° between the upper left second premolar and first molar. An elastic chain was then used from the screw to the gold chain to retract the canine in a distal and slight occlusal direction [Figure 5]. This ensured that the canine was retracted away from the root of the lateral incisor to avoid any root resorption and damage. This process was continued for 8 months until the canine tip had reached the middle of the space provided by the extracted premolar. At this stage, the upper arch was bonded. A panoramic radiograph taken at this point revealed some root resorption related to the upper left central incisor [Figure 6]. The decision was made to reduce the amount of torque correction needed on the central incisor to avoid further root resorption.

Alignment of the upper arch was initiated together with an open coil at the impacted canine area to open further space and correct the midline. Four months later, the lower arch was bonded, and the miniscrew was removed.



**Figure 5:** Miniscrew mechanics to retract the canine



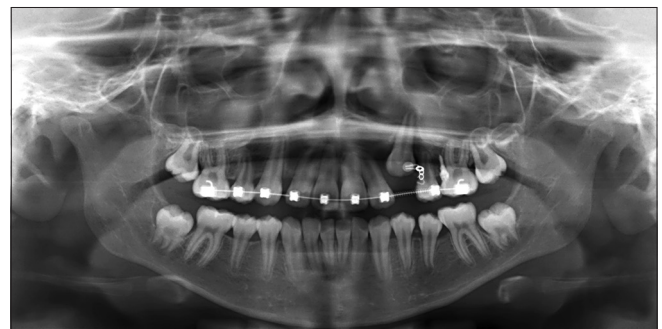
**Figure 7:** Posttreatment facial and intraoral photographs

Reevaluation of the attached gingival condition at the impacted canine led to the decision for re-exposure of the canine using an apically repositioned flap to establish a good width of attached gingiva. Following the exposure, the canine was bonded, and standard orthodontic mechanics was continued until the case was finished. Bonded upper and lower fixed retainers were placed, and the patient received upper and lower Hawley retainers for nighttime wear only. The final results can be seen in Figure 7. The panoramic and cephalometric radiograph with the measurements can be seen in Figures 8 and 9, respectively. The treatment objectives were achieved except for the upper incisors torque, which was avoided due to the root resorption. The patient was seen after 1 year [Figure 10] where she was wearing the removable Hawley retainers at nighttime (3–4 times per week). No change in the root resorption of the central incisor was noted radiographically.

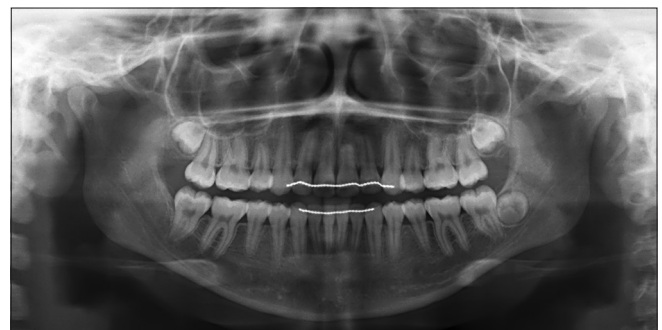The total treatment time was 38 months distributed as follows: Canine traction with a screw (8 months), upper arch mechanics to open space for canine (12 months), and full upper and lower arch treatment (18 months). The reason for the extended treatment time was unfortunately due to the patient missing multiple appointments and delays in the surgical exposure. However, the total number of active treatment visits was only 28.

## DISCUSSION

In the management of impacted canines, the radiographic position of the canine plays an essential role in the determination of the prognosis for treatment. Several authors have proposed grading systems to determine the severity of the impacted

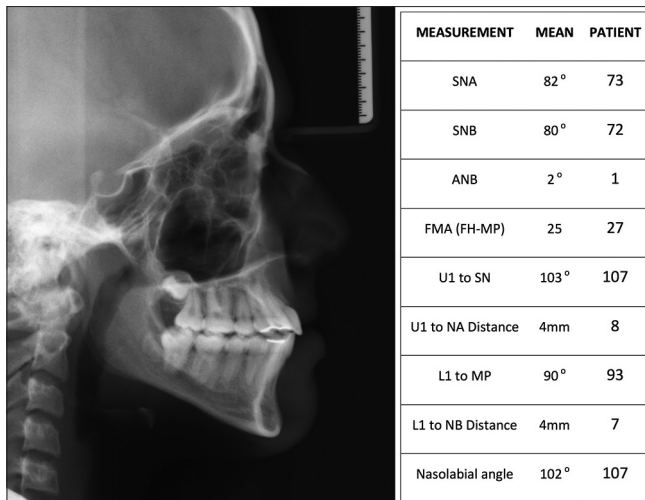


**Figure 6:** Panoramic radiograph on the day of upper arch bonding



**Figure 8:** Posttreatment panoramic radiograph





**Figure 9:** Posttreatment cephalometric radiograph and measurements

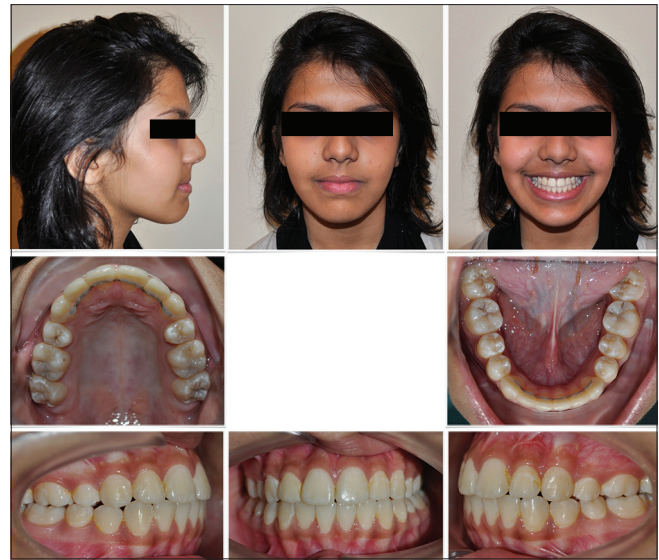canine in the horizontal, sagittal, and vertical dimensions.<sup>[7,9]</sup> According to these grading systems, the poorest prognosis for an impacted canine is when its tip has reached the mesial surface of the lateral incisor; when the root apex is above the second premolar; when the angulation of the canine to the midline is more than 31°; or when the vertical position of the canine has reached the incisor root apex.

The impacted canine, in this case report would, therefore, be considered having a poor prognosis from every aspect. With the advent of miniscrews, however, the prognoses of such cases and others may have to be revisited.

Traditionally, treatment of canine impactions involves overcoming the biomechanical side effects on the anchor unit making treatment more difficult and prognosis more challenging. While miniscrews require their own biomechanical considerations, they are, in this case, far less complicated. Being able to position the miniscrew further distal and more gingival, has enabled the pulling of the canine away from the lateral incisor to avoid root resorption. However, root resorption of the central incisor was noticed though unlikely from the mechanics itself. The use of a cone-beam computed tomography radiograph initially would have helped further with the diagnosis of the case before initiation of treatment.

In addition to the mechanical benefits, the use of the miniscrew as illustrated in this case report has enabled delaying bonding of teeth at a later stage. The risk for orthodontic side effects such as decalcification<sup>[10]</sup> caused by extended treatment time, can, therefore, be reduced. Hence, minimal cooperation is required from the patient during this initial stage of treatment.

In a study by Stewart *et al.*, it was found that treatment time increased from 24 to 31 months when the canine tip was 14 mm or more from the occlusal plane.<sup>[4]</sup> Fleming *et al.* found that canines impacted more than halfway above the adjacent tooth required almost 6 months longer to correct.<sup>[11]</sup> In a study by



**Figure 10:** One-year retention follow-up facial and intraoral photographs

Iramaneerat *et al.*, the average treatment duration for typically impacted canines was shown to be 28.8 months.<sup>[12]</sup> In the case illustrated here, it only took 28 active treatment visits to complete the treatment. With the poor position of the canine, this would be considered a fast, efficient, and effective treatment method. More importantly, treatment was simplified. Unfortunately, patient cooperation with multiple missed appointments has led to the extended treatment time in this case.

Orthodontic miniscrews are used for anchorage in many different malocclusions. A major concern with their use, however, is the ability of the miniscrew to withstand the forces applied and to remain stable. The miniscrew used in this case report was able to withstand all forces and remain stable for the duration of force application. In a review by Crismani *et al.*, it was concluded that the most important factors for increased success of a miniscrew were the use of a diameter of greater than 1.2 mm and a length of 8 mm or more.<sup>[6]</sup> The miniscrew used in this case report was 1.7 mm in diameter with a length of 8 mm, which is likely to have helped with the success of the miniscrew. Furthermore, the placement of the miniscrew in attached gingiva and at an angle of 45° to the occlusal plane has helped minimize side effects such as gingival inflammation and overgrowth and root damage.

### Declaration of patient consent

The authors certify that they have obtained all appropriate patient consent forms. In the form the patient(s) has/have given his/her/their consent for his/her/their images and other clinical information to be reported in the journal. The patients understand that their names and initials will not be published and due efforts will be made to conceal their identity, but anonymity cannot be guaranteed.

### Financial Support and Sponsorship

Nil.

## Conflicts of Interest

There are no conflicts of interest.

## REFERENCES

1. Afify AR, Zawawi KH. The prevalence of dental anomalies in the Western Region of Saudi Arabia. *ISRN Dent* 2012;2012:837270.
2. Jacoby H. The etiology of maxillary canine impactions. *Am J Orthod* 1983;84:125-32.
3. Peck S, Peck L, Kataja M. Prevalence of tooth agenesis and peg-shaped maxillary lateral incisor associated with palatally displaced canine (PDC) anomaly. *Am J Orthod Dentofacial Orthop* 1996;110:441-3.
4. Stewart JA, Heo G, Glover KE, Williamson PC, Lam EW, Major PW. Factors that relate to treatment duration for patients with palatally impacted maxillary canines. *Am J Orthod Dentofacial Orthop* 2001;119:216-25.
5. Becker A, Chaushu S. Success rate and duration of orthodontic treatment for adult patients with palatally impacted maxillary canines. *Am J Orthod Dentofacial Orthop* 2003;124:509-14.
6. Paduano S, Cioffi I, Iodice G, d'Antò V, Riccitiello F, Pellegrino G, *et al.* Correction of multiple canine impactions by mixed straightwire and cantilever mechanics: A case report. *Case Rep Dent* 2014;2014:925019.
7. Becker A. *The Orthodontic Treatment of Impacted Teeth*. Oxford, United Kingdom: Wiley-Blackwell; 2012.
8. Crismani AG, Bertl MH, Celar AG, Bantleon HP, Burstone CJ. Miniscrews in orthodontic treatment: Review and analysis of published clinical trials. *Am J Orthod Dentofacial Orthop* 2010;137:108-13.
9. Ericson S, Kurol J. Radiographic examination of ectopically erupting maxillary canines. *Am J Orthod Dentofacial Orthop* 1987;91:483-92.
10. Tufekci E, Dixon JS, Gunsolley JC, Lindauer SJ. Prevalence of white spot lesions during orthodontic treatment with fixed appliances. *Angle Orthod* 2011;81:206-10.
11. Fleming PS, Scott P, Heidari N, Dibiase AT. Influence of radiographic position of ectopic canines on the duration of orthodontic treatment. *Angle Orthod* 2009;79:442-6.
12. Iramaneerat S, Cunningham SJ, Horrocks EN. The effect of two alternative methods of canine exposure upon subsequent duration of orthodontic treatment. *Int J Paediatr Dent* 1998;8:123-9.