



# Hemisensory Loss after Ventriculoperitoneal Shunt Insertion

Rafaa Algethami<sup>1</sup> Rana H. Moshref<sup>1</sup> Abdulrahman J. Sabbagh<sup>1</sup>

<sup>1</sup>Neurosurgery Department, King Abdulaziz University Hospital, Jeddah, Saudi Arabia

Address for correspondence Rana H. Moshref, MBBS, King Abdulaziz University Hospital, Jeddah, 22254, Saudi Arabia (e-mail: ranamoshref@gmail.com).

AJNS 2022;17:683–686.

## Abstract

### Keywords

- ▶ ventriculoperitoneal shunt
- ▶ sensory loss
- ▶ thalamus
- ▶ intracranial hypertension
- ▶ deficits

Idiopathic intracranial hypertension includes ventriculoperitoneal shunt (VPS) insertion, with a reported complication of shunt revision in 25% of the cases 1 year after insertion. We report a case of a 28-year-old female with pituitary adenoma who developed sensory loss after VPS placement that could be explained by disruption in thalamic pathways. A lesson learned from this case is that although VPS is a simple procedure, complications can occur. Modalities can be used to detect the complications, and further revisions might be needed.

## Introduction

Idiopathic intracranial hypertension (IIH) is a disease that has elevated intracranial pressure with an unknown etiology and usually requires a ventriculoperitoneal shunt (VPS) insertion. IIH prevalence is 1 in 100,000 people, affects mostly women of childbearing age, and results in permanent vision loss with increased intracranial pressure.<sup>1</sup> Risk factors include female gender, endocrine disorders (Addison's disease, hypoparathyroidism), exogenous growth hormone replacement, hypervitaminosis (vitamin A, isotretinoin) and with obesity, the incidence can reach as high as 13 to 14/100,000 per Iowa and Louisiana states.<sup>2</sup> Manifestations of the disease include headache (94%), transient visual obscuration (68%), pulse synchronous tinnitus (58%), photopsia (54%), and retrobulbar pain (44%), and less than 30% of diplopia and visual loss.<sup>3</sup>

Usually, the treatment of IHH includes administration of carbonic anhydrase inhibitors, lumbar punctures, as well as surgical cerebrospinal fluid diversion in the form of lumbo-

peritoneal shunt or ventriculoperitoneal shunt. When placing a VPS, the preferred procedure among neurosurgeons is a right parietooccipital approach (Keen approach) with the use of a medium pressure valve.<sup>4</sup> According to a 1990 study, ventricular size on routine computed tomography (CT) has no predictive value when evaluating patients with suspected pseudotumor cerebri.<sup>5</sup> However, in a study published in 2016 called "optimizing ventriculoperitoneal shunt placement in the treatment of idiopathic intracranial hypertension and intraoperative CT," the prediction grade was mixed with the outcome. Grading included grade 1 (catheter terminates in the ipsilateral frontal horn or third ventricle), grade 2 (catheter terminates in the contralateral frontal horn), grade 3 (catheter terminates in the non-target cerebrospinal fluid space), and grade 4 (catheter terminates within the brain parenchyma), as most success rates are in grades 1 and 2 by 90%.<sup>6,7</sup> An assessment postoperatively is usually done to assess ventricular size and catheter site.<sup>5</sup> The rates of complications post-VPS insertion according to World Neurosurgery are highest in the 1-year postinsertion as

article published online  
October 28, 2022

DOI <https://doi.org/10.1055/s-0042-1757436>.  
ISSN 2248-9614.

© 2022. Asian Congress of Neurological Surgeons. All rights reserved.

This is an open access article published by Thieme under the terms of the Creative Commons Attribution-NonDerivative-NonCommercial-License, permitting copying and reproduction so long as the original work is given appropriate credit. Contents may not be used for commercial purposes, or adapted, remixed, transformed or built upon. (<https://creativecommons.org/licenses/by-nc-nd/4.0/>)

Thieme Medical and Scientific Publishers Pvt. Ltd., A-12, 2nd Floor, Sector 2, Noida-201301 UP, India

complications occur in nearly 1 out of 4 patients, including revision in nearly 25% of the cases and infection in 5%.<sup>7</sup>

## Materials and Methods

In our study, we report a case of a female with pituitary adenoma and IIH who developed hemisensory loss.

## Result

### Case Report

A 29-year-old female, known case of pituitary adenoma, IIH, and obese (body mass index: 40), was admitted electively for VPS insertion. Her main complaints were throbbing headaches and double vision. She reported episodic blurred vision and sensory disturbances at different times and places. There were no vision abnormalities, no seizures, no weakness, no loss of consciousness, no rash, and no joint stiffness.

Her previous medical and surgical history includes a diagnosis of pituitary adenoma secondary to prolactinoma in 2008, based on symptoms of galactorrhea and amenorrhea, magnetic resonance imaging (MRI) brain, and laboratory findings of high prolactin levels of 200 mcg/L. She was treated with cabergoline and her prolactin decreased dramatically to 36 mcg/L. She then developed headache, bilateral papilledema, and right 6th nerve palsy after the second cabergoline dose, and a concomitant diagnosis of benign intracranial hypertension was made. She stopped taking cabergoline 0.5 mg 1 month after diagnosis by herself. However, she continued to take omeprazole 20 mg and acetazolamide. She did a gastric sleeve in 2010 with significant weight loss in a year and recurrence of obesity within the last 3 years. As she was not taking her multivitamins for her expected mineral deficiency postoperatively, she developed her current symptoms. Later, a lumboperitoneal shunt was placed in 2011 for her continuous headaches that migrated twice and revised. In another institution, she was monitored with a CT brain scan until the radiological features vanished. There was no family history of autoimmune diseases or cancers.

### Hospital Course

She was admitted for VPS insertion. A preoperative visual assessment was done. The visual field was normal. Papilledema was seen in the fundoscopic examination. On examination, she was alert, conscious, and oriented; her Glasgow Coma Scale (GCS) was 15/15; cranial nerves were intact except for right 6th nerve palsy; motor and sensory function in upper and lower limbs.

She was admitted for navigated VPS insertion (due to small ventricles) and removal of the old migrated tubes. A preoperative CT scan of the brain was done that showed an enlarged empty sella turcica, dilation of the optic sheath with the vertical tortuosity of the optic nerves and flattening of the posterior sclera, no midline shift, no mass effect, left transverse sinus is hypoplastic, and thinning of the sigmoid plate is noted bilaterally with possible dehiscence.

She gave consent for VPS insertion and laparoscopic old tube removal. Preoperative laboratory results were normal,

other than iron deficiency anemia. A right parietal VPS insertion was done with an adjustable valve, and on day 1 postoperatively, her headache and double vision subsided. Postoperative CT brain was done that showed a right parietal ventricular catheter tip seen in the left thalamus, no ventricular dilatation, and no intra- or extra-axial hemorrhage (►Fig. 1).

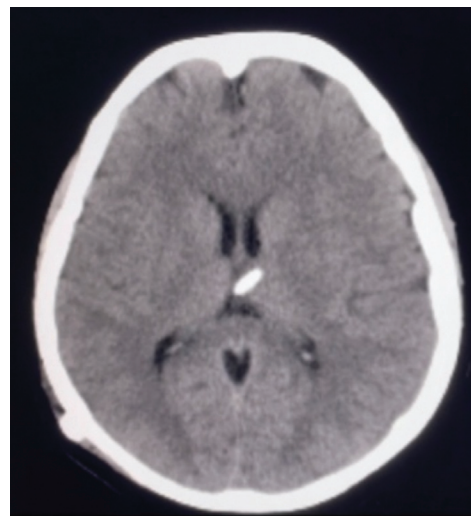
On day 2 postoperatively, she started to have hemisensory loss on the left side. The examination showed intact cranial nerve examination other than the improving right sixth nerve palsy and abnormal sensations (pinprick, temperature, vibration, proprioception) on the left side of the body compared with the right side. A CT showed that the ventricular tube tip was inside the thalamus on the left side, ipsilateral to the symptoms, with no other findings. A shunt revision was done, where a ventricular catheter was pulled 1 cm out with no change in catheters or valve. She was followed postoperatively, and the symptoms did not resolve. Postoperative VPS revision surgery showed that the tip of the right posterior parietal VP shunt was at the cistern of the velum interpositum, and air focus was seen at the periphery of the frontal horn of the right ventricle, with no change in the ventricular system and no bleeding (►Figs. 2–4). Two days post-VPS revision, the patient was discharged on acetazolamide 500mg twice a day and Solpadeine (paracetamol, caffeine, and aspirin) to be taken three times daily for 30 days.

### Follow-Up

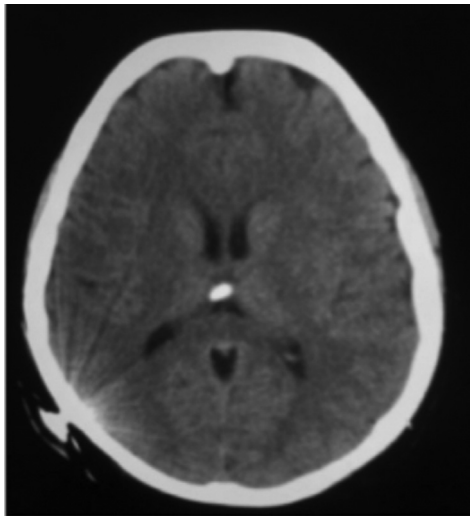
She was seen in the clinic 1 week, 1 month, and 6 months after being discharged. Headache improved. The sixth nerve palsy resolved. The Strata valve was adjusted to 2 and the wound was clean and dry.

## Discussion

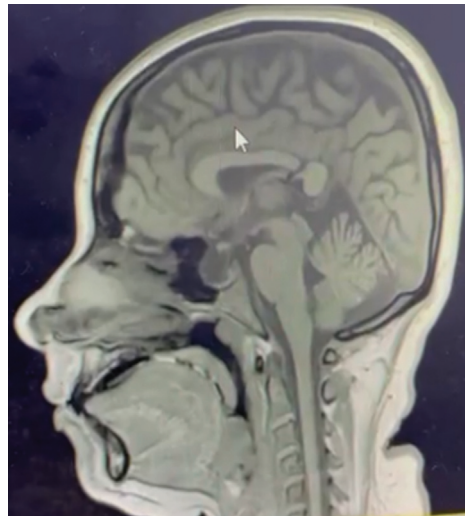
Based on a retrospective cohort study, the overall incidence of VPS placement in the US population is 5.5 per 100,000.



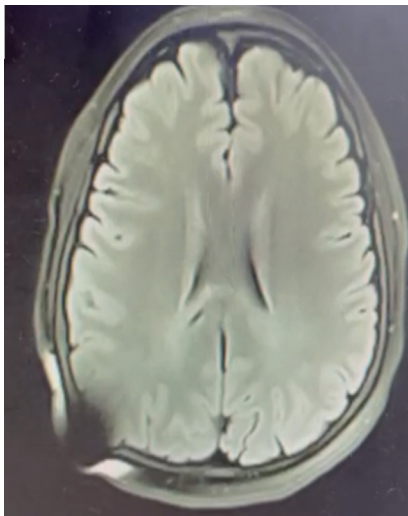
**Fig. 1** Postoperative computed tomography brain. Right parietal ventricular catheter tip seen in left thalamus.



**Fig. 2** Postoperative computed tomography brain showing post-ventriculoperitoneal shunt (VPS) revision surgery. Tip of the right posterior parietal VPS is at cistern of velum interpositum, air focus is seen at the periphery of the frontal horn of the right ventricle with no change in ventricular system and no bleeding.



**Fig. 4** Postoperative magnetic resonance imaging brain sagittal cut. Tip of right posterior parietal ventriculoperitoneal shunt is seen crossing splenium of corpus callosum.



**Fig. 3** Postoperative magnetic resonance imaging brain coronal cut. Tip of right posterior parietal ventriculoperitoneal shunt is seen parallel to semiovale.

Although VPS insertion is a common and simple procedure, it carries a risk of complications that are usually detected by the new appearance of symptoms or neurological deficits.<sup>8</sup> A 2020 study conducted in the central region of Saudi Arabia concluded that the most common reasons for the first three revisions are valve mechanical failures followed by infections.<sup>9</sup> In a US study, it showed a cumulative complication rate of nearly 30 and 48% in a 5-year duration in adults and pediatric populations, respectively.<sup>8</sup>

In our study, hemianesthesia was reported, but the literature is scarce with cases that report neurological complications. The occurrence of symptoms in this case can be explained based on anatomical regions of the brain that could possibly include affection of somatosensory area 1, 2, corona radiata, or ventral posterolateral nucleus in the

thalamus<sup>10</sup> however, tractography did not show any anomalies. According to a 2003 study that discussed somatosensory and motor disturbances in patients with parietal lobe lesions, posterior lesions are frequently associated with impairment of more complex synthetic somatosensory functions similar to those observed after deep cerebellar lesions. Damage to the posterior parietal lobe can interfere with almost every aspect of somatosensory function.<sup>10</sup>

Also, her symptoms may be explained physiologically by possible undiagnosed multiple sclerosis and vitamin deficiency. Multiple sclerosis is diagnosed with McDonald's diagnostic criteria that include clinical, radiological, and laboratory findings of neurological symptoms separated by time and place.<sup>11,12</sup> Also, vitamin deficiency can occur after 7 years post-bariatric surgery if not replaced, and patients present with anemia and numbness due to a deficiency in B vitamins.<sup>12</sup> According to a study (neurological complications of nutritional deficiency following bariatric surgery), patients may suffer from permanent deficits such as ocular motility abnormalities, ataxia, and mental status changes if thiamine deficiency is not detected early enough.<sup>13</sup> Also, cobalamin can play a role in its deficiency as it can cause decreased vibratory sensation and proprioception in the lower extremities.<sup>14</sup>

To prevent neurological complications from injury to neurological structures, a tractography can be used based on diffusion tensor imaging (DTI) for surgical planning and to analyze white matter anatomy in a tract-specific manner,<sup>15</sup> such as thalamocortical radiations (posterior thalamic radiations connected to the thalamic caudal parts with the parietal and occipital lobes via the posterior thalamic peduncle), superior thalamic radiations (superior thalamic peduncle and the posterior limb of the internal capsule to the ventral nuclear group of the thalamus with the precentral and postcentral gyrus).<sup>16,17</sup> Another modality includes use of functional MRI (fMRI) that is a quick noninvasive

technique as it reveals blood flow to the active cortex.<sup>18</sup> The combination of fMRI activation tasks and DTI is not usually used in clinical practice, but they may be useful in defining the structural basis of functional connectivity in the normal brain, as well as how these networks degrade in disease states.<sup>19</sup> An assessment using resting state functional MRI study published in 2016 concluded that brain networks associated with cognition control are altered in patients with vitamin B12 deficiency, which partially recovers after 6 weeks of replacement therapy.<sup>20</sup>

## Conclusion

A lesson learned from this case is that although VPS is a simple procedure, complications can happen. Modalities can be used to detect the complications and further revisions might be needed.

### Authors' Contributions

R.A. was involved in collecting the data, writing the manuscript, and editing the manuscript. R.M. wrote and edited the manuscript and revised the final proof. A.S. contributed to idea formation and final proof revision.

### Ethical Approval and Informed Consent

Informed consent has been obtained from the patient conforming to Declaration of Helsinki.

### Funding

None.

### Conflict of Interest

None declared.

### Acknowledgment

The authors would like to thank the patient for agreeing to publish the case as a form of educational tool.

## References

- 1 Fowler JB, De Jesus O, Mesfin FB. Ventriculoperitoneal Shunt. Puerto Rico: StatPearls; 2021
- 2 Durcan FJ, Corbett JJ, Wall M. The incidence of pseudotumor cerebri. Population studies in Iowa and Louisiana. *Arch Neurol* 1988;45(08):875–877
- 3 Wall M. Idiopathic intracranial hypertension. *Neurol Clin* 2010;28(03):593–617
- 4 Pople IK. Hydrocephalus and shunts: what the neurologist should know. *J Neurol Neurosurg Psychiatry* 2002;73(Suppl 1):i17–i22
- 5 Jacobson DM, Karanjia PN, Olson KA, Warner JJ. Computed tomography ventricular size has no predictive value in diagnosing pseudotumor cerebri. *Neurology* 1990;40(09):1454–1455
- 6 Yim B, Reid Gooch M, Dalfino JC, Adamo MA, Kenning TJ. Optimizing ventriculoperitoneal shunt placement in the treatment of idiopathic intracranial hypertension: an analysis of neuroendoscopy, frameless stereotaxy, and intraoperative CT. *Neurosurg Focus* 2016;40(03):E12. Doi: 10.3171/2015.12.FOCUS15583
- 7 Merkler AE, Ch'ang J, Parker WE, Murthy SB, Kamel H. The rate of complications after ventriculoperitoneal shunt surgery. *World Neurosurg* 2017;98:654–658
- 8 Wu Y, Green NL, Wrensch MR, Zhao S, Gupta N. Ventriculoperitoneal shunt complications in California: 1990 to 2000. *Neurosurgery* 2007;61(03):557–562, discussion 562–563
- 9 Altweiri IS, AlRaddadi KK, Alsager GA, et al. Patterns and prognosis of ventriculoperitoneal shunt malfunction among pediatrics in Saudi Arabia. *Neurosciences (Riyadh)* 2020;25(05):356–361
- 10 Freund HJ. Somatosensory and motor disturbances in patients with parietal lobe lesions. *Adv Neurol* 2003;93:179–193
- 11 Kamińska J, Koper OM, Piechal K, Kemona H. Multiple sclerosis - etiology and diagnostic potential. *Postepy Hig Med Dosw* 2017;71(00):551–563
- 12 Stroh C, Manger T, Benedix F. Metabolic surgery and nutritional deficiencies. *Minerva Chir* 2017;72(05):432–441
- 13 Liebermann M, Toga AW. *Brain Mapping: An Encyclopedic Reference*. USA: Elsevier; 2015
- 14 Heaton EB, Savage DG, Brust JC, Garrett TJ, Lindenbaum J. Neurologic aspects of cobalamin deficiency. *Medicine (Baltimore)* 1991;70(04):229–245
- 15 Newton HB. *Handbook of Neuro-Oncology Neuroimaging*. 2nd edition. USA: Academic Press; 2016
- 16 Zhang Y, Zhang J, Oishi K, et al. Atlas-guided tract reconstruction for automated and comprehensive examination of the white matter anatomy. *Neuroimage* 2010;52(04):1289–1301
- 17 George K, M. Das J. *Neuroanatomy, Thalamocortical Radiations*. USA: StatPearls Publishing; 2021
- 18 Westbrook C. *Handbook of MRI Technique*. 3rd edition. Wiley; 2008. Available at: <https://nu.edu.sa/documents/1881691/0/Handbook+of+MRI+Technique.pdf/9043c4b5-06f5-44b1-b0f6-2d42c0284780>
- 19 Guye M, Parker GJ, Symms M, et al. Combined functional MRI and tractography to demonstrate the connectivity of the human primary motor cortex in vivo. *Neuroimage* 2003;19(04):1349–1360
- 20 Gupta L, Gupta RK, Gupta PK, Malhotra HS, Saha I, Garg RK. Assessment of brain cognitive functions in patients with vitamin B12 deficiency using resting state functional MRI: a longitudinal study. *Magn Reson Imaging* 2016;34(02):191–196