



Since January 2020 Elsevier has created a COVID-19 resource centre with free information in English and Mandarin on the novel coronavirus COVID-19. The COVID-19 resource centre is hosted on Elsevier Connect, the company's public news and information website.

Elsevier hereby grants permission to make all its COVID-19-related research that is available on the COVID-19 resource centre - including this research content - immediately available in PubMed Central and other publicly funded repositories, such as the WHO COVID database with rights for unrestricted research re-use and analyses in any form or by any means with acknowledgement of the original source. These permissions are granted for free by Elsevier for as long as the COVID-19 resource centre remains active.

administration. Rare cases with rituximab-induced acute thrombocytopenia have been reported in the literature. **Case report:** A 51-year-old female patient who newly diagnosed splenic marginal zone lymphoma received rituximab as first line therapy. Petechiae occurred in the lower extremities on the day following rituximab administration. The blood test showed a severe drop in the platelet count from 112,000/ μ L to 5,000/ μ L. Blood peripheral smear evaluation confirmed severe thrombocytopenia. **Results:** There was no change in hemoglobin or white blood cell levels. After the diagnosis of rituximab-induced acute thrombocytopenia, thrombocyte suspension was administered due to the risk of bleeding. Close clinical and laboratory observations were made. The platelet count began to rise gradually in the following period. Before the second week of rituximab administration, the platelet count was 122,000/ μ L. **Conclusion:** Rituximab has a widespread use, especially in malignancies and autoimmune diseases. Like many monoclonal antibodies, rituximab has several side effects. Thrombocytopenia is a long-term side effect associated with rituximab, and rituximab-induced severe acute thrombocytopenia has been rarely reported. Therefore, it should be kept in mind that severe acute thrombocytopenia may develop after rituximab administration.

<https://doi.org/10.1016/j.htct.2022.09.1255>

PP 21

VITAMIN B 12 DEFICIENCY MIMICKING THROMBOTIC MICROANGIOPATHY: A CASE REPORT

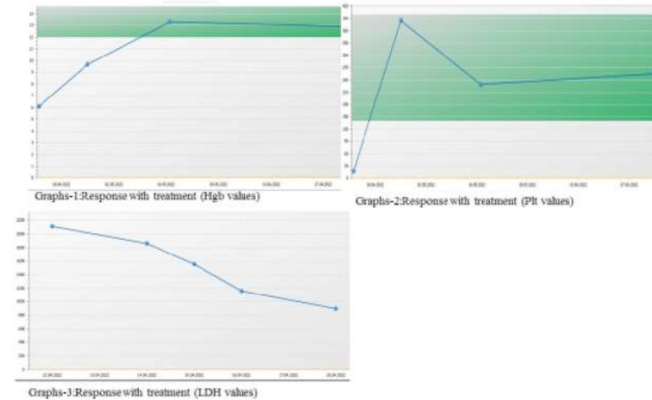
Müzeyyen Aslaner Ak¹, Selime Yiğit², Gizem Süren², Şehmus Ertop¹

¹ Zonguldak Bulent Ecevit University Faculty of Medicine Department of Hematology

² Zonguldak Bulent Ecevit University Faculty of Medicine Department of Internal Medicine

Objective: Vitamin B12 has an important role in DNA synthesis, erythrocyte development and neurological functions by the transfer of one-carbon methyl groups. Vitamin B 12 deficiency may mimic Thrombotic Microangiopathy (TMA) and lead to pseudo-thrombotic microangiopathy (pseudo-TMA). Early recognition of pseudo-TMA is important because treatment with vitamin B 12 replacement is quite simple and effective. **Case report:** A 66-year-old female patient was admitted to the emergency department with complaints of fatigue. CBC values Hb 3.8gr/dL, Hct 11.3%, MCV 115 fL, platelets 19000/mm³, WBC 6400/mm³, ind.bil.1.5 mg/dL, LDH 2111U/L. In peripheral blood smear (PBS), macroovalocytes, anisopoikilocytes, schistocytes, hypersegmented neutrophils and a normoblast with megaloblastic features (figure-1) were observed. Thrombocytopenia and the presence of schistocyte initially supported TMA. **Methodology:** Blood was drawn from the patient for the ADAMTS-13 test. While concurrent steroid treatment with fresh frozen plasma (FFP) was started, plasmapheresis preparation was also made. The patient's vitamin B12 level was 50 pg/mL. The patient was started on vitamin B12

as 1000 mcg IM. Following clinical recovery, hemoglobin and platelets stabilized, the hemolysis panel indicated a steady improvement (graphs 1, 2, 3). **Results Conclusion:** TMA symptoms can be mimicked by severe vitamin B12 deficiency. Rapid and accurate diagnosis of pseudo-TMA and initiation of parenteral vitamin B 12 replacement can prevent unnecessary and expensive diagnostic investigations and long-term plasma exchange treatments. Our case, has demonstrated the importance of considering vitamin B12 insufficiency in cases presenting with TMA and the value of carefully examining PBS in the identification of megaloblastic anemia.



<https://doi.org/10.1016/j.htct.2022.09.1256>

PP 22

QUALITY OF LIFE IN HEMATOLOGICAL PATIENTS IN THE POST-COVID ERA

Weronika Lebowa, Karol Miklusiak, Ositadima Chukwu, Agnieszka Giza, Tomasz Sacha

Department of Haematology, University Hospital, Jagiellonian University Medical College, Cracow, Poland

Objective: Currently, restrictions related to the COVID-19 pandemic have been lifted in many countries. However, the pandemic could still have impact on the current quality of life of patients, especially oncological ones. Our study aimed to determine the impact of the COVID-19 pandemic on the functioning of patients with hematological diseases. **Methodology:** This is a prospective survey-based study. We used the EORTC QoL questionnaire in the population consisting of 32 patients: 22 with lymphoma (69%), 4 with hairy cell leukemia (13%), 3 with myelofibrosis (9%), 1 with acute myeloid leukemia (3%), 1 with chronic myeloid leukemia (3%), 1 with non-oncologic disease (3%). The median age was 50.5 years (ranged 21 – 76). The questionnaires were collected between May and June 2022. Statistical analysis was performed using R software (R version 4.0.3.). **Results:** 41% of patients had a COVID-19 infection confirmed by PCR test. 38% of them were hospitalized, 80% of whom required oxygen therapy. Quality of life was 62.5 (16.7 – 83.3), functioning scales: physical

functioning 86.7, role functioning 66.7, emotional functioning 83.3, cognitive functioning 83.3, social functioning 66.7; symptom: fatigue 33.3, insomnia 33.3. Patients who required oxygen therapy had higher scores on the financial impact scale than those who didn't, 66.7 vs 0, $p = 0.0261$. **Conclusion:** Role and social functioning was the worst item among functioning scales. Women had significantly higher social functioning than men. Fatigue and insomnia were the most burdensome symptoms assessed on the symptom scales. No significant differences were found in scores of EORTC between patients who reported COVID infection and those who didn't. The limitation of this study is a relatively small research group. The future direction is to perform a similar analysis on a larger population.

<https://doi.org/10.1016/j.htct.2022.09.1257>

PP 23

ECULIZUMAB DOSE ADJUSTMENTS DURING PREGNANCIES IN PAROXYSMAL NOCTURNAL HEMOGLOBINURIA: A SINGLE CENTER EXPERIENCE.

Semra Aydin¹, Valentina Giai², Stefano D'ardia², Giorgia Iovino³, Chiara Frairia², Irene Urbino², Marco Cerrano², Eloise Beggiato⁴, Ernesta Audisio²

¹ Department of Oncology, Hematology, Immuno-Oncology and Rheumatology, University Hospital of Bonn, Bonn

² Department of Oncology, Hematology, A.O.U. Città della Salute e della Scienza, Turin, Italy

³ Servizio di Oncologia ed Ematologia, Cirie, Italy

⁴ Unit of Hematology, Department of Oncology, University of Turin, Turin, Italy

Objective: Paroxysmal nocturnal hemoglobinuria (PNH) has always been considered a relative contraindication for pregnancy. The use of eculizumab has reduced morbidity and mortality of fetus and mother. Dose adjustments are often required due to emerging breakthrough hemolysis, no standard recommendations are currently available in this setting. Here we report our single hematology center experience on breakthrough hemolysis and eculizumab dose adjustments during PNH pregnancies. **Methodology:** Clinical data of four pregnancies from three PNH patients are reported. Two of them were already on standard dosage eculizumab when pregnancies were diagnosed. Their baseline PNH clone sizes were 89.5% and 97.5% on granulocytes and 38% and 90% on erythrocytes, respectively. In both cases low molecular weight heparin-prophylaxis was started when pregnancy was diagnosed. The third 26 year old patient with a baseline PNH clone of 8.8% started treatment at the beginning of her 2nd trimester. **Results:** The 26 year old patient was stable on 900 mg Eculizumab until 12 weeks post-partum. The other two developed breakthrough hemolysis during their third trimesters. Eculizumab dosing was increased initially from 900mg

bi-weekly to 900 mg weekly and subsequently to 1200 mg biweekly. The 28 year old patient with the largest clone underwent two pregnancies and required even a 1200mg weekly dosage in her first pregnancy until four weeks post-partum. All four babies were delivered without complications. **Conclusion:** Eculizumab dose adjustments up to 1200 mg biweekly as well as interval shortening from bi-weekly to weekly administration seems effective and safe in breakthrough hemolysis control during pregnancy in PNH. Dose escalations did not impact on birth or development of the babies.

<https://doi.org/10.1016/j.htct.2022.09.1258>

PP 24

ALECTINIB-RELATED ERYTHROCYTE MEMBRANE CHANGES, NON-IMMUNE HEMOLYSIS AND ERYPTOSIS

Emine Gulturk

Bakirkoy Dr Sadi Konuk Hospital

Objective: Alectinib is an anaplastic lymphoma kinase (ALK) inhibitor which standard initial treatment for patients with advanced ALK rearranged non-small-cell lung cancer (NSCLC). The current study was planned by the incidental observation of non-immun hemolysis signs in several alectinib-treated patients, and its aim was to comprehensively characterize erythrocyte changes under this drug. **Methodology:** We analyzed retrospectively 13 patients treated with alectinib for ALK+ NSCLC at the Bakirkoy Sadi Konuk and Kartal Dr Lutfi Kırdar Hospital Medical Oncology Department. Almost all patients were consulted with the hematology clinic because of anemia and elevated lactate dehydrogenase during alectinib. Laboratory tests requested for characterization of anemia included reticulocyte count, indirect bilirubin, haptoglobin, direct antiglobulin test, and LDH. All patients were examined by peripheral smear. **Results:** The analyzed patients, hematological tests results are showed that: Anemia was present in approximately all of patients and was mostly mild, (lowest hgb 8.5gr/dl). Reticulocytes were increased and the direct antiglobulin (Coombs) test was negative in all patients. Peripheral blood smears showed signs of eryptosis, abnormal red blood cell morphology in all patients, with anisocytosis, a predominance of acanthocytes, as well as occasional echinocytes, spherocytes, dacrocytes and rare fragmentocytes. **Conclusion:** We have reported 13 cases of significant alterations in erythrocyte morphology secondary to alectinib. Patients predominantly showed mild anemia, but one patient developed significant Coombs-negative hemolysis. In this case, hemolytic markers improved after alectinib was discontinued. This study highlights the need for both clinicians and haematologists to be observant for unrecognised off-target effects of novel agents.

<https://doi.org/10.1016/j.htct.2022.09.1259>