

CASE REPORT

Myotonic dystrophy as a cause of colonic pseudoobstruction: not just another constipated child

Andrea M. Glaser¹, Jennifer H. Johnston², Wallace A. Gleason¹ & J. Marc Rhoads¹

¹Department of Pediatrics, Division of Gastroenterology, University of Texas Medical School at Houston, Houston, Texas

²Department of Radiology, University of Texas Medical School at Houston, Houston, Texas

Correspondence

Marc Rhoads, University of Texas Health Science Center at Houston, 6431 Fannin St., MSB 3.137, Houston, TX 77030. Tel: 713 500 7642; Fax: 713 500 5750; E-mail: J.Marc.Rhoads@uth.tmc.edu

Funding Information

No sources of funding were declared for this study.

Received: 22 July 2014; Revised: 13 January 2015; Accepted: 20 February 2015

Clinical Case Reports 2015; 3(6): 424–426

doi: 10.1002/ccr3.256

Case History

A 10-year-old Caucasian female with a medical history of congenital myotonic dystrophy presented in July of 2012 for fecal impaction. Initial review of her history revealed two previous admissions (2007 and 2008) for small bowel obstruction related to adhesions requiring surgical intervention. During this admission, our first encounter with the patient, she responded well to standard bowel cleanout with nasogastric polyethylene glycol 3350 (PEG 3350, GoLyte[®], Braintree Laboratories, Braintree, MA, USA) and was discharged home with an oral regimen of PEG 3350 (Miralax[®], Bayer Healthcare, Whippany, NJ, USA) 17 g daily.

She was readmitted two months later with fecal impaction and signs of small bowel obstruction on upper GI study. Exploratory laparotomy resulted in lysis of adhesions. Postoperative recovery was routine, and she was discharged on a bowel regimen of PEG 3350, 17 g twice daily. Again, she showed a good response until two months later, when she was admitted for abdominal distension with a differential diagnosis of fecal impaction versus small bowel obstruction. On abdominal flat plate films, both the colon and small intestine were severely dilated, (Fig. 1). She was treated with manual disimpac-

Key Clinical Message

Muscular dystrophy has been traditionally associated with common gastrointestinal symptoms such as reflux, constipation, and dysphasia. In myotonic dystrophy, there are rare reports of chronic intestinal pseudoobstruction (CIPOS). We herein present a case of CIPOS requiring colectomy and with good results.

Keywords

constipation, fecal impaction, intestinal pseudoobstruction, myotonic dystrophy.

tion and improved subsequently, tolerating oral feedings. This time, she was discharged with a regimen of povidone iodine enemas and 10 g lactulose orally twice daily.

She returned to the hospital again 3 months later, with similar symptoms (abdominal distention, retching, and lack of bowel movement for greater than 48 h). However, imaging at this admission did not show signs of obstruction. She responded well to standard cleanout with GoLyte[®] and was discharged with a new home regimen of PEG 3350 17 g BID and liquid senokot 5 mL once daily with an additional administration of a phosphate enema if no bowel movement for 48 h.

She returned with abdominal distention one month later. At this time, very dilated loops of bowel were noted on KUB (Fig. 2), similar to their appearance during her previous admissions. Full gastrointestinal motility studies revealed adequate antroduodenal motility with excellent response to azithromycin, however, colonic motility studies revealed a lack of rectoanal inhibitory response (RAIR) on anorectal manometry as well as lack of distal colonic response to bisacodyl.

Discussions of future medical management proved difficult, due to the patient's dysphagia (common in patients with myotonic dystrophy) and inability to swallow enteric coated bisacodyl. Another treatment option included cecos-

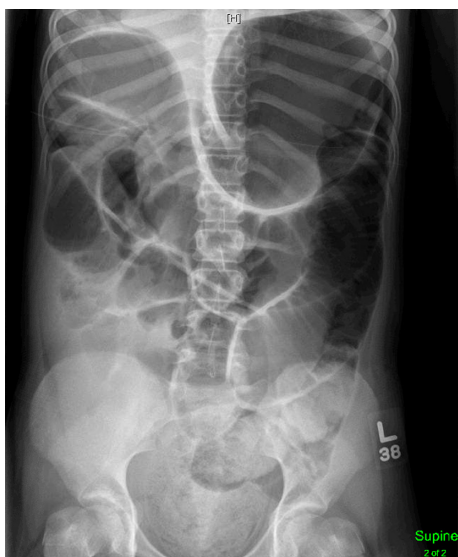

Figure 1. Abdominal radiograph, obtained supine on December 31, 2012. Markedly distended small and large bowel loops are shown. A large amount of stool is seen in the rectum, suggestive at this time of fecal impaction.

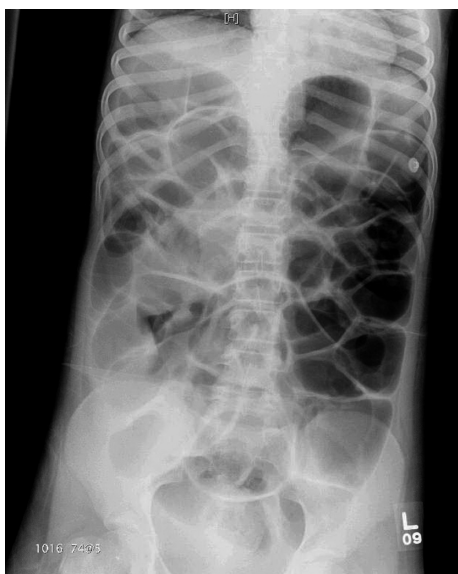

Figure 2. Abdominal flat plate film taken April 26, 2013, showing recurrence of marked gaseous distension of small and large bowel loops. Compared to Figure 1, significantly less fecal material is seen in the rectal vault.

tomy in order to instill a crushed bisacodyl tablet to increase colonic motility. It was decided to try continued medical management with carbamazepine for treatment of her myotonic dystrophy, as well as initiation of botulinum toxin injections to her internal anal sphincter in an effort to relieve the persistently high anal pressure. Following these

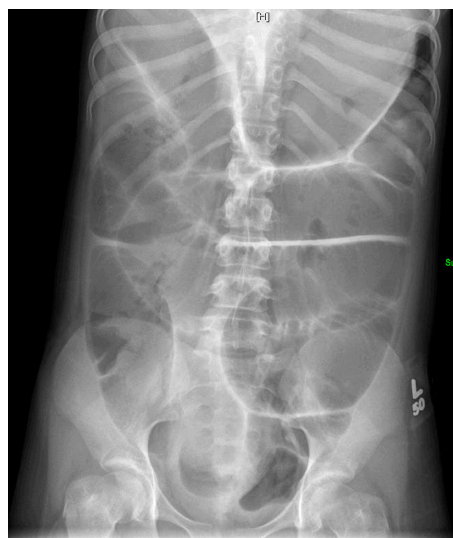


Figure 3. Abdominal flat plate radiograph, August 21, 2013. Severe gaseous distension of numerous loops of both small and large bowel is seen, similar in degree compared to Figure 1.

interventions, she was discharged home with a regimen of lactulose, senokot, and bisacodyl enemas twice weekly.

Despite strict compliance with medication regimen, the patient was admitted a fifth time with severely dilated loops of bowel on KUB without overt signs of obstruction. Conservative management with, nasogastric decompression followed by nasogastric PEG 3350 infusion allowed resolution of symptoms. The patient was discharged on PEG 3350, 17 g twice daily, with bisacodyl enemas twice weekly. Repeat anorectal manometry approximately 2 weeks later showed persistently reduced anal sphincter tone indicating a response to botulinum toxin injections. However, again in August of 2013 she presented with abdominal distention, retching, and dilated loops of bowel on plain film (Fig. 3). She was diagnosed at this point with chronic intestinal pseudoobstruction, specifically of the colon, a rarely described phenomenon in patients with myotonic dystrophy [1].

Because of persistent symptoms total abdominal colectomy with end ileostomy was performed in August, 2013. Since that time, the patient has gone 17 months without readmission for symptoms related to pseudoobstruction.

Discussion

Myotonic dystrophy (DM) is an autosomal dominant, highly variable, progressive neuromuscular disease, the phenotypic severity relating to the number of inherited trinucleotide repeats (CTG) [1]. The motility of the intestine is a function of the intestinal smooth muscle controlled by the enteric nervous system, and disturbances in

these two entities may lead to dysmotility. The fundamental nature of the disease process of DM is still debated. It is well documented that DM affects the smooth muscle of various organs, including the GI tract, in a manner similar to dystrophic skeletal muscle with swollen, partially destroyed smooth muscle cells that are progressively replaced by fat [2]. DM has been reported in the literature as a cause of severe colonic impaction and intestinal pseudoobstruction, although this complication appears to be rare. Brunner *et al.* described four cases of intestinal pseudoobstruction in 1992 due to myotonic dystrophy. One patient was treated with cisapride, a prokinetic, and did well. The other three had partial colectomies due to megacolon. Bruinenberg *et al.*, in 1996, also described a case of pseudoobstruction following appendectomy that was then determined to be to the result of DM [3]. Because the disease is relatively rare (incidence 1:8000), it is often not explained in detail in reviews of chronic intestinal pseudoobstruction syndrome [4,5], or it is not mentioned at all [6].

In this child, the symptoms appeared to be progressive rather than present from birth. Hypotonia and respiratory failure are typically the neonatal presenting symptoms. The others appear later in childhood (predominantly cardiac conduction abnormalities, feeding intolerance) and then progress. In the noncongenital forms, GI symptoms may be the first indication of a myotonic muscular dystrophy and can precede skeletal muscle findings by up to 10 years and may be limited to only part of the GI tract, as in our patient. The impairment of gastrointestinal function may be sometimes so gradual that the patients adapt to it with little awareness of symptoms [2]. This is likely due to progressive deposition of fat in the smooth muscle of the GI tract. However, one of our group (JMR) has encountered a case of pseudoobstruction in a newborn with myotonic dystrophy requiring prolonged parenteral nutrition.

Worsening in our patient occurred despite excellent clinical follow-up and perceived compliance with treatment. We initially suspected her problem was related to abnormally high internal and external anal sphincter pressures, secondary to her primary disease (myotonia and inability to relax after muscular contraction). However, the dilation of her small intestine provided evidence for a more widespread muscular disorder of the GI tract. We attempted treatment of her primary disease with carbamazepine, in an effort to combat the underlying patho-

physiology, but were unsuccessful as she continued to present with isolated colonic pseudoobstruction. Given that respiratory failure is common and often fatal in DM (up to 40% mortality) in the neonatal period [7], our case of congenital myotonic dystrophy is unusual in that her gastrointestinal disease has become her major limiting condition. Faure *et al.* demonstrated that despite surgical intervention, a significant number of pediatric patients with chronic intestinal pseudoobstruction remain dependent on artificial nutrition [5]. We are concerned that given the progressive nature of this disease, signs of small intestinal dilatation, and knowing that her colonic pseudoobstruction may progress to full chronic intestinal pseudoobstruction and result in a requirement for total parenteral nutrition in the future, despite current clinical improvement after colectomy.

Conflict of Interest

None declared.

References

1. Brook, J. D., M. E. McCurrach, H. G. Harley, A. J. Buckler, D. Church, H. Aburatani, *et al.* 1992. Molecular basis of myotonic dystrophy: expansion of a trinucleotide (CTG) repeat at the 3' end of a transcript encoding a protein kinase family member. *Cell* 68:799–808.
2. Bellini, M., S. Biagi, C. Stasi, F. Costa, M. G. Mumolo, A. Ricchiuti, *et al.* 2006. Gastrointestinal manifestations in myotonic muscular dystrophy. *World J. Gastroenterol.* 12:1821–1828.
3. Bruinenberg, J. F., P. N. Rieu, F. M. Gabreels, and J. Tolboom. 1996. Intestinal pseudo-obstruction syndrome in a child with myotonic dystrophy. *Acta Paediatr.* 85:121–123.
4. Connor, F. L., and L. C. Di. 2006. Chronic intestinal pseudo-obstruction: assessment and management. *Gastroenterology* 130(2 Suppl 1):S29–S36.
5. Faure, C., O. Goulet, S. Ategbo, A. Breton, P. Tounian, J. L. Ginies, *et al.* 1999. Chronic intestinal pseudoobstruction syndrome: clinical analysis, outcome, and prognosis in 105 children. *French-Speaking Group of Pediatric Gastroenterology. Dig. Dis. Sci.* 44:953–959.
6. Gabbard, S. L., and B. E. Lacy. 2013. Chronic intestinal pseudo-obstruction. *Nutr. Clin. Pract.* 28:307–316.
7. Prendergast, P., S. Magalhaes, and C. Campbell. 2010. Congenital myotonic dystrophy in a national registry. *Paediatr. Child Health* 15:514–518.