

Impairments of Visual Function and Ocular Structure in Patients With Unilateral Posterior Lens Opacity

Duoru Lin^{1,*}, Jingjing Chen^{1,*}, Zhenzhen Liu^{1,*}, Zhuoling Lin¹, Xiaoyan Li¹, Xiaohang Wu¹, Qianzhong Cao¹, Haotian Lin¹, Weirong Chen¹, and Yizhi Liu¹

¹ State Key Laboratory of Ophthalmology, Zhongshan Ophthalmic Center, Sun Yat-sen University, Guangzhou, Guangdong, 510060, People's Republic of China

Correspondence: Haotian Lin, PhD, Zhongshan Ophthalmic Center, Xian Lie South Rd #54, Guangzhou, China, 510060. e-mail: gddlht@aliyun.com

Weirong Chen, MD, Zhongshan Ophthalmic Center, Xian Lie South Rd #54, Guangzhou, China, 510060. e-mail: chenwr_q@aliyun.com

Received: 3 January 2018

Accepted: 6 June 2018

Published: 24 July 2018

Keywords: congenital cataract; posterior cataract; visual function; visual evoked potential; visual impairment

Citation: Lin D, Chen J, Liu Z, Lin Z, Li X, Wu X, Cao Q, Lin H, Chen W, Liu Y. Impairments of visual function and ocular structure in patients with unilateral posterior lens opacity *Trans Vis Sci Tech.* 2018;7(4):9. <https://doi.org/10.1167/tvst.7.4.9> Copyright 2018 The Authors

Purpose: We investigate visual function impairment and ocular structure in patients with unilateral posterior lens opacity, a type of congenital cataract (CC) in our novel CC category system.

Methods: We studied patients aged 3 to 15 years who were diagnosed with unilateral posterior CC. Best corrected visual acuity (BCVA) and visual evoked potentials (VEP) were examined. Corneal astigmatism (CA), mean keratometry, central corneal thickness, anterior chamber depth (ACD), and axial length were measured by Pentacam and IOL-Master. Variations between two eyes were compared by paired *t*-tests.

Results: Among the 25 patients involved, BCVAs (logMAR) of cataractous and contralateral healthy eyes were 0.8 ± 0.4 (range, 0.1–1.7) and 0.1 ± 0.1 (range, –0.1 to 0.4). Compared to contralateral healthy eyes, larger CA (1.8 ± 1.2 vs. 0.9 ± 0.4 diopters [D], $P = 0.002$) and deeper ACD (3.7 ± 0.3 vs. 3.5 ± 0.4 mm, $P = 0.009$) were found in cataractous eyes. No significant positive or negative linear relationship was found between BCVA and parameters of VEP. Peak time of P100 of pattern VEP-60' in cataractous eyes was longer than that in contralateral healthy eyes (114.9 ± 18.8 vs. 105.0 ± 12.4 ms, $P = 0.013$). Amplitudes of P100 of patterns VEP-60' and -15' in cataractous eyes were smaller than those in contralateral healthy eyes (PVEP-60', 15.2 ± 5.3 vs. 19.9 ± 10.4 μ V, $P = 0.023$; PVEP-15', 10.4 ± 7.0 vs. 22.1 ± 11.9 μ V, $P = 0.012$).

Conclusions: Impaired visual function and ocular structure were detected in patients with posterior lens opacities.

Translational Relevance: This study provides evidence-based clinical recommendations for unilateral posterior CC patients with controversial treatment options.

Introduction

Congenital cataracts (CC) have remained a leading cause of treatable childhood blindness, with a worldwide prevalence of 4.24/10000.¹ Due to the complex etiology with polygenic involvement, patients with CC exhibit a wide range of clinical lens opacity presentations.² We recently proposed a novel CC category system (total, anterior, interior, and posterior cataracts) based on the position of lens opacities and their anterior segment characteristics, with the aim to facilitate diagnosis and treatment of CC.³ Our findings suggested that genetic and other

nongenetic factors that caused CC also may affect the cornea, iris, and other anterior segment tissues.⁴ Patient treatment plans should vary according to the specific CC categories to achieve a better treatment effect. Greater corneal astigmatism in anterior cataract and potential shallow anterior chambers in total cataract patients require appropriate management during the treatment process. Undoubtedly, surgical procedures should be performed as early as possible after diagnosis of dense total cataracts.^{5,6} However, the best timing of surgery for unilateral posterior cataracts, with seemingly mild opacities, but an unknown extent of visual impairments, remains

unclear. Presently, the most commonly used visual functional impairment assessment method for patients with CC is subjective visual acuity measurement, which is severely affected by lens opacities and cannot truly represent the functional integrity of the retina, visual pathway, and visual cortex of patients with CC. Visual evoked potentials (VEP) have been reported previously as a useful objective method to assess visual function with minimal influences of lens opacity.^{7,8} Combining VEP technique and three-dimensional (3D) imaging in our study, we comprehensively analyzed the alterations of visual function and ocular structure in patients with unilateral posterior CC to further explore the clinical treatment guidance provided by our novel CC category system.

Materials and Methods

Subjects and Ethical Statements

This study was included in our series of ongoing studies for the Childhood Cataract Program of the Chinese Ministry of Health (CCPMOH),⁹ a national project for CC treatment and research supported by the Zhongshan Ophthalmic Center (ZOC). Patients with CC aged 3 to 15 years who sought treatment at the ZOC from May 2015 to August 2016 were included in the current study. All participants were diagnosed with unilateral CC, which was classified as posterior cataractous based on slit-lamp and 3D ocular examinations (Fig. 1). Lens opacities that involved the posterior capsules were defined as posterior cataracts, and a more detailed description of our novel CC category system has been reported previously.³ Patients with complications due to other ocular abnormalities, such as nanophthalmos, glaucoma, severe corneal diseases, lens luxation, retinal diseases, strabismus, and nystagmus, were excluded. This study was approved by the Human Research Ethics Committee of the ZOC, Sun Yat-sen University. All procedures adhered to the tenets of the Declaration of Helsinki, and written informed consent was obtained from the legal guardian of each patient after a detailed explanation of the nature and possible consequences of the study.

Basic Patient Information and Measurements of Ocular Structure

The basic information of all patients was collected, including age, sex, and eye laterality. Best corrected visual acuity (BCVA) was determined by subjective

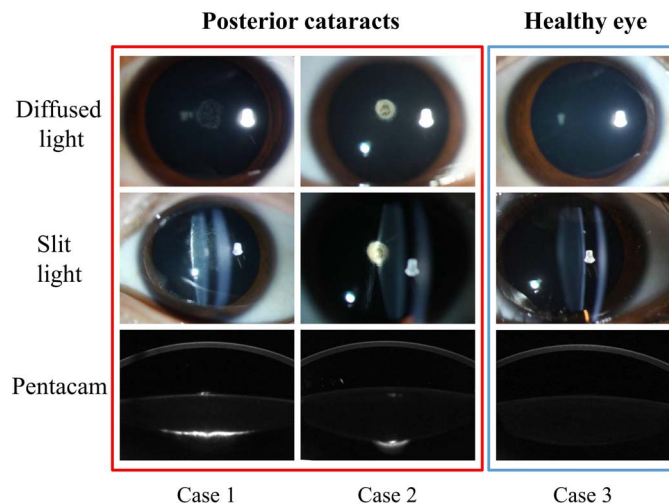


Figure 1. Diagrams of posterior cataracts, one type of our novel congenital cataract category system.

refraction with E optotype on a projector. Intraocular pressure (IOP) was measured by a noncontact tonometer (TX-F; Canon, Tokyo, Japan) and the normal range was set from 10 to 21 mmHg.¹⁰ Anterior segment biological parameters were measured in an undilated pupil before surgical treatment, including corneal astigmatism (CA), mean keratometry (km), central corneal thickness (CCT), and anterior chamber depth (ACD). The definitions of the anterior segment parameters also were described in detail previously.¹¹ Measurements were obtained with a 3D anterior segment imaging and analysis system (Pentacam HR; Oculus, Inc., Wetzlar, Germany), which is a commercially available camera based on the Scheimpflug principle. Furthermore, axial length (AL) also was measured using an IOL-Master (Carl Zeiss Meditec AG, Jena, Germany). All ocular biological structure parameters were measured by two experienced examiners (ZLL and XYL), and the mean of three measurements that met the quality standards was calculated for each parameter.

VEP Examinations

The VEP of patients with CC were examined in a darkroom with MonPackONE (Metrovision, Perenchies, France) by two experienced ophthalmologists (DRL and JJC). Before VEP examination, patients with undilated pupils were required to spend at least 10 minutes staying in the darkroom with a light-proof eye mask while seated. After adaptations, the eye without cataract was first examined to ensure the patient was familiar with the examination process, followed by the cataractous eye. The untested eye was

covered by the light-proof eye mask throughout the examination. Flash VEP (FVEP) examination was performed for patients with a BCVA < 1.0 (log-MAR). FVEP, pattern-reversal VEP-60' (PVEP-60'), and PVEP-15' were performed for patients with a BCVA \geq 1.0 (LogMAR). Refractive error was corrected by an optical lens before PVEP examinations.¹² Electrode cupules (Ag/AgCl) were used and placed on the head before flash or pattern stimulations. Electrode placement was set strictly according to the "10-20 International System," which is based on measurements of head size.¹³ The active electrode was placed at point Oz along the midline of scalp. The reference electrode was located at point Fz, while one earlobe served as the ground location. The VEP parameters were set as follows: test distance, 0.30 m for FVEP and 1.0 m for PVEP; stimulation intensity of FVEP, 3.0 cd.s./m²; flashing time, 5.0 ms; stimulation interval, 1.0 s for PVEP and FVEP; luminance of the screen for PVEP, 100 cd/m² (stimulation on); 5.49 cd/m² (stimulation off); 53.7 cd/m² (mean); contrast of the black-and-white checkerboard, 100%; valid responses, 60 times for PVEP and FVEP; Reliability (a proprietary index provided by the instrument), >95%; parameters of filters, 1.0 Hz for high pass filter; and 100 Hz for low pass filter. Two near infrared video cameras equipped in MonPackONE were used for monitoring fixation: one near test camera for FVEP tests performed at 0.30 m and one distance test camera for PVEP tests performed at 1.0 m. No artifact-rejection algorithm was used in our study. Examples of FVEP and PVEP traces from two patients are presented in Figure 2, the peak times and amplitudes of the P2 wave of FVEP and the P100 wave of PVEP were recorded and compared.

Statistical Analysis

All statistical analyses were performed using the Statistical Package for the Social Sciences (SPSS ver. 19.0; SPSS, Inc., Chicago, IL). All continuous variables, including age, BCVA, IOP, ocular structure measurements, peak time, and VEP amplitude, were recorded as the mean \pm SD. Normal distributions of age, BCVA, IOP, ocular structure measurements, peak time, and VEP amplitude were tested using the Shapiro-Wilk test. Differences between cataractous and contralateral healthy eyes regarding the aforementioned parameters were measured by a paired *t*-test. The relationships between BCVA and VEP parameters were calculated by partial correlation

analysis with age controlled. The level of significance was $P < 0.05$.

Results

We studied 25 patients with unilateral posterior CC (10 girls, 15 boys; mean age, 73.3 ± 28.0 months/ 5.6 ± 2.4 years, range, 39–164 months/3.3–14.0 years). BCVA of cataractous eyes was worse than that of the contralateral healthy eyes ($t = 9.872$, $P < 0.001$), and no difference in the IOP between two eyes was found ($t = -0.91$, $P = 0.38$; Fig. 3).

The ocular structure parameters are shown in Table 1, including CA, km, CCT, ACD, and AL. Compared to contralateral healthy eyes, larger CA and deeper ACD were found in cataractous eyes ($P = 0.002$ and 0.009 , respectively).

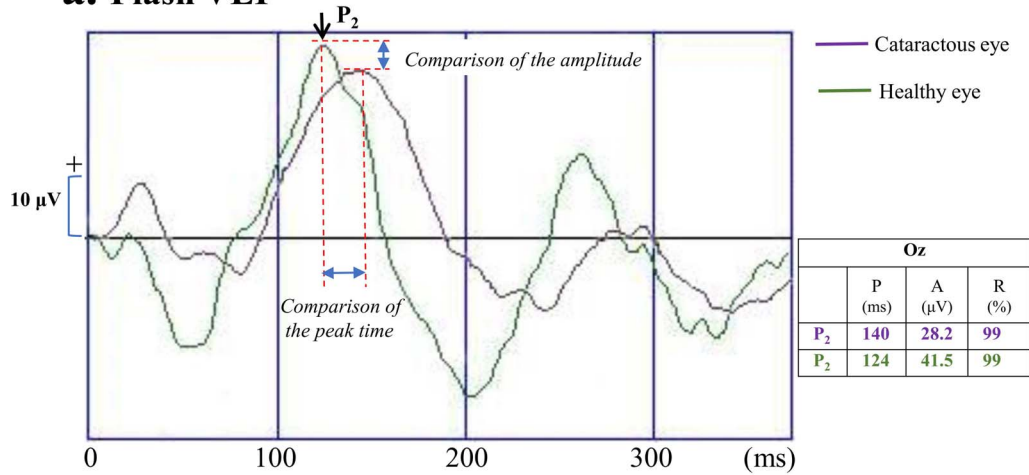
All 25 patients completed the FVEP examinations, and 20 and 11 successfully completed PVEP-60' and PVEP-15' examinations, respectively. The relationships between visual acuity and VEP parameters in young patients were further analyzed (Fig. 4). Slight positive relationships between BCVA and peak time of VEP (PVEP-60' and -15' Figs. 4c, 4e) and negative relationships between BCVA and VEP amplitude (FVEP and PVEP-15'; Figs. 4b, 4f) were revealed. However, no linear relationships between BCVA and VEP parameters were statistically significant (P values of partial correlation analysis ranged from 0.149–0.994).

The peak time and amplitude of FVEP, PVEP-60', and PVEP-15' between cataractous and contralateral healthy eyes also were compared using a paired *t*-test. The peak time of P100 of PVEP-60' in cataractous eyes was longer than that in contralateral healthy eyes (114.9 ± 18.8 vs. 105.0 ± 12.4 ms, $t = 2.74$, $P = 0.013$; Fig. 5). Amplitudes of P100 of patterns PVEP-60' and -15' in cataractous eyes were smaller than those in contralateral healthy eyes (PVEP-60', 15.2 ± 5.3 vs. 19.9 ± 10.4 μ V, $t = -2.47$, $P = 0.023$; PVEP-15', 10.4 ± 7.0 vs. 22.1 ± 11.9 μ V, $t = -3.00$, $P = 0.012$).

Discussion

We recently proposed a novel CC category system, including total, anterior, interior, and posterior cataracts, based on the anterior segment characteristics, with the aim of facilitating CC treatment. Posterior CC, one type of CC (based on our novel category system) with seemingly mild lens opacity and a small affected area, has the most controversial

a. Flash VEP



b. Pattern-reversal VEP

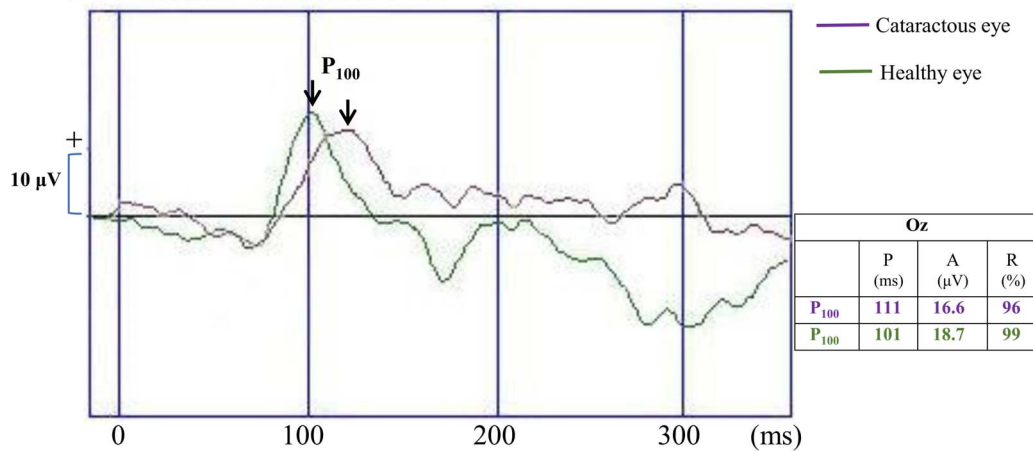
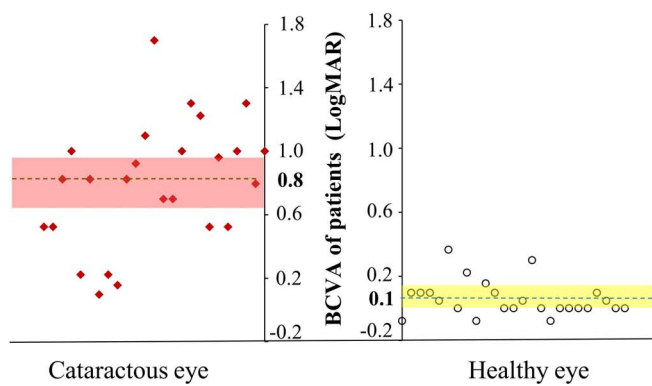


Figure 2. Examples of FVEP and PVEP traces. The traces of healthy and cataractous eyes were artificially overlapped for a better comparison and illustration. (a) These FVEP traces were obtained from two eyes of a 5-year-old boy (patient CJX). (b) These PVEP-60' traces were obtained from two eyes of a 4.5-year-old girl (patient HXY). FVEP, flash visual evoked potentials; P, peak time; A, amplitude; R, reliability.

a. BCVA



b. IOP

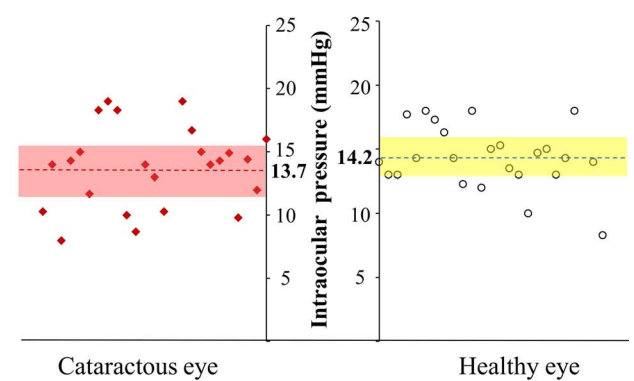


Figure 3. Comparisons of BCVA and IOP between cataractous eyes and contralateral healthy eyes. The dotted lines indicate the mean values, the red and yellow bands on both Figures indicate 95% confidence intervals.

Table 1. Comparisons of the Ocular Biological Structure Parameters Between Cataractous and Contralateral Healthy Eyes

	Cataractous Eye	Healthy Eye	<i>t</i>	<i>P</i>
CA (D)	1.8 ± 1.2	0.9 ± 0.4	3.54	0.002*
Km (D)	43.5 ± 1.6	42.9 ± 0.9	1.80	0.09
CCT (μm)	542.6 ± 40.4	538.8 ± 36.4	0.41	0.68
ACD (mm)	3.7 ± 0.3	3.5 ± 0.4	2.89	0.009*
AL (mm) ^a	22.6 ± 1.8	22.4 ± 0.5	0.55	0.59

D, diopters.

^a Available for 15 children;

* Paired *t*-test, statistically significant at *P* < 0.05.

treatment option among all categories. In our study, we comprehensively investigated the influences of unilateral posterior lens opacity on visual function and ocular structure in patients with posterior CC and further explored the clinical treatment guidance of our novel CC category system for CC patients.

Alteration of ocular structure parameters is the most direct marker of visual impairment in CC patients. Similar to other reports^{14,15} and to our previous study,¹¹ larger CA and deeper ACD were found in cataractous than in healthy contralateral eyes in our study. The higher CA in eyes with CC likely resulted from a delayed separation of the lens from the surface ectoderm during fetal development.¹⁶ The deeper ACD in patients with CC may be explained by the special type of cataracts in our study. According to the novel CC category system related to anterior segment characteristics proposed by Lin et al.,³ eyes with posterior cataracts trended toward deeper ACD than eyes with a clear lens, which is consistent with our current findings. Inappropriate management of the larger CA and deeper ACD can lead to development of an unexpected refractive error and, therefore, requires attention.

Ocular structure is the foundation of visual function; thus, we analyzed the functional impairments of patients with posterior CC that were caused by the reported abnormal ocular structures. The influence of lens opacity on visual function can be reflected directly by decreased visual acuity, and the BCVAs of cataractous eyes were significantly worse than those of contralateral healthy eyes. However, visual acuity that is severely affected by lens opacities, can merely show the current visual condition of patients with CC and cannot truly reflect the functional integrity of the retina and visual pathway independent of lens opacity. VEP, which originates in

the visual cortex and can be extracted from brain waves by repeated superposition averaging, has been reported previously as a useful objective method to assess visual function with minimal impact of lens opacity.¹⁷ We also analyzed the relationships between BCVA and VEP parameters, where no significant linear relationship was found, which further confirms the different aspects of vision reflected by BCVA and VEP examinations. However, slight linear relationships between BCVA and VEP parameters were revealed in PVEP-15' (BCVA and peak time, PCC = 0.383; BCVA and amplitude, PCC = -0.455). The relationship between visual acuity and PVEP parameters with small checkerboard still required further investigation. Compared to contralateral healthy eyes, prolonged peak time and smaller amplitudes of cataractous eyes were detected in patients with unilateral posterior CC, which is consistent with previous findings.¹⁸ The prolonged peak time and small amplitudes may have resulted from deprivation amblyopia caused by congenital lens opacities. Competition and suppression between two eyes in unilateral patients prevent the affected eye from normal visual stimulation that promotes healthy development of visual function during the sensitive period, which is reflected by the weakened VEP response in our study. Therefore, surgical treatment should be considered in posterior CC patients, even though this CC condition has mild and small-area lens opacities. However, the prognosis of patients with amblyopic unilateral CC remains unfavorable, even after surgical intervention at 6 weeks of age.¹⁹ Meanwhile, mean patient age in our study was 73.3 months, indicating that delayed treatment of unilateral CC remains common in China. Thus, better education regarding CC management and a detailed explanation of the potential for poor postoperative

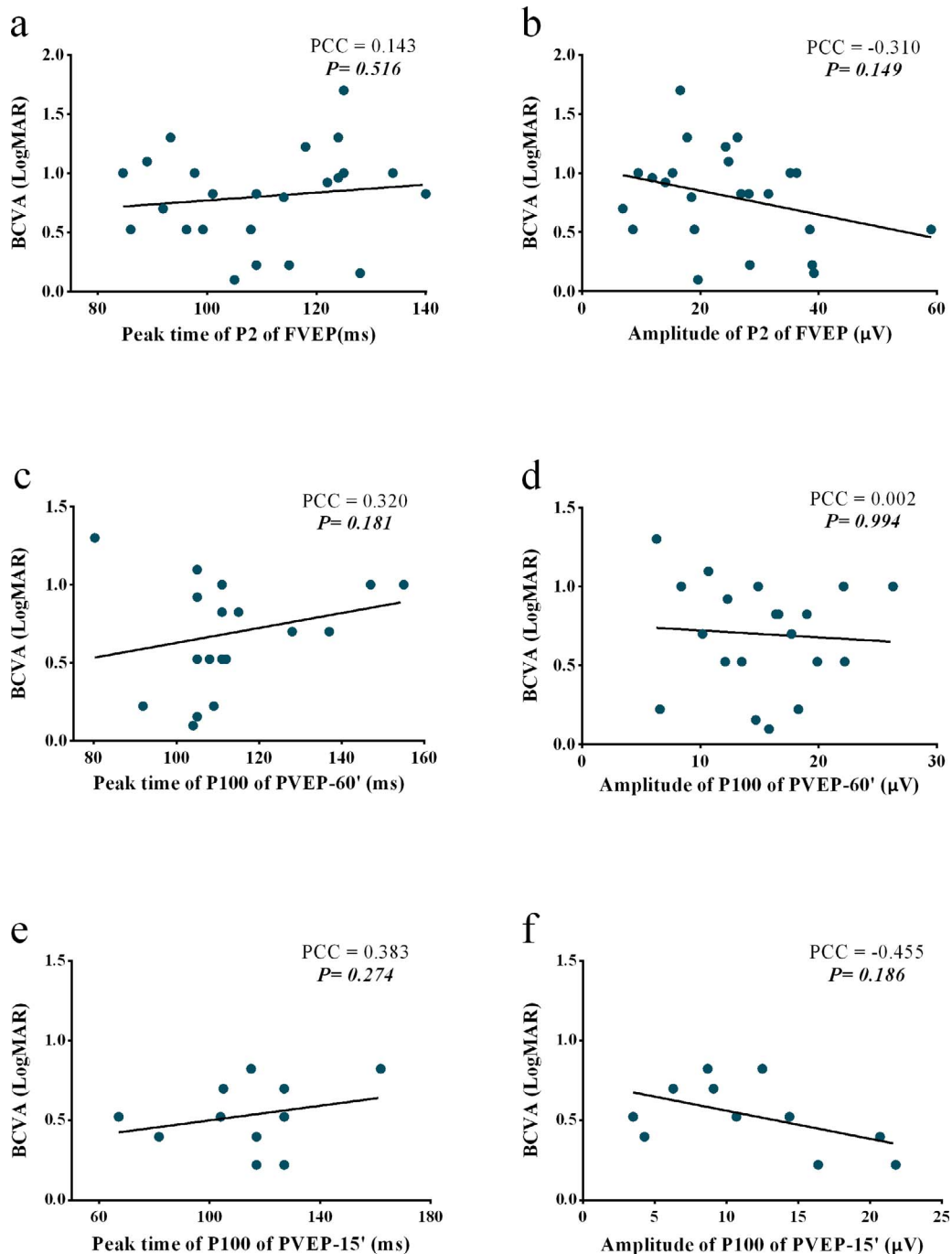


Figure 4. Scatterplots for BCVA and VEP parameters in cataractous eyes of patients with unilateral posterior CC. No significant linear relationship was found between BCVA and VEP parameters. Number of patients: 25 in (a) and (b); 20 in (c) and (d); 11 in (e) and (f); PCC, partial correlation coefficient.

visual function for this type of CC are essential for parents of patients with CC.

Our study has certain limitations. First, only 11 patients were tested successfully by PVEP-15' examinations; others failed due to poor vision of the

affected eye, low reliability index of examination, or indistinguishable P100 waveform. Therefore, the relationship between BCVA and FVEP-15' parameters, as well as the comparison of FVEP-15' parameters between affected and healthy eyes in

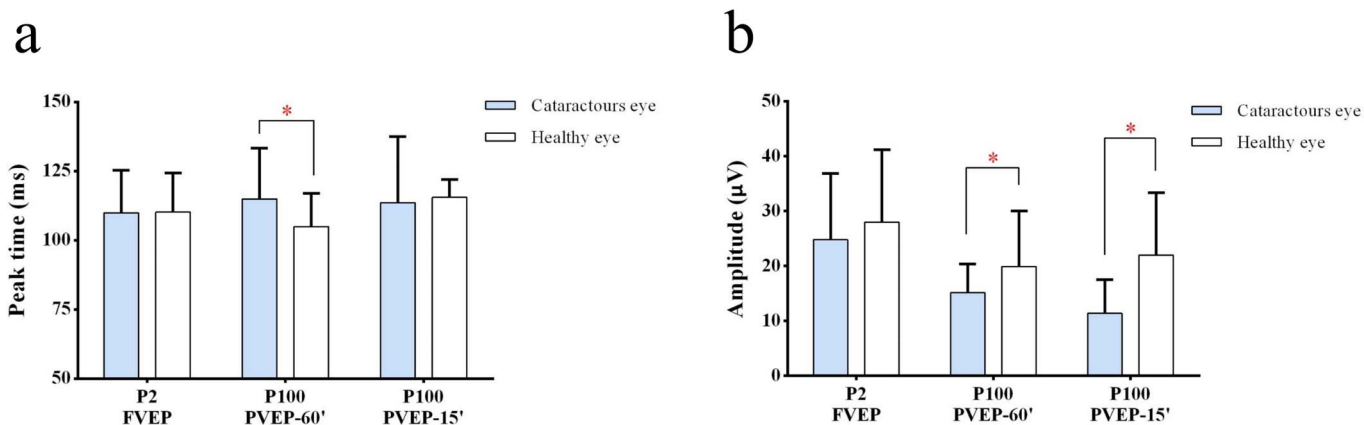


Figure 5. Comparisons of the peak time and amplitude of VEP between both eyes of patients with unilateral posterior CC. (a) The peak time of P100 of PVEP-60' in cataractous eyes was longer than that in contralateral healthy eyes. (b) The amplitudes of P100 of patterns VEP-60' and -15' in cataractous eyes were smaller than those in contralateral healthy eyes. Error bar: standard deviation; * Paired *t*-test, statistically significant at $P < 0.05$.

unilateral posterior CC patients revealed in our study should be interpreted with caution. Second, because it is difficult for young children to cooperate in the examinations for a long time, each VEP condition was recorded only once with 60 valid responses overlaying and averaging. Third, the influence of age on VEP parameters should be addressed carefully so that VEP responses of young patients may not be completely matured. Peak time of VEP showed maturational changes and continued to decrease until different reported ages (most of which were before 1 year).^{20–23} In our study, all participants were >3.5 years old (mean age, 5.6 years), which could minimize the effects of the confounding factor of age. However, previous studies revealed that amplitude matured much slower than peak time.^{24,25} Therefore, we further statistically controlled the effects of age by partial correlations analysis when calculating the relationships between BCVA and VEP parameters. Furthermore, retinal function was not evaluated in our study. An objective examination, such as electroretinogram, of retinal function would be included to rule out mild retinal dysfunction in our next study. Additionally, the relatively small number of patients with unilateral posterior CC still limits the extent to which the results can be generalized. Finally, because this was a preliminary study, only one type of our novel CC category system with controversial treatment options was evaluated. The visual function of other CC types still requires further investigations.

Nevertheless, we comprehensively evaluated visual function and ocular structure of patients with unilateral posterior CC, one type of CC in our novel

CC category system with two controversial treatment options. According to our results, impaired visual function and ocular structure were detected in patients with posterior lens opacity. Timely surgery and a detailed explanation of the potential for poor postoperative visual function in this type of CC can be considered. This study could provide a reference for further study of visual impairments for other types of CC in our novel CC category system and promote clinical treatment guidance effects of our novel CC category system.

Acknowledgments

Supported by the National Natural Science Foundation of China (NSFC; 81770967, 91546101, 81300750), Clinical Research and Translational Medical Center of Pediatric Cataract in Guangzhou City (201505032017516), Youth Pearl River Scholar Funded Scheme (2016–2018), Guangdong Provincial Foundation for Medical Scientific Research (A2015340), and Fundamental Research Funds for the Central Universities (16ykjc28).

The sponsors of the study had no role in the study protocol design, data collection, data analysis, data interpretation, manuscript preparation, or decision to submit the manuscript for publication.

DRL, JJC, and HTL contributed to the conception or design of the work; DRL, JJC, ZZL, XHW, QZC, and ZLL contributed to the acquisition of

data; DRL and XYL contributed to the analysis; DRL, JJC, and ZZL contributed to the interpretation of data for the work; and HTL and DRL contributed to drafting the work and revising it critically for important intellectual content. All authors gave final approval of the version to be published; HTL, WRC, and DRL agree to be accountable for all aspects of the work.

Disclosure: **D. Lin**, None; **J. Chen**, None; **Z. Liu**, None; **Z. Lin**, None; **X. Li**, None; **X. Wu**, None; **Q. Cao**, None; **H. Lin**, **W. Chen**, None; **Y. Liu**, None

*DL, JC, and ZL contributed equally to this article.

References

1. Wu X, Long E, Lin H, Liu Y. Prevalence and epidemiological characteristics of congenital cataract: a systematic review and meta-analysis. *Sci Rep*. 2016;6:28564.
2. Reddy MA, Francis PJ, Berry V, Bhattacharya SS, Moore AT. Molecular genetic basis of inherited cataract and associated phenotypes. *Surv Ophthalmol*. 2004;49:300–315.
3. Lin H, Lin D, Liu Z, et al. A novel congenital cataract category system based on lens opacity locations and relevant anterior segment characteristics. *Invest Ophthalmol Vis Sci*. 2016;57:6389–6395.
4. Datiles MB, Hejtmancik JF. Congenital cataracts: classification and association with anterior segment abnormalities. *Invest Ophthalmol Vis Sci*. 2016;57:6396.
5. Zhang L, Wu X, Lin D, et al. Visual outcome and related factors in bilateral total congenital cataract patients: a prospective cohort study. *Sci Rep*. 2016;6:31307.
6. Zhu M, Zhu J, Lu L, He X, Zhao R, Zou H. Four-year analysis of cataract surgery rates in Shanghai, China: a retrospective cross-sectional study. *BMC Ophthalmol*. 2014;14:3.
7. Fuest M, Plange N, Jamali S, et al. The effect of cataract surgery on blue-yellow and standard-pattern visual-evoked potentials. *Graef's Arch Clin Exp Ophthalmol*. 2014;52:1831–1837.
8. Fuest M, Kieckheofel J, Mazinani B, et al. Blue-yellow and standard pattern visual evoked potentials in phakic and pseudophakic glaucoma patients and controls. *Graef's Arch Clin Exp Ophthalmol*. 2015;53:2255–2261.
9. Lin D, Chen J, Lin Z, et al. 10-year overview of the hospital-based prevalence and treatment of congenital cataracts: the CCPMOH experience. *PLoS One*. 2015;10:e0142298.
10. Lin H, Chen W, Luo L, et al. Ocular hypertension after pediatric cataract surgery: baseline characteristics and first-year report. *PLoS One*. 2013;8:e69867.
11. Lin D, Chen J, Liu Z, et al. Prevalence of corneal astigmatism and anterior segmental biometry characteristics before surgery in Chinese congenital cataract patients. *Sci Rep*. 2016;6:22092.
12. Creel DJ. Visually evoked potentials. In: Kolb H, Fernandez E, Nelson R, eds. *Webvision: The Organization of the Retina and Visual System*. Salt Lake City, UT: University of Utah Health Sciences Center; 1995.
13. Odom JV, Bach M, Brigell M, et al. ISCEV standard for clinical visual evoked potentials: (2016 update). *Doc Ophthalmol Adv Ophthalmol*. 2016;133:1–9.
14. Watanabe T, Matsuki N, Yaginuma S, Nagamoto T. [Corneal astigmatism in children with congenital cataract]. *Nippon Ganka Gakkai Zasshi*. 2014;118:98–103.
15. Trivedi RH, Wilson ME. Biometry data from Caucasian and African-American cataractous pediatric eyes. *Invest Ophthalmol Vis Sci*. 2007;48:4671–4678.
16. Bouzas AG. Anterior polar congenital cataract and corneal astigmatism. *J Pediatr Ophthalmol Strab*. 1992;29:210–212.
17. Lin D, Chen J, Lin H, Chen W. Application of visual electrophysiology for the diagnosis and treatment of cataracts. *Eye Sci*. 2015;30:190–197.
18. McCulloch DL, Skarf B. Pattern reversal visual evoked potentials following early treatment of unilateral, congenital cataract. *Arch Ophthalmol*. 1994;112:510–518.
19. Eizenbaum F, Salomao SR, Berezovsky A, et al. Amblyopia after unilateral infantile cataract extraction after six weeks of age. *Arq Bras Ophthalmol*. 2009;72:645–649.
20. Lenassi E, Likar K, Stirn-Kranjc B, Breclj J. VEP maturation and visual acuity in infants and preschool children. *Doc Ophthalmol Adv Ophthalmol*. 2008;117:111–120.
21. Kraemer M, Abrahamsson M, Sjostrom A. The neonatal development of the light flash visual evoked potential. *Doc Ophthalmol Adv Ophthalmol*. 1999;99:21–39.
22. Benavente I, Tamargo P, Tajada N, Yuste V, Oliván MJ. Flash visually evoked potentials in the newborn and their maturation during the first

- six months of life. *Doc Ophthalmol Adv Ophthalmol*. 2005;110:255–263.
23. McCulloch DL, Skarf B. Development of the human visual system: monocular and binocular pattern VEP latency. *Invest Ophthalmol Vis Sci*. 1991;32:2372–2381.
 24. Madrid M, Crognale MA. Long-term maturation of visual pathways. *Vis Neurosci*. 2000;17:831–837.
 25. Mahajan Y, McArthur G. Maturation of visual evoked potentials across adolescence. *Brain Devel*. 2012;34:655–666.