

This article is licensed under the Creative Commons Attribution-NonCommercial 4.0 International License (CC BY-NC) (<http://www.karger.com/Services/OpenAccessLicense>). Usage and distribution for commercial purposes requires written permission.

Case Report

Hyperpigmented Torpedo Maculopathy with Pseudo-Lacuna: A 5-Year Follow-Up

Austin Rohl^a Sushma Vance^{a, b}

^aUniversity of Central Florida College of Medicine, Orlando, Fla., USA; ^bCentral Florida Retina, Orlando, Fla., USA

Keywords

Torpedo maculopathy · Paramacular coloboma · Optical coherence tomography · Fundus autofluorescence · Retinal pigment epithelium

Abstract

Purpose: The aim of the study was to describe a case of globally hyperpigmented torpedo maculopathy that also contained a novel central lesion resembling a 'pseudo-lacuna'. We compare the morphology of the lesion after 5 years of follow-up. **Case Presentation:** An asymptomatic 10-year-old Caucasian male was referred by his optometrist after having found a hyperpigmented lesion on routine dilated examination in 2010. Color fundus photography OS from October 2015 showed a 1.74 × 0.67 mm hyperpigmented oval-shaped lesion temporal to the macula. Since June 2010, the hyperpigmented torpedo lesion appeared to have assumed a more ovoid shape and increased in size in the vertical axis. Centrally, there was a small pearlescent-colored pseudo-lacuna lesion that seemed to also have significantly increased in size since June 2010. Enhanced depth imaging optical coherence tomography of this pseudo-lacuna showed retinal pigment epithelium clumping and migration. Fundus autofluorescence revealed reduced autofluorescence of the torpedo lesion and marked hyperautofluorescence of the pseudo-lacuna. Fluorescein angiography shows no neovascular disease or leakage. **Conclusion:** Torpedo maculopathy has been described previously as a hypopigmented, nonprogressive lesion of unknown etiology. The findings of global hyperpigmentation, pseudo-lacuna formation, and morphologic changes over time in this lesion challenge these classically held descriptions, and necessitate long-term follow-up with multimodal imaging.

© 2016 The Author(s)

Introduction

Torpedo maculopathy is a rare, typically hypopigmented, oval-shaped lesion of the retinal pigment epithelium (RPE) that usually presents as an incidental finding upon examination. It was first described in 1992 by Roseman and Gass [1] in a 12-year-old boy. The term 'torpedo maculopathy' was later introduced by Daily [2] in 1993, given its characteristic torpedo-like tip that points towards the fovea.

The vast majority of reported cases of torpedo maculopathy are visually asymptomatic, although some have shown a corresponding scotoma [3]. The natural history of the lesion is not well studied, and the longest follow-up to date is 5 years [4]. Past authors have suggested that torpedo maculopathy is nonprogressive in both appearance and function [3, 5]; however, some recent studies indicate gradual structural and functional changes over time [4, 6]. The origins of this lesion remain unclear although previous reports have suggested abnormal nerve fiber layer, faulty development of the choroid, malformation of the long posterior ciliary neurovascular bundle, or a persistent defect in RPE development at the fetal temporal bulge [3, 7, 8].

In this report, we describe color fundus photography, fundus autofluorescence (FAF), fluorescein angiography (FA), and enhanced depth imaging optical coherence tomography (EDI-OCT) findings in a 15-year-old male patient with torpedo maculopathy. To our knowledge, we are identifying the first case of torpedo maculopathy that is globally hyperpigmented, as well as describing a novel central lesion within the torpedo resembling a 'pseudo-lacuna'. Also important to our study is a fundus photograph from 5 years ago, showing significant morphological changes over time. These multimodal findings further clarify the etiology of this rare lesion, and challenge the classic description of torpedo maculopathy as a nonprogressive and primarily hypopigmented lesion.

Case Report

A 10-year-old Caucasian male was referred by his optometrist due to a 'chorioretinal scar' found incidentally in the left eye during a routine dilated examination in 2010. The patient had no ocular complaints and his best-corrected visual acuity was 20/20 OU. The patient had no significant past medical or ocular history, including exposure to retinotoxic drugs or infectious processes such as toxoplasmosis. There was no known family ocular history. Observation was elected and a fundus photograph was taken at this time.

The patient returned for a routine follow-up visit in 2015. He remained asymptomatic and there was no change in vision and no new medical history. Color fundus photography from October 2015 (fig. 1b) shows a well-defined, ovoid-shaped, hyperpigmented lesion that is 1.74 × 0.67 mm in size and temporal to the macula. It is surrounded by a halo of patchy hypopigmentation. Color fundus photography from June 2010 (fig. 1a) shows the same lesion 5 years ago.

Over these 5 years, the hyperpigmented torpedo lesion appears to have assumed a more ovoid shape and increased in size in the vertical axis. There also seems to be a change in the area of the surrounding hypopigmentation, most notably an increased amount of hypopigmentation superonasal to the lesion. The appearance of a small, hypopigmented, almost pearlescent-colored spot becomes more apparent in the 2015 image (arrow in fig. 1b). The

same hypopigmented spot can also be seen in the photo from 2010, although it was much smaller at that time (fig. 1a).

EDI-OCT of the lesion from 2015 demonstrates RPE clumping and migration that corresponds to the pseudo-lacuna (fig. 2a). There is also disruption of the ellipsoid zone and mild thinning of the outer retina, which is overlying a subretinal cleft (fig. 2b). The inner retinal layers appear normal and well organized. The choroid beneath the lesion demonstrates hyporeflectivity and normal choroidal thickness.

FAF reveals globally reduced autofluorescence of the hyperpigmented torpedo lesion with a surrounding rim of hyperautofluorescence. The pseudo-lacuna lesion demonstrates an area of markedly increased autofluorescence (fig. 3).

Early and late phases of FA show a hypofluorescent lesion with a rim of hyperfluorescence (fig. 4a, b). The area of the pseudo-lacunae in the center of the lesion also remains hypofluorescent in both phases (arrow in fig. 4a, b). There is no leakage on the angiogram.

Given the lack of symptoms and the absence of neovascular activity or leakage on the OCT and FA, it was decided to continue to observe the patient on an annual basis. The patient was given an Amsler grid and instructed to call if he experienced any new vision changes.

Discussion

Several of the clinical and OCT findings in this case were consistent with previous cases [4–6, 9, 10]. The clinical findings include having an ovoid shape longer in the horizontal axis, a location temporal to the fovea, absence of foveal involvement, unilaterality, and a lack of visual symptoms. Additionally, on OCT, this lesion displays thinning of the outer retinal layer, a normal inner retinal structure, and a subretinal cleft. Given this, we believe we have identified a true torpedo maculopathy lesion. Differential diagnoses include congenital nevus, choroidal melanoma, hamartoma of the RPE, congenital retinal pigment epithelial hypertrophy (CHRPE), inflammatory causes (toxoplasmosis, etc.), and trauma.

Traditionally, torpedo maculopathy has been described as a mostly hypopigmented or nonpigmented lesion, with some containing a variably hyperpigmented tail [5, 8–10]. Golchet et al. [5] indicated that pigmentation may be variable, with some lesions showing significant hyperpigmentation within the hypopigmented lesion. Villegas et al. [11] used hypopigmentation as a characteristic to distinguish it from similar lesions of the retina such as CHRPE. However, in contrast to the previous classical descriptions, the torpedo lesion in this case has a unique, globally hyperpigmented appearance.

Although most cases of torpedo maculopathy in the literature have referred to it as non-progressive lesion, the lesion in this particular case noticeably changes in size and shape over a 5-year follow-up period. The only other study with a 5-year follow-up period also reported a size increase over 5 years [4]. Wong et al. [6] further categorized torpedo lesions into two different categories and proposed the possibility of the lesions undergoing structural and functional changes over time.

Perhaps the most striking difference over the 5-year follow-up period is the progression of a pseudo-lacuna within the torpedo lesion. The lacuna in this case is unlike the characteristic lacuna belonging to CHRPE. In CHRPE, the lacunae are associated with RPE atrophy and loss with a resultant increase in optical transmission on OCT [12]. In figure 2a, we see RPE thickening, as opposed to atrophy, and decreased optical transmission through the pseudo-lacuna lesion. Additionally, the pseudo-lacuna lesion exhibits hyperautofluorescence on FAF

(fig. 3) and blockage hypofluorescence on FA (fig. 4). The absence of leakage on FA confirms that there is no underlying exudative or neovascular process involved. Interestingly, these findings are in contrast to those found by Golchet et al. [5] in their case series of torpedo maculopathy. In that series, the FA in all cases revealed generalized transmission hyperfluorescence, and the only FAF done exhibited global hypoautofluorescence. These findings led the authors to conclude that there is thinned and nonfunctional RPE in torpedo lesions. The pseudo-lacuna within the current torpedo lesion may simply represent accumulated debris due to dysfunctional (but not absent) RPE – somewhat similar to a vitelliform-like lesion. However, its characteristics actually appear to be more closely related to a variant type of subretinal drusenoid deposits (VTD) as described by Lee and Ham [13]. This is especially interesting given that VTD are also found in the perifoveal region, are discrete lesions, exhibit hyperautofluorescence, and do not appear related to macular degeneration [13]. Although it is currently unknown if there is any progression of VTD, other related types of deposits are well-known to undergo remarkable dynamism over time [14].

EDI-OCT enables superior visualization and measurement of the choroid compared to standard spectral domain OCT [15]. Teitelbaum et al. [8] postulated that abnormal choroidal development in the macula could result in torpedo maculopathy. In this case, the EDI-OCT did not reveal any abnormality in choroidal thickness directly beneath the torpedo lesion. This further supports the theory that torpedo maculopathy may be primarily due to defective RPE, specifically to an RPE developmental defect in the fetal temporal bulge [7]. However, the decreased optical transmission made it difficult to make any qualitative observations of the choroid underlying the lesion. Future studies utilizing en face OCT angiography of the choroid may enhance the understanding of its potential role in this condition.

In this unique case, the presence of global hyperpigmentation, pseudo-lacuna formation, and morphologic changes over time challenge some of the classically held descriptions about torpedo maculopathy. These findings suggest that a torpedo lesion may be more dynamic than previously believed, and necessitate long-term follow-up with multimodal imaging.

Statement of Ethics

Informed consent was obtained from the patient prior to the study.

Disclosure Statement

The authors have no conflicts of interest to disclose.

References

- 1 Roseman RL, Gass JD: Solitary hypopigmented nevus of the retinal pigment epithelium in the macula. *Arch Ophthalmol* 1992;110:1358–1359.
- 2 Daily MJ: Torpedo maculopathy or paramacular spot syndrome. *New Dimens Retin Symp* 1993;11.
- 3 Pian D, Ferrucci S, Anderson SF, Wu C: Paramacular coloboma. *Optom Vis Sci* 2003;80:556–563.
- 4 Sanabria MR, Coco RM, Sanchidrian M: OCT findings in torpedo maculopathy. *Retin Cases Br Rep* 2008;2:109–111.
- 5 Golchet PR, Jampol LM, Mathura JR, Daily MJ: Torpedo maculopathy. *Br J Ophthalmol* 2010;94:302–306.
- 6 Wong EN, Franzco SF, Franzco APH, Franzco FKC: Novel optical coherence tomography classification of torpedo maculopathy. *Clin Experiment Ophthalmol* 2014;342–348.

- 7 Shields CL, Guzman JM, Shapiro, MJ, Fogel LE, Shields JA: Torpedo maculopathy at the site of the 'fetal buldge'. Arch Ophthalmol 2010;128:499–501.
- 8 Teitelbaum BA, Hachey DL, Messner LV: Torpedo maculopathy. J Am Optom Assoc 1997;68:373–376.
- 9 Trevino R, Kiani S, Raveendranathan P: The expanding clinical spectrum of torpedo maculopathy. Optom Vis Sci 2014;91:S71–S78.
- 10 Thomas AS, Flaxel CJ, Pennesi ME: Spectral-domain optical coherence tomography and fundus autofluorescence evaluation of torpedo maculopathy. J Pediatr Ophthalmol Strabismus 2015;52:e8–e10.
- 11 Villegas VM, Schwartz SG, Flynn HW, Capo H, Berrocal AM, Murray TG, Harbour JW: Distinguishing torpedo maculopathy from similar lesions of the posterior segment. Ophthalmic Surg Lasers Imaging Retina 2014;45:222–226.
- 12 Fung AT, Pellegrini M, Shields CL: Congenital hypertrophy of the retinal pigment epithelium. Retina 2013;2:2209–2213.
- 13 Lee MY, Ham D: Subretinal drusenoid deposits with increased autofluorescence in eyes with reticular pseudodrusen. Retina 2014;34:69–76.
- 14 Querques G, Canoui-Poitrine F, Coscas F, Massamba N, et al: Analysis of progression of reticular pseudodrusen by spectral domain – Optical coherence tomography. Invest Ophthalmol Vis Sci 2012;53:1264–1270.
- 15 Margolis R, Spaide RF: A pilot study of enhanced depth imaging optical coherence tomography of the choroid in normal eyes. Am J Ophthalmol 2009;147:811–815.

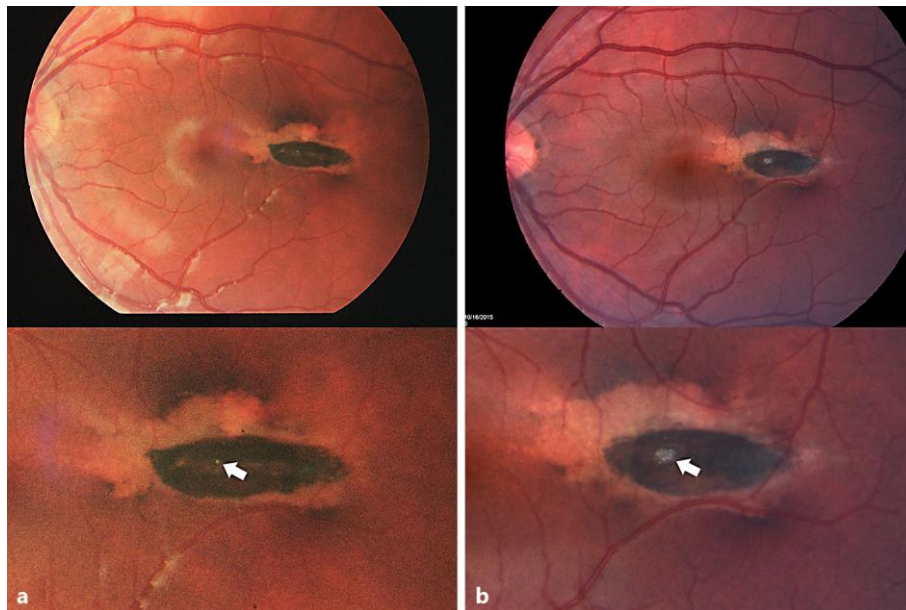


Fig. 1. Torpedo maculopathy. **a** June 2010, fundus photography OS in a 15-year-old male. The magnified view shows the torpedo lesion, with the proposed origin of the pseudo-lacuna demonstrated by the arrow. **b** October 2015, fundus photography OS in a 15-year-old male. The magnified view shows the torpedo lesion with a markedly larger pseudo-lacuna demonstrated by the arrow.

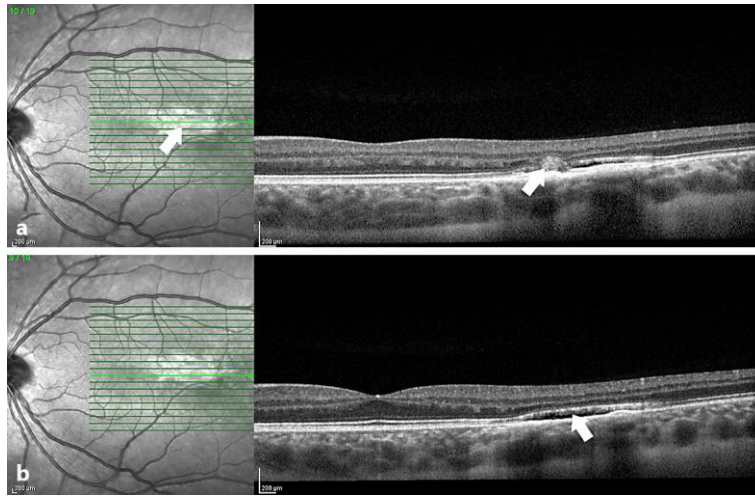


Fig. 2. EDI-OCT of torpedo maculopathy taken in October 2015. **a** Scan at the level of the ‘pseudo-lacuna’ within the torpedo lesion. The white arrow corresponds to the location of pseudo-lacuna in both the infrared image on the left and the OCT image on the right. **b** The white arrow demonstrates a subretinal cleft through the torpedo lesion.

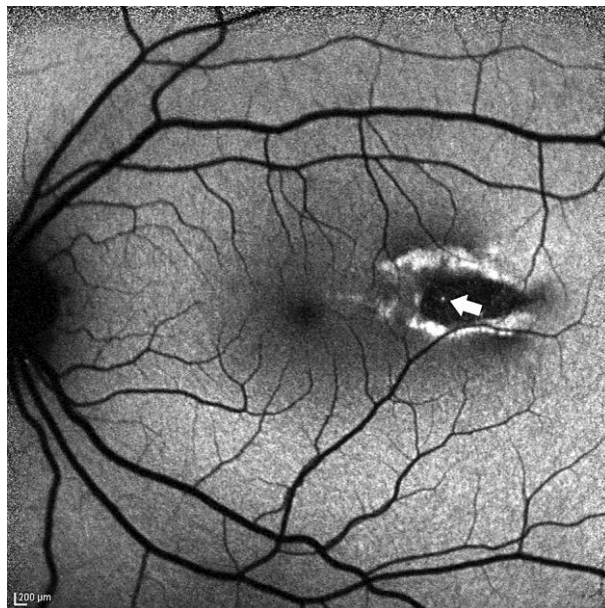


Fig. 3. Fundus autofluorescence of OS in October 2015. The pigmented torpedo lesion is hypoautofluorescent with a rim of hyperautofluorescence. There is a small dot of hyperautofluorescence that corresponds to the pseudo-lacuna found on the color photo (white arrow).

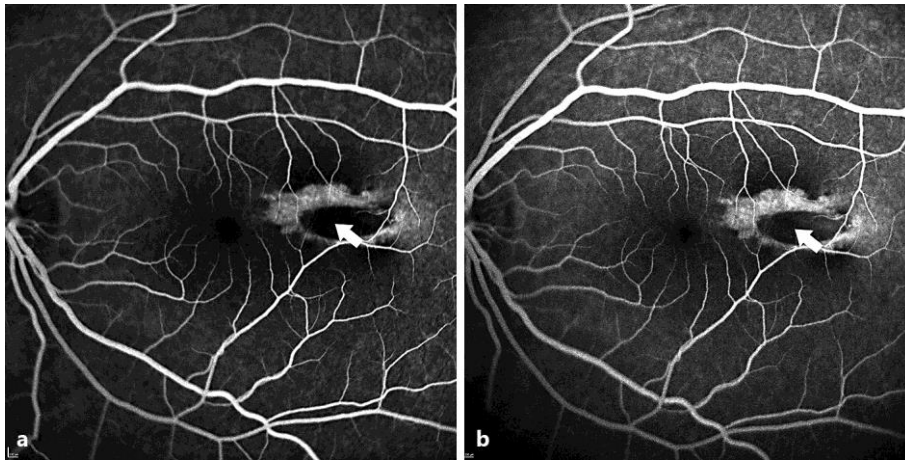


Fig. 4. FA of OS in October 2015. **a** The early-phase angiogram demonstrates a globally hypofluorescent lesion with a rim of hyperfluorescence and no neovascular activity. **b** The late-phase angiogram confirms no neovascular disease or leakage. The area signified by the pseudo-lacuna lesion (arrows) remains hypofluorescent.