

Received: 2011.02.15
Accepted: 2012.03.08
Published: 2012.03.20

Multiple sialolithiasis in sublingual gland causing dysphagia

Hulya Eyigor, Ustun Osma, Mustafa Deniz Yılmaz, Omer Tarik Selcuk

Department of ENT Head and Neck Surgery, Antalya Education and Research Hospital, Antalya, Turkey

Summary

Background:

Sialolithiasis is a common disease of the major salivary glands, but it is rarely seen in the sublingual gland. Patients commonly experience pain and/or swelling, but dysphagia is presented in extended lesions.

Case Report:

In this report we present a 67-year-old woman who had 268 sialoliths in the sublingual gland, forming a huge mass and causing dysphagia. The diameter of the largest sialolith was approximately 4 mm. The diagnosis of sialolithiasis was confirmed pathologically.

Conclusions:

Multiple sublingual gland sialoliths are considered rare; they may cause symptoms like dysphagia and speech difficulty. To our knowledge our patient had more sialoliths in a sublingual gland than any previous reports in the literature.

key words:

sialolithiasis • sublingual gland • multiple sialoliths • dysphagia

Full-text PDF:

<http://www.amjcaserep.com/fulltxt.php?ICID=882599>

Word count:

809

Tables:

–

Figures:

5

References:

10

Author's address:

Hulya Eyigor, Antalya Eğitim ve Arastırma Hastanesi, KBB Kliniği, Antalya, Turkey, e-mail: hulinar@yahoo.com

BACKGROUND

Sialolithiasis is a common disease of the salivary glands. Sialolithiasis occurs mainly in the submandibular gland (80–90%) and to a lesser extent in the parotid gland (5–20%). The sublingual gland and the minor salivary glands are rarely affected (1–2%) [1]. Sialoliths may be single or multiple. Demographically, sialolithiasis shows a male preponderance. All ages may be affected, although patients in their third to sixth decade represent the majority of cases. The symptoms of sialolithiasis vary – patients commonly experience pain and/or swelling when the ducts are obstructed [2]. Dysphagia may be present in extended lesions [3].

In this report we present a 67-year-old woman who had 268 sialoliths in the sublingual gland, forming a huge mass and causing dysphagia.

CASE REPORT

A 67-year-old female patient who had a sublingual swelling for 40 years was admitted to our clinic. She had dysphagia and difficulty in speech for the last 6 months (Figure 1). A month before she went to a primary care clinic with the same complaints and the mass was thought to be an abscess; needle aspiration was attempted but revealed no material. On physical examination a hard localized mass was palpated sublingually. Her oral and dental hygiene was poor. She had absent and decayed teeth. Palpation of the neck revealed no lymphadenopathy. Radiologically there were numerous pearl-like structures on the floor of the mouth on computerized tomography (CT) scan (Figure 2). A transoral approach was performed and a total number of 268 sialoliths were removed from a cystic mass located anterior to the sublingual gland. The diameter of the largest sialolith was approximately 4 mm (Figure 3). Postoperative lavage of the remaining cavity was done for 5 days and antibiotic therapy was given. The diagnosis of sialolithiasis was confirmed pathologically. Control CT scan and intra-oral examination were normal on the 3rd postoperative month (Figures 4, 5).

DISCUSSION

The submandibular gland is the most common site for sialolithiasis, followed by the parotid gland. The sublingual gland and minor glands are very rare sites for sialolithiasis [4].

The major complaints are pain and swelling. Sialolithiasis presents with painful swelling (59%), painless swelling (29%), and pain only (12%), and patients are afflicted with a recurrent salivary colic and spasmodic pain upon eating [4]. The most prominent complaints of our patient were dysphagia and difficulty in speech, which prompted her to seek medical help.

Different etiological hypotheses have been proposed about salivary gland calculi: mechanical, inflammatory, chemical, neurogenic, infectious, foreign bodies, etc. However, it seems that the combination of a variety of these factors usually determines the precipitation of the amorphous tricalcium phosphate, which, once crystallized and transformed into hydroxyapatite, becomes the initial focus [5]. Bacterial infections are important factors involved into calculi formation.

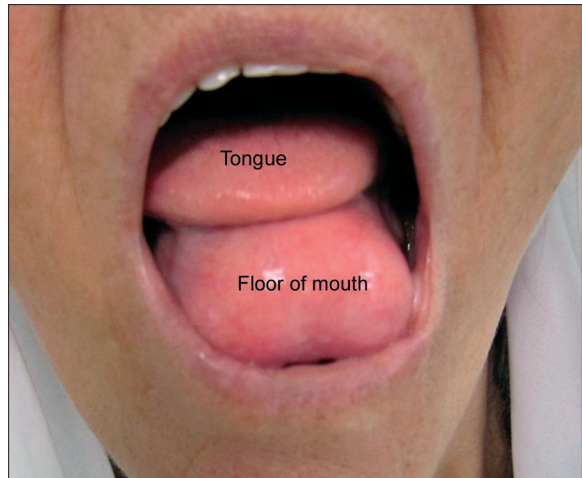


Figure 1. Floor of mouth showing the mass.

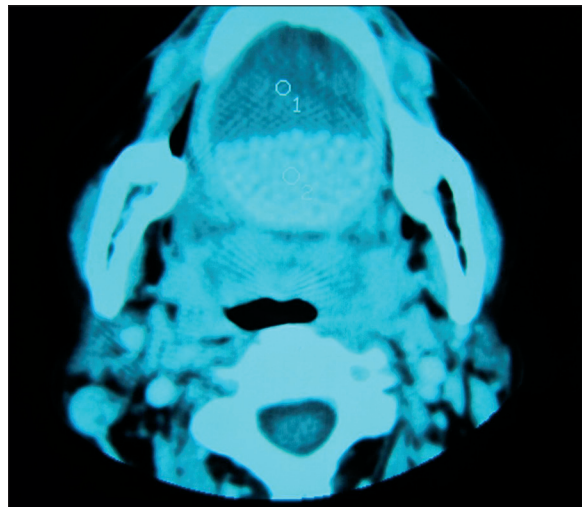


Figure 2. Computed tomography scan showing sialoliths on floor of the mouth.

Toxins produced by bacteria can produce a local environment with pH less than 5.5, which causes tissue damage. When tissue healing processes reestablish the 7.2 pH, crystallization of salivary ions, especially calcium phosphates, occurs [6]. Poor oral hygiene and decayed teeth may have been the etiologic risk factors in our patient.

Sialoliths may be single or multiple. Lustmann et al. [5] reported that 1 sialolith was present in 75.3% of cases, 2 in 15.6%, 3 in 2.9%, and 4 to 8 in 6.2% [1]. In 1972, Hurlen et al. reported a case of multiple sialolithiasis of the minor salivary gland in which 3 sialoliths were removed [7]. Choi et al. reported a patient with 22 sialoliths in a minor salivary gland, who had the largest number of sialoliths up until now [8]. Our case establishes a new record with 268. The size of the salivary calculi may vary from less than 1mm to a few cm in largest diameter. Choi et al. presented sialoliths as large as 5 mm in diameter, like our case.

Sialolithiasis treatment depends on the localization of the salivary calculus; for those closer to the ostium, duct catheterization and dilatation facilitate and allow retrieval of

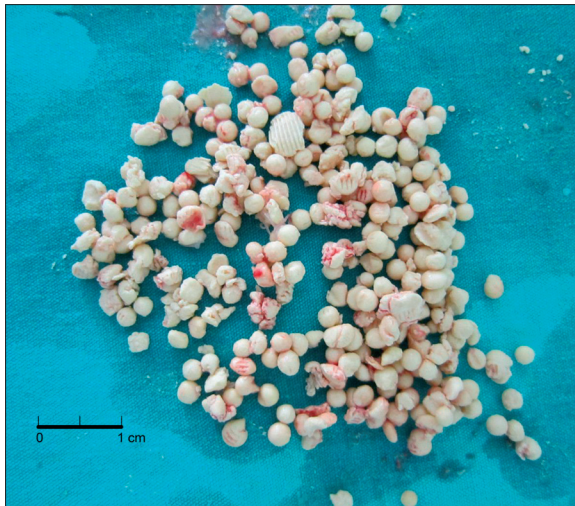


Figure 3. Photograph of 268 sialoliths with diameters measured between 1–4 mm.

the sialolith. For those located in the anterior half of the duct, surgical intervention is the best choice. Finally, the ones located in the posterior region of the duct or within the gland may require total gland removal [9,10]. Jardim et al. indicates that there was no need to remove the gland because there was no inflammation inside [10]. Solitary sialoliths usually do not recur, although chronic multiple recurrence has been reported [8]. Lustmann et al. estimated that the recurrence rate of sialolithiasis is 8.9% [1]. We offered to remove the sublingual gland to prevent recurrence but the patient rejected surgery. There was a regression of inflammation and no sialoliths were present in postoperative CT scan on the 3rd month.

CONCLUSIONS

Multiple sublingual gland sialoliths are considered rare; they may cause different symptoms like dysphagia and speech difficulty. To our knowledge our patient had the most sublingual gland sialoliths ever to be reported in the literature.

REFERENCES:

1. Lustmann J, Regev E, Melamed Y: Sialolithiasis. A survey on 245 patients and a review of the literature. *Int J Oral Maxillofac Surg*, 1990; 19(3): 135–38
2. Williams MF: Sialolithiasis. *Otolaryngol Clin North Am*, 1999; 32(5): 819–34
3. Gungormus M, Yavuz MS, Yolcu U: Giant sublingual sialolith leading to dysphagia. *J Emerg Med*, 2010; 39(3): 129–30
4. Hong KH, Yang YS: Sialolithiasis in the sublingual gland. *J Laryngol Otol*, 2003; 117(11): 905–7

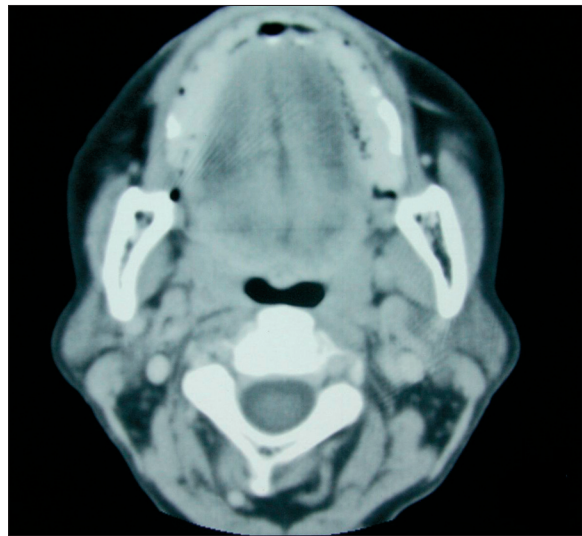


Figure 4. Postoperative CT scan.

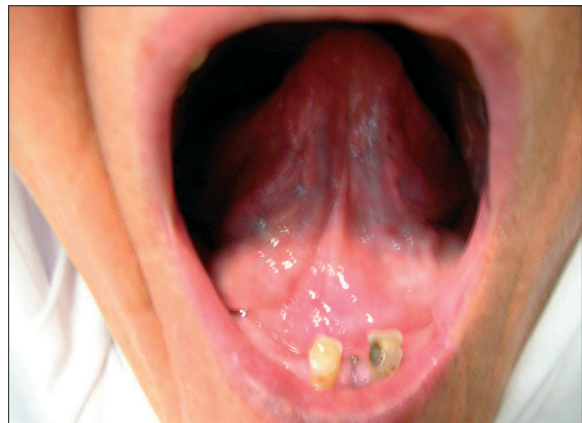

Figure 5. Postoperative intra-oral examination.

5. Bodner L: Parotid sialolithiasis. *J Laryngol Otol*, 1999; 113(3): 266–67
6. Escudier MP: The current status and possible future of salivary calculi. In: Pregrel M, (ed.), *Atlas of oral and maxillofacial surgery clinics of North America*. Philadelphia, PA: Saunders 1998: 117–32
7. Hurlen B, Koppang HS: Multiple sialolithiasis of minor salivary glands: report of a case. *Br J Oral Surg*, 1972; 10(2): 193–98
8. Choi J, Kim K, Oh NS: Multiple sialoliths in sublingual gland: report of a case. *Int J. Oral Maxillofac Surg*, 2002; 31(5): 562–63
9. Ziegler CM, Steveling H, Seubert M et al: Endoscopy: a minimally invasive procedure for diagnosis and treatment of diseases of the salivary glands. Six years of practical experience. *Br J Oral Maxillofac Surg*, 2004; 42(1): 1–7
10. Jardim EC, Ponzoni D, de Carvalho PS et al: Sialolithiasis of the submandibular gland. *J Craniofac Surg*, 2011; 22(3): 1128–31