

## Prostate adenocarcinoma revealed by gingival metastasis: An uncommon presentation

Yosra Yahyaoui<sup>a</sup>, Yosr Zenzri<sup>a,\*\*</sup>, Olfa Adouni<sup>b</sup>, Feriel Letaief<sup>a</sup>, Maha Driss<sup>b</sup>, Amel Mezlini<sup>a</sup>

<sup>a</sup> Medical Oncology Department, Salah Azaiez Institute, Tunis, Tunisia

<sup>b</sup> Pathology Department, Salah Azaiez Institute, Tunis, Tunisia

### ARTICLE INFO

#### Keywords:

Prostate adenocarcinoma  
Metastases  
Gingival

### ABSTRACT

Prostate cancer is the second most frequent among men. Bones and lymph nodes are the most common sites of metastases in advanced prostate cancer. Oral cavity metastases are rare. We report a case of 65-year-old man with a prostate adenocarcinoma revealed by gingival metastasis. We analyze through this observation the clinical, morphological and therapeutic characteristics of this neoplasia.

### Introduction

Prostate cancer tends to occur most commonly in men over the age of 50. It may be revealed by an abnormal digital rectal exam or urinary symptoms, such as hematuria or dysuria. The oral cavity metastases of prostate adenocarcinoma are uncommon and account for 1% of all the oral malignancies. The bony structure is usually invaded. Primary metastases to soft tissues are extremely rare.<sup>1</sup> We report here an unusual case of prostate adenocarcinoma revealed by gingival metastasis.

### Case report

A 65-year-old male with a medical history of heavy smoking (75 pack-year smoking history) was complaining of dysphagia to solids, dysphonia, weight loss and deterioration of the general status since six months. He had a poor performance status (PS = 2). The physical examination revealed a lower gingival lesion (Fig. 1). No cervical lymph nodes were noted. Our patient had weakness and paralysis of the lower limbs. A nasopharyngoscopy was performed. There were no abnormalities during endoscopic examination. A nasopharyngeal biopsy was performed. The histological examination showed a chronic nasopharyngitis. The patient had a gingival biopsy. The anatomopathological examination showed tumor cells proliferation in the lamina propria arranged in small clusters and nests. A cribriform architecture with a stromal fibro-inflammatory reaction were noted. Large cells with atypical nuclei and prominent nucleoli were observed (Fig. 2).

Immunohistochemical staining showed that the tumor cells had a diffuse positivity for the prostate specific antigen (PSA) (Fig. 3). The diagnosis of moderately differentiated adenocarcinoma of the prostate was confirmed.

The PSA blood test was performed. Our patient had a high PSA level (PSA = 721, 3 ng/ml). The prostate ultrasonography showed an enlarged prostate with heterogeneous enhancement and left ureteropyelo-calyceal dilatation. Thoraco-abdomino-pelvic CT scan showed lung metastases with mediastinal lymph nodes. Multiple osteolytic and osteosclerotic bone metastases were observed. Our patient had radiotherapy for the palliation of painful bone metastases. The regimen was 16 Gy given in two 8-Gy fractions, one week apart.

At the time of this writing, our patient is alive. He started luteinizing hormone-releasing hormone (LHRH) agonist (goserelin) associated with Bicalutamide.

### Discussion

Most prostate neoplasms are first found as a result of screening with a prostate-specific antigen (PSA) blood test or digital rectal exam. The diagnosis of prostate cancer can be revealed by metastases. Pelvic lymph nodes and axial skeleton are the most common site of prostate metastases. Less frequently, it spreads lung, to the liver, bladder, or brain. Bone metastases in the mouth are extremely rare, and represent 1% of all malignant oral cavity neoplasms.<sup>2</sup> Few cases of patients with prostate cancer have been reported to have oral cavity metastases. One case of

*Abbreviations:* PSA, the prostate specific antigen; PS, performance status; LHRH, luteinizing hormone-releasing hormone.

\* Corresponding author. Bab Saadoun, 1006, Tunis, Tunisia.

*E-mail addresses:* [yosyahyaoui@gmail.com](mailto:yosyahyaoui@gmail.com) (Y. Yahyaoui), [yosr-zenzri@live.fr](mailto:yosr-zenzri@live.fr) (Y. Zenzri), [Feryel.kstontini@gmail.com](mailto:Feryel.kstontini@gmail.com) (F. Letaief), [maha.driss@rns.tn](mailto:maha.driss@rns.tn) (M. Driss), [amel.mezline@rns.tn](mailto:amel.mezline@rns.tn) (A. Mezlini).

<https://doi.org/10.1016/j.eucr.2020.101156>

Received 22 February 2020; Accepted 16 March 2020

Available online 2 April 2020

2214-4420/© 2020 Published by Elsevier Inc. This is an open access article under the CC BY-NC-ND license (<http://creativecommons.org/licenses/by-nc-nd/4.0/>).

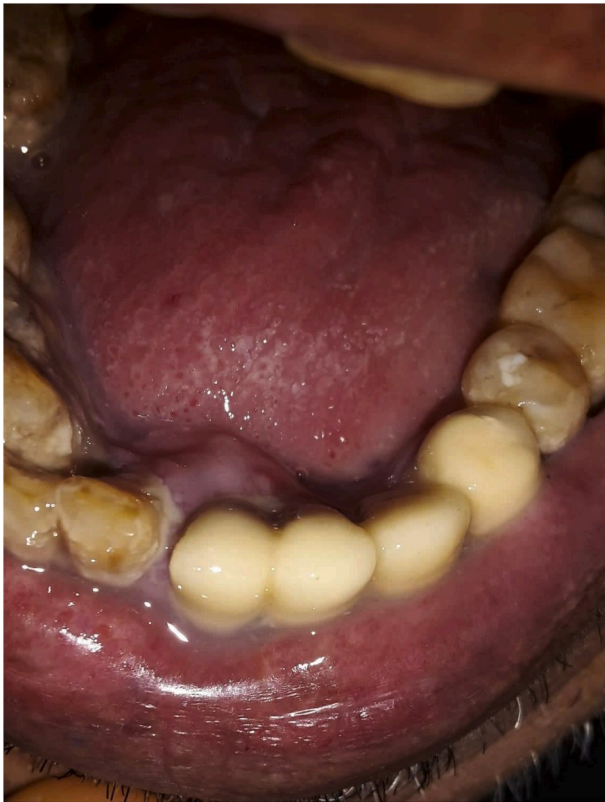

Fig. 1. The gingival lesion.

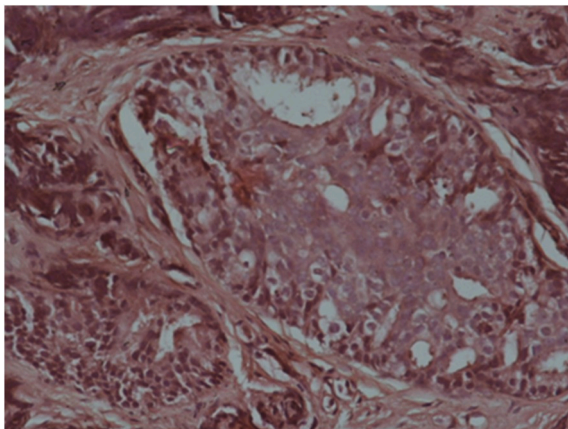


Fig. 2. Prostatic adenocarcinoma infiltrating gingival mucosa HEX40.

gingival metastasis from prostatic adenocarcinoma had been reported in the literature.<sup>3</sup> However, the most common site of oral soft tissues metastases is gingivae (54, 8%).<sup>3</sup> The others sites are: tongue, lips, the buccal and palatal mucosa.

The diagnosis of an oral cavity metastasis is challenging, both to the clinician and to the pathologist because of its rarity.

Piatelli reported 390 cases of oral neoplasms. Twenty-two cases of oral metastases from prostate cancer were described.<sup>3</sup>

The diagnosis requires a combination of morphological and immunohistochemical studies.

Immunohistochemistry is used to facilitate the diagnosis of prostate carcinoma. A positive PSA immunostaining is not completely prostate-specific, but it is helpful in making the diagnosis.<sup>4</sup>

Oral metastases should not be confused with benign lesions such as periodontal abscess, peripheral fibroma or pyogenic granuloma.<sup>5</sup>

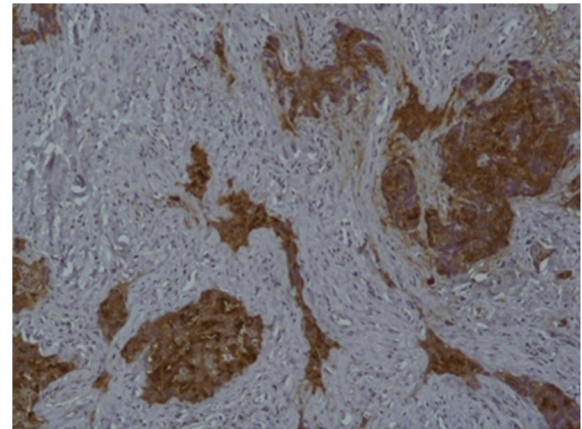


Fig. 3. Diffuse positivity for the prostate specific antigen.

The prognosis of these patients is poor. Surgery is not recommended in most cases.<sup>2</sup>

Patients with localized metastases and controlled primary cancer may have surgery treatment. The gingival metastases must be removed in case of bleeding or pain.

In our case, lung metastases with mediastinal lymph nodes and multiple bone metastases were observed. Surgery was not indicated. Our patient had hormonal treatment and radiotherapy for the palliation of painful bone metastases. Hormonal manipulation does not always result in a favorable response.

## Conclusion

Oral soft tissues metastases of prostate adenocarcinoma are extremely rare. We described the second case of prostate adenocarcinoma revealed by gingival metastasis. Pathological examination and immunohistochemistry are necessary to a conclusive diagnosis. Multidisciplinary approach is mandatory. Metastatic lesion in the oral region has a very poor prognosis.

## Funding

This research did not receive any specific grant from funding agencies in the public, commercial, or not-for-profit sectors.

## Declaration of competing interest

None.

## CRediT authorship contribution statement

**Yosra Yahyaoui:** Conceptualization, Methodology, Software, Data curation, Writing - original draft, Supervision, Validation. **Yosr Zenzri:** Conceptualization, Methodology, Software, Data curation, Writing - original draft, Writing - review & editing. **Olfa Adouni:** Visualization, Investigation. **Feriel Letaief:** Visualization, Investigation. **Maha Driss:** Visualization, Investigation. **Amel Mezlini:** Visualization, Investigation.

## Acknowledgements

None.

## References

1. Damodaran D, Kathiresan N, Satheesan B. Oral cavity metastasis: an unusual presentation of carcinoma prostate. *Indian J Urol.* 2008;24:112–113.
2. Menezes JD, Cappellari PF, Capelari MM, et al. Mandibular metastasis of adenocarcinoma from prostate cancer: case report according to epidemiology and

- current therapeutical trends of the advanced prostate cancer. *J Appl Oral Sci.* 2013;21: 490–495.
3. Piatelli A, Fioroni M, Rubini C. Gingival metastasis from a prostate adenocarcinoma: report of a case. *J Periodontol.* 1999;70:441–444.
  4. Bonk S, Kluth M, Hube-Magg C, et al. Rognostic and diagnostic role of PSA immunohistochemistry: a tissue microarray study on 21,000 normal and cancerous tissues. *Oncotarget.* 2019;10:5439–5453.
  5. Langdon JD, Henk JM. *Malignant Tumors of the mouth. Jaws and Salivary Glands.* second ed. London: E.Arnold; 1995:240–245.