



Contents lists available at ScienceDirect

# International Journal for Parasitology: Parasites and Wildlife

journal homepage: [www.elsevier.com/locate/ijppaw](http://www.elsevier.com/locate/ijppaw)

## Caecal worm, *Aulonocephalus pennula*, infection in the northern bobwhite quail, *Colinus virginianus*



Nicholas R. Dunham<sup>a</sup>, Cassandra Henry<sup>a</sup>, Matthew Brym<sup>a</sup>, Dale Rollins<sup>b</sup>,  
R. Gayman Helman<sup>c</sup>, Ronald J. Kendall<sup>a,\*</sup>

<sup>a</sup> The Wildlife Toxicology Laboratory, Texas Tech University, Box 43290, Lubbock, TX, 79409-3290, USA

<sup>b</sup> Rolling Plains Quail Research Ranch, 1262 U.S. Highway 180 W., Rotan, Texas, 79546, USA

<sup>c</sup> Texas A&M Veterinary Medical Diagnostic Laboratory, 6610 Amarillo Blvd. West, Amarillo, TX, 79106, USA

### ARTICLE INFO

#### Article history:

Received 21 December 2016

Received in revised form

16 February 2017

Accepted 22 February 2017

#### Keywords:

*Aulonocephalus pennula*

Caecal worm

*Colinus virginianus*

Northern bobwhite

Parasitism

Pathology

### ABSTRACT

Parasitic nematodes that infect quail have been understudied and long been dismissed as a problem in quail management. Within the Rolling Plains ecoregion of Texas, an area that has experienced quail population “boom and bust” cycles and ultimately a general decline, the need to determine why Northern bobwhite (*Colinus virginianus*) populations are diminishing has increased in priority. Previously, caecal parasites have been documented to cause inactivity, weight loss, reduced growth, inflammation to the caecal mucosa, and even death. The caecal worm *Aulonocephalus pennula* is an intestinal nematode parasite that is commonly found within the caecum of quail, as well as many other avian species. In the Rolling Plains ecoregion, *A. pennula* has been documented to have as high as a 98% prevalence in bobwhite quail samples; however, the effect it has on its host is not well understood. The present study documents *A. pennula* causes no pathological changes within the caeca of the Northern bobwhite. However, there is concern for disruption of digestion and the possible implications of infection for wild bobwhite quail survival are discussed.

© 2017 The Authors. Published by Elsevier Ltd on behalf of Australian Society for Parasitology. This is an open access article under the CC BY-NC-ND license (<http://creativecommons.org/licenses/by-nc-nd/4.0/>).

### 1. Introduction

The gastrointestinal tract is highly susceptible to many species of intestinal parasites (Cynthia, 2011). Infected avian species have been reported to experience inflammation, lesions, hemorrhaging, hyperplasia, necrosis, and even death (Greiner and Ritchie, 1994). Even parasites that were thought to have no effect on the host have been shown to cause weight loss (Booth et al., 1993). When you consider that avian fat stores can affect the survivability through winter, even a slight weight loss can have major implications (Rogers, 1987). Despite a parasites ability to regulate a host population, there have only been intermittent efforts to address these concerns (Leopold, 1986; Lehmann, 1984; Peterson, 2007).

Recently, *Aulonocephalus pennula* infection has gained more attention with surveys showing high prevalence and intensity in Northern bobwhite (*Colinus virginianus*; hereafter bobwhite) inhabiting the Rolling Plains ecoregion of Texas (Villarreal et al.,

2012; Bruno, 2014; Dunham et al., 2016a). These findings are rather alarming considering that the Rolling Plains ecoregion, a region once known for its rather abundant quail populations, has often experienced a cyclical boom-and-bust population life cycle that repeats on approximately a 5-year cycle (Hernández and Peterson, 2007; Lusk et al., 2007). Unfortunately, bobwhite populations in the Rolling Plains ecoregion have been declining despite relatively stable habitat conditions (Rollins, 2007).

First described by Chandler (1935), *A. pennula* (synonymously *A. lindquisti*) is a free-floating intestinal caecal worm nematode that is typically found in the caeca and occasionally in the large and small intestine. It is thought that caecal worm infection can disrupt the digestion ability of the host. The avian caeca is important for cellular digestion, absorption of nutrients, regulation and absorption of water and nitrogen, and the production of antibodies to name a few (Clench and Mathias, 1995). Lehmann (1984) suggested that *A. pennula* to be detrimental to bobwhite health because they ingest and/or disrupt the host's digestive material, which possibly impacts reproduction and causes death through malnutrition especially during times of drought. Rollins (1980) speculated that caecal digestion was especially important when the bobwhite's diet

\* Corresponding author.

E-mail address: [ron.kendall@ttu.edu](mailto:ron.kendall@ttu.edu) (R.J. Kendall).

consisted of high-cellulose foods (e.g., during late-winter when seeds of Russian thistle [*Salsola kali*] were most common in a bobwhite's diet in the Rolling Plains). Recent studies by Villarreal et al. (2012), Bruno (2014), Dunham et al. (2016a) found *A. pennula* to be highly prevalent. Observations were not reported on any gross pathology associated with infection. Although the prevalence has been well documented, there is little known about the life cycle or pathogenicity of *A. pennula*; however, Rollins (1980) visually noted gross pathological changes in quail infected with >100 worms. Rollins (1980) also noted that intensities of *A. pennula* increased through the winter months, thus potentially limiting caecal digestion via interference.

The purpose of this study was to (Booth et al., 1993) examine the host response to infection with *A. pennula*, and (Bruno, 2014) discuss the possible contribution that *A. pennula*-associated infection has on the decline of Northern bobwhites in the Rolling Plains ecoregion of Texas and Oklahoma.

## 2. Materials and methods

### 2.1. Ethics statement

This experiment was approved by Texas Tech University Animal Care and Use Committee under protocols 16071-08 and 16049-06. All bobwhite were trapped and handled according to Texas Parks and Wildlife permit SRP-1098-984 and SRP-0715-095.

### 2.2. Study area

The experimental study area of the present manuscript is consistent with the study area described in Dunham et al. (2014). The broader range of application (e.g., Rolling Plains) was described by Rollins (2007).

### 2.3. Quail samples

Wild bobwhites were collected from the same study area, in the same manner, and using the same techniques previously described by Dunham et al. (2014). The quail collection for the present study occurred in October 2016. Pen-raised bobwhites, purchased from the Quail Ranch of Oklahoma, were used as infection free control quail for our study.

### 2.4. Histological techniques

After euthanasia, the feathers and skin were removed from the breast and surrounding area. Both femurs were then disarticulated from the ilium allowing for easier access to the sternum. A shallow incision was made in the connective tissue around the metasternum and continued in the direction of the coracoid and clavicle. The coracoid and clavicle were severed freeing the sternum and exposing the body cavity. Next, the ventriculus and liver were gently removed revealing the intestines and caeca. Both caeca, as well as a portion of the ileum, were excised via a cut at the ileum and large intestine. In order to determine *A. pennula* infection levels, the caeca and associated ileum were checked for parasites as described in Dunham et al. (2016a). To prepare samples for pathology, the caeca and attached ileum were cut into approximately 20–30 mm sections and fixed in 10% neutral buffered formalin. Each sample was fixed for a minimum of 4 days. Fixed sections of caecum were then sectioned in 3 mm intervals prior to processing. All tissues were processed in an automated Shandon Pathcentre® histology processor (Thermo Scientific, Waltham, MA), which dehydrated tissues in progressively increased concentrations of ethanol and cleared in xylene prior to paraffin embedding. The

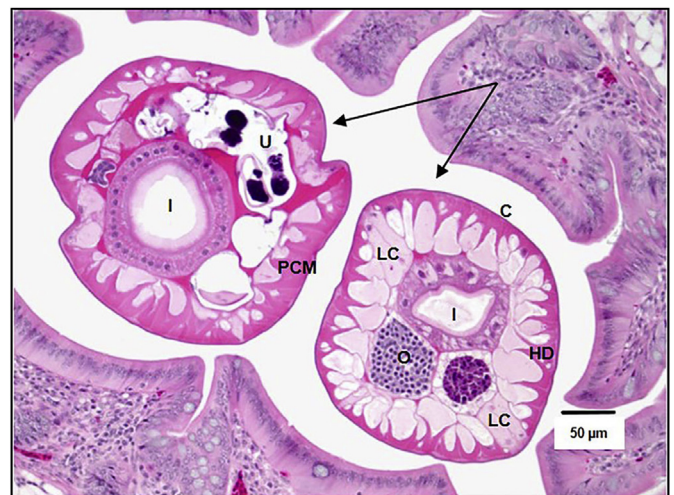
processed tissue was then embedded in Paraplast™ paraffin wax (VWR, Radnor, PA) to create tissue blocks for microtomy. Tissue was sectioned at 4 μ thickness with a microtome and mounted on glass slides for staining. Routine staining with hematoxylin and eosin (VWR Premium Histology Stains) was performed, slides were cover-slipped, and specimens were examined microscopically by a board-certified veterinary pathologist. A SPOT Idea™ digital camera (SPOT Imaging, Diagnostic Instruments, Inc., Sterling Heights, MI) connected to an Olympus BX-51 bright field microscope (Olympus America Inc., Center Valley, PA) was used for imaging. The orad, middle, and aborad portions of the caecum were adequately sampled from each bobwhite sample. Voucher specimens of *A. pennula* (1 424 314) were deposited in the Smithsonian Museum of Natural History (Suitland, Maryland, USA).

### 2.5. Parasite identification

Caecal worms were identified morphologically using the descriptions from Chandler (1935) and Inglis (1958) and the present observations were consistent with these. The head structure was composed of six trough-shaped grooves, a distinguishing characteristic of *A. pennula*. Histologically, intraluminal nematodes were generically circular on transverse section and measured 250–300 μm in diameter. Nematodes were composed of a smooth homogenous eosinophilic cuticle with fine annular striations, a hypodermis, longitudinal polymyarian coelomyarian musculature, a pseudocoelom, prominent lateral cords, and variable tubular organs (Fig. 1). Cuticle thickness was approximately 2–4 μm with the hypodermis approximately 4–8 μm thick. The esophagus was triradiate and intestines were lined by polycytous isocytous epithelium. Both males and females were present within the caecum. Females had variable portions of paired uterus, oviduct, and ovaries occupying the remainder of the section. Uterus contained non-embryonated eggs with indistinct morphology. Males had paired testes.

### 2.6. Statistical analysis

A two sample *t*-test was conducted to determine if there was a significant difference in caecal worm infection between sex and age



**Fig. 1.** Histological section of a Northern bobwhite (*Colinus virginianus*) caecum with intraluminal *Aulonocephalus pennula* parasites in transverse sections (indicated by arrows). Hematoxylin and eosin staining at 200×; C = cuticle; HD = hypodermis; LC = lateral cord; I = intestines; O = oviducts; U = uterus containing eggs; PCM = polymyarian coelomyarian musculature.



(R Development Core Team, 2015). Significance was determined at  $P \leq 0.05$  and means are reported as mean  $\pm$  SE.

### 3. Results

All ten (5 adult, 5 juvenile, 6 male, 4 female) of the wild captured bobwhites in our sample were infected with *A. pennula*. Infection ranged from 97 to 341 with a mean of  $195.7 \pm 24.53$  caecal worms per bird. Adult bobwhites averaged  $223 \pm 42.53$  caecal worms while juveniles averaged  $168.4 \pm 17.5$ ; however, no significant difference was detected ( $t[8] = 1.063, P = 0.32$ ). Females averaged  $218.5 \pm 36.4$  while male bobwhites only averaged  $180.5 \pm 31.4$  caecal worms per bird but no significant difference was documented ( $t[8] = 0.699, P = 0.50$ ). Transverse sections of the oral, middle, and aboral caecum were all similar morphologically. All wild bobwhite samples had no significant changes in the caecal wall despite the variable numbers of *A. pennula* found within the caecal lumen (Fig. 2). Samples taken from infection free pen-raised control bobwhites had a patchy distribution of mild to moderate number of mononuclear leukocytes consisting of lymphocytes, plasma cells, and mononuclear phagocytes within the lamina propria of the caecum (Fig. 3). Additionally there were scattered proprial lymphoid nodules within the control caecum.

### 4. Discussion

Intestinal parasites have long been reported in bobwhites, along with several other galliform species (Hudson, 1986; Robel et al., 2003; Dunham et al., 2016a). However, the Rolling Plains ecoregion appears to harbor the greatest intensities of caecal worms, often 3 times higher than other studies on bobwhites in Texas (Jackson, 1969; Rollins, 1980; Lehmann, 1984; Bruno, 2014; Villarreal et al., 2012). Hudson (1986) was one of the first studies to suggest that a caecal worm, *Trichostrongylus tenuis*, has the ability to regulate populations of red grouse (*Lagopus lagopus scoticus*). Additional research also suggested that there was a negative correlation between the presence of these caecal worms and the breeding success of female red grouse (Potts et al., 1984). Watson et al. (1987) documented that *T. tenuis* of the red grouse uses a grazing-feeding strategy, in which it directly consumes the tissues of the caecum and often penetrates the caecal wall when occurring at high intensities. With evidence of caecal worm infections negatively impacting other galliform species, the need to investigate the potential implications of *A. pennula* in bobwhite became necessary.

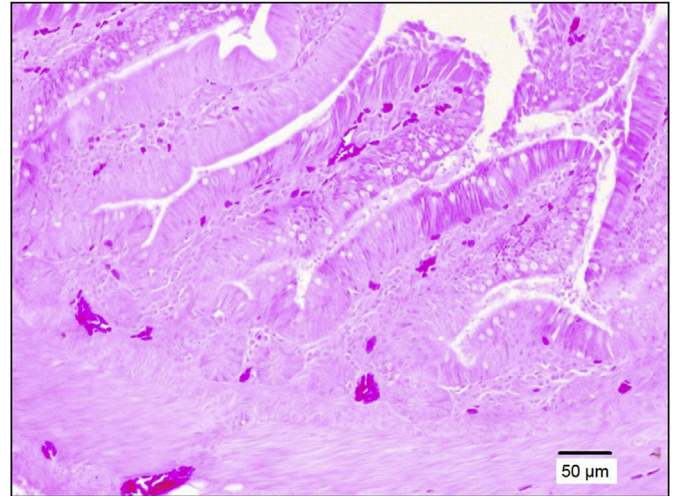


Fig. 3. Transverse histological sections of a pen-raised control Northern bobwhite (*Colinus virginianus*) caecum without an *Aulonocephalus pennula* infection.

Unlike *T. tenuis*, *A. pennula* is thought to be a free-floating nematode and does not penetrate the caecal wall; however, it is possible that, at high intensities, that *A. pennula* may penetrate the host's caecum. The results of the present study indicated that *A. pennula* infection does not cause observed caecal lesions. This was surprising given that, while our sample size was small, it was expected that inflammation and/or pathology would be witnessed, especially considering that the sample size averaged "strong to extreme" caecal worm infections (Dunham et al., 2016a).

A key finding of the present study was that only minimal amounts of digesta was found within the caecum. Petkevičius (2007) noted that common characteristics of intestinal parasites are that they cause a reduction in feed intake, reduction of the digestibility of ingesta, and a decreased efficiency of feed utilization. The mucosa of the intestinal tract especially the ileum, caecum, and large intestine normally contain lymphoid cellular elements. These are components of the normal immune defense mechanisms in the intestinal mucosa, which will fluctuate in intensity in normal animals based on the microenvironment of the lumen due to diet as well as other foreign factors in transit through the digestive tract. If bobwhites are not efficiently digesting foods, especially during the bottleneck of late-winter, this could have direct implications on the survivability of the bobwhite. Rollins (1980) speculated that

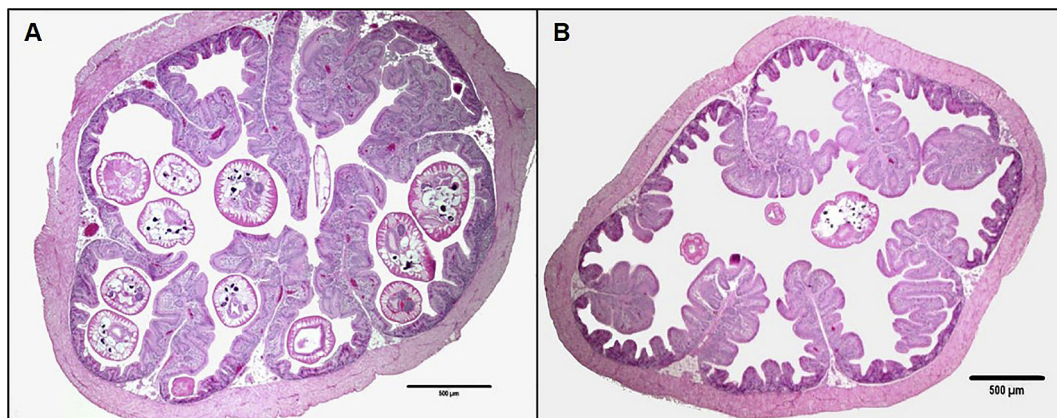


Fig. 2. Transverse histological sections of a Northern bobwhite (*Colinus virginianus*) caecum infected with *Aulonocephalus pennula*. Hematoxylin and eosin staining at 40 $\times$  for both A and B.

excessive caecal worm burdens (>150 worms per bird) could impede caecum function via interference when the caecal lumen was essentially blocked with worms. Rollins also noted that caecal worm burdens more than doubled from October through January.

Intestinal parasites, in both human and animals, have been associated with many nutritional deficiencies, such as iron or vitamin A (Hesham et al., 2004). Lehmann (1953, 1984) found that changes in *A. pennula* intensity in bobwhites reduced vitamin A levels, especially during time of drought. The Rolling Plains ecoregion commonly experiences drought like conditions, which could be increasing the worm burdens within these quail. Drought-like conditions have been suggested to cause quail to experience water stress and consume less nutrients (Hernández and Peterson, 2007). If these quail begin to experience nutritional stress their ability to withstand helminth infections may become compromised (Wobeser, 2006). Parasites have evolved a series of strategies to invade the host and to evade host defense mechanisms (Koski and Scott, 2003). McSorley and Maizels (2012) suggested that infections may be associated with a significant degree of downregulation of the host immune response and decrease the bird's ability to eliminate parasites. Given this, it is likely that these parasites will continue to grow and infection will continue until the host dies. This is supported by the fact that 96% of bobwhites collected in the study in the Rolling Plains of Texas had  $\leq 300$  caecal worms suggesting a quantitative relationship between degree of infection and bobwhite survival (Dunham et al., 2016a).

With high prevalence of *A. pennula* documented in bobwhites in the Rolling Plains ecoregion, along with the documented eyeworm (*Oxyspirura petrowi*) prevalence and associated pathology throughout the region (Bruno et al., 2015; Dunham et al., 2016b), a need to treat/control parasitic infection with an anthelmintic medication could be needed in the near future. Studies have shown that treating avian species with an anthelmintic medication causes a reduction of parasites, heavier bird weights, and population stability (Hudson et al., 1992, 1998; Katoch et al., 2012). While the results of this research cannot determine if *A. pennula* is impairing a bobwhite's digestive efficiency, there is no doubt that this parasite species is highly prevalent and the relationship is likely not symbiotic. Additional research is needed to determine the life history characteristics of *A. pennula* and its probable impact on bobwhites in this region.

## Acknowledgments

We thank Rolling Plains Quail Research Foundation (23A470) and Park Cities Quail (24A125) for their continued financial support of our quail research. We thank the Texas A&M Veterinary Medical Diagnostic Laboratory (Amarillo, TX) for performing the histologic processing of our quail samples. We thank the owners and employees of our study ranch for allowing access and providing lodging. Lastly, we thank all of the reviewers for their time, comments, and consideration of this manuscript.

## References

- Booth, D.T., Clayton, D.H., Block, B.A., 1993. Experimental demonstration of the energetic cost of parasitism in free-ranging hosts. *Proc. R. Soc. Lond. B Biol. Sci.* 253, 125–129.
- Bruno, A., 2014. Survey for *Trichomonas Gallinae* and Assessment of Helminth Parasites in Northern Bobwhites from the Rollin Plains Ecoregion. Thesis. Texas A&M University-Kingsville, USA.
- Bruno, A.B., Fedynich, A.M., Smith-Herron, A., Rollins, D., 2015. Pathological response of northern bobwhites to *Oxyspirura petrowi* infections. *J. Parasitol.* 101, 364–368.
- Chandler, A.C., 1935. A new genus and species of Subuluriae (Nematodes). *Trans. Am. Micro. Soc.* 54, 33–35.
- Clench, M.H., Mathias, J.R., 1995. The avian cecum: a review. *Wilson Bull.* 1, 93–121.
- Cyntia, K., 2011. The Merck Veterinary Manual 10th (Tenth) Edition. Merck Sharp & Dohme Corp.
- Dunham, N.R., Soliz, L.A., Fedynich, A.M., Rollins, D., Kendall, R.J., 2014. Evidence of an *Oxyspirura petrowi* epizootic in northern bobwhites (*Colinus virginianus*), Texas, USA. *J. Parasitol.* 50, 552–558.
- Dunham, N.R., Peper, S.T., Downing, C., Brake, E., Rollins, D., Kendall, R.J., 2016a. Infection levels of eyeworm *Oxyspirura petrowi* and caecal worm *Aulonocephalus pennula* in the northern bobwhite and scaled quail from the Rolling Plains of Texas. *J. Helminthol.* <http://dx.doi.org/10.1017/S0022149X16000663>.
- Dunham, N.R., Reed, S., Rollins, D., Kendall, R.J., 2016b. *Oxyspirura petrowi* infection leads to pathological consequences in Northern bobwhite (*Colinus virginianus*). *Int. J. Parasitol. Parasites Wildl.* 5, 273–276.
- Greiner, E.C., Ritchie, B.W., 1994. In: Ritchie, B.W., Harrison, G.J., Harrison, L.R. (Eds.), *Avian Medicine: Principles and Application in Parasites*. Wingers Publishing Inc, Lake Worth, Florida.
- Hernández, F., Peterson, M.J., 2007. In: Brennan, L. (Ed.), *Northern Bobwhite Ecology and Life History*. Pp 40–64 in *Texas Quails: Ecology and Management*. Texas A&M University Press, College Station, USA.
- Hesham, M.S., Edariah, A.B., Norhayati, M., 2004. Intestinal parasitic infections and micronutrient deficiency: a review. *Med. J. Malays.* 59, 284–293.
- Hudson, P.J., 1986. The effect of a parasitic nematode on the breeding production of red grouse. *J. Anim. Ecol.* 55, 85–92.
- Hudson, P.J., Newborn, D., Dobson, A.P., 1992. Regulation and stability of a free-living host-parasite system: *Trichostrongylus tenuis* in red grouse. I. Monitoring and parasite reduction experiments. *J. Anim. Ecol.* 61, 477–486.
- Hudson, P.J., Newborn, D., Dobson, A.P., 1998. Prevention of population cycles by parasite removal. *Science* 282, 2256–2258.
- Inglis, W.G., 1958. The comparative anatomy of the subulurid head (Nematoda) with a consideration of its systematic importance. *Proc. Zool. Soc. Lond.* 130, 577–604.
- Jackson, A.S., 1969. Quail Management Handbook for West Texas Rolling Plains. Bull. vol. 48. Texas Parks and Wildlife Department, Austin, Texas, pp. 1–75.
- Katoch, R., Yadav, A., Godara, R., Khajuria, J.K., Borkataki, S., Sodhi, S.S., 2012. Prevalence and impact of gastrointestinal helminthes on body weight gain in backyard chickens in subtropical and humid zone of Jammu, India. *J. Parasit. Dis.* 36, 49–52.
- Koski, K.G., Scott, M.E., 2003. Gastrointestinal nematodes, trace elements, and immunity. *J. Trace Elem. Exp. Med.* 16, 237–251.
- Lehmann, V.W., 1953. Bobwhite population fluctuations and vitamin A. *Trans. N. A. Wildl. Game Conf.* 18, 199–246.
- Lehmann, V.W., 1984. The Bobwhite in the Rio Grande Plain of Texas. Texas A&M University Press, College Station, USA.
- Leopold, A., 1986. Game Management. Univ. Wisconsin Press, Madison, p. 481 (first published in 1933 by Charles Scribner's Sons).
- Lusk, J.J., Guthery, F.S., Peterson, M.J., Demaso, S.J., 2007. Evidence of regionally synchronized cycles in Texas quail population dynamics. *J. Wildl. Manage* 71, 837–843.
- McSorley, H.J., Maizels, R.M., 2012. Helminth infections and host immunoregulation. *Clin. Microb. Rev.* 25, 585–608.
- Peterson, M.J., 2007. In: Brennan, L. (Ed.), *Diseases and Parasites of Texas Quails Pp 89–114 in Texas Quails: Ecology and Management*. Texas A&M University Press, College Station, TX, USA.
- Petkevicius, S., 2007. The interaction between intestinal helminth infection and host nutrition. *Review. Veterinararija ir. zootech.* 37, 53–60.
- Potts, G.R., Tapper, S.C., Hudson, P.J., 1984. Population fluctuations in red grouse: analysis of bag records and a simulation model. *J. Anim. Ecol.* 53, 21–36.
- R Core Team, 2015. R: A Language and Environment for Statistical Computing. R Foundation for Statistical Computing, Vienna, Austria. <https://www.R-project.org>.
- Robel, R.J., Walker, T.L., Hagen, C.A., Ridley, R.K., Kemp, K.E., Applegate, R.D., 2003. Helminth parasites of lesser prairie-chicken *Tympanuchus pallidinctus* in southwestern Kansas: incidence, burdens and effects. *Wildl. Biol.* 9, 341–349.
- Rogers, C.M., 1987. Predation risk and fasting capacity: do wintering birds maintain optimal body mass? *Ecol* 68, 1051–1061.
- Rollins, D., 1980. Comparative Ecology of Bobwhite and Scaled Quail in Mesquite Grassland Habitats. M.S. Thesis. Oklahoma State University.
- Rollins, D., 2007. In: Brennan, L. (Ed.), *Quails on the Rolling Plains Pp 117–141 in Texas Quails: Ecology and Management*. Texas A&M University Press, College Station, USA.
- Villarreal, S.M., Bruno, A., Fedynich, A.M., Brennan, L.A., Rollins, D., 2012. Helminth infections across a northern bobwhite (*Colinus virginianus*) annual cycle in Fisher County, Texas. *West. N. Am. Naturalist* 76, 275–280.
- Watson, H., Lee, D.L., Hudson, P.J., 1987. The effect of *Trichostrongylus tenuis* on the caecal mucosa of young, old and anthelmintic-treated wild red grouse, *Lagopus lagopus scoticus*. *Parasitol* 94, 405–411.
- Wobeser, G.A., 2006. Defense, resistance, and repair pp 75–90. In: *Essentials of Disease in Wild Animals*. Blackwell Publishing, Ames, Iowa.