

HOSTED BY



ELSEVIER

Contents lists available at ScienceDirect

Chinese Journal of Traumatology

journal homepage: <http://www.elsevier.com/locate/CJTEE>

Case report

Bilateral segmental pelvic and femoral fractures in a young female: A rare case report

Raju Vaishya, Amit Kumar Agarwal*, Nishint Gupta, Vipul Vijay

Department of Orthopaedics and Joint Replacement Surgery, Indraprastha Apollo Hospitals, New Delhi 110076, India

ARTICLE INFO

Article history:

Received 8 August 2015

Received in revised form

23 December 2015

Accepted 2 January 2016

Available online 13 May 2016

Keywords:

Pelvis

Femoral fractures

Rib fractures

ABSTRACT

The management of multiple complicated injured patients remains a great challenge despite advancements in modern medical care. We present a rare case of bilateral unstable pelvic fractures associated with bilateral segmental femoral shaft fractures. We have proposed a mechanism of such complex injury pattern and discussed the plan of management. We believe that a timely and aggressive surgical intervention to fix all the major fractures soon after medically stabilizing the patient helped our patient to overcome these serious and lethal injuries. It is necessary to establish an optimal protocol for management of such complex fractures by conducting prospective and multicentric studies in the future.

© 2016 Daping Hospital and the Research Institute of Surgery of the Third Military Medical University. Production and hosting by Elsevier B.V. This is an open access article under the CC BY-NC-ND license (<http://creativecommons.org/licenses/by-nc-nd/4.0/>).

Introduction

Pelvic fractures occurring simultaneously with femoral shaft fractures are extremely rare and serious injuries. They are often caused by high-energy trauma and are associated with a high mortality rate.¹ However, such severe injuries with complex patterns are seen more commonly nowadays due to high-speed trauma caused in road traffic accidents (RTA) on motorways. High mortality rates (50%–77%) have been reported for femoral shaft fractures associated with pelvic fractures and injuries to other systems.² These injuries have a great impact not only on the social and economic life of individual, but also on the society.³ We present a rare case of bilateral unstable pelvic fractures (acetabular and sacral fractures), bilateral segmental femoral shaft fracture with multiple right rib fractures and associated haemothorax. To the best of our knowledge, no such combination of injury has been reported so far. We have proposed a mechanism of such injury and discussed the plan of management.

Case report

A 21-year-old female sustained multiple injuries in a major RTA 6 months ago. She was travelling with family and friends in a four

wheeler jeep when the driver of her vehicle tried to overtake a truck in high speed and had a head-on collision with the truck coming from opposite side. Five out of seven co-passengers died in this accident on the spot. Only 2 young ladies, sitting in the rear seat of the jeep, survived this fatal accident (Fig. 1). They were admitted in a nearby hospital where they had primary resuscitative treatment and were then referred to our tertiary care center 5 days after the accident.

On admission, this patient was in a state of hemorrhagic shock and was found to have multiple injuries, including multiple right rib fractures with haemothorax, bilateral segmental femur fractures (Fig. 2), bilateral acetabular and sacral fractures (Fig. 3), with involvement of lumbosacral plexus causing foot drop on both sides.

Her medical condition was stabilized by multiple blood transfusions, intravenous broad-spectrum antibiotics, splinting of fractures by skeletal traction, right chest tube drainage and other supportive measures. She was then operated on in 2 sittings at the gap of 2 days to fix all the major fractures. Firstly, the segmental fractures of both femora were fixed under general anaesthesia using intramedullary interlocking nails, taking the adequate precaution of padding the perineal and sacral areas. Right side segmental femur fracture was fixed with an antegrade femoral nail; whereas left comminuted segmental fracture was more proximal (subtrochanteric) therefore was fixed with Synthes' shaft fracture nailing system. Postoperatively, she was kept in intensive care for close monitoring. She responded very well to the first surgery and hence after two days the sacral fractures were fixed using a sacral bar in a prone position. And then the patient was turned supine and

* Corresponding author. Tel.: +91 9968578514.

E-mail address: amitorthopgi@yahoo.co.in (A.K. Agarwal).

Peer review under responsibility of Daping Hospital and the Research Institute of Surgery of the Third Military Medical University.



Fig. 1. Four wheeler at the site of accident, victims being extricated from the vehicle.

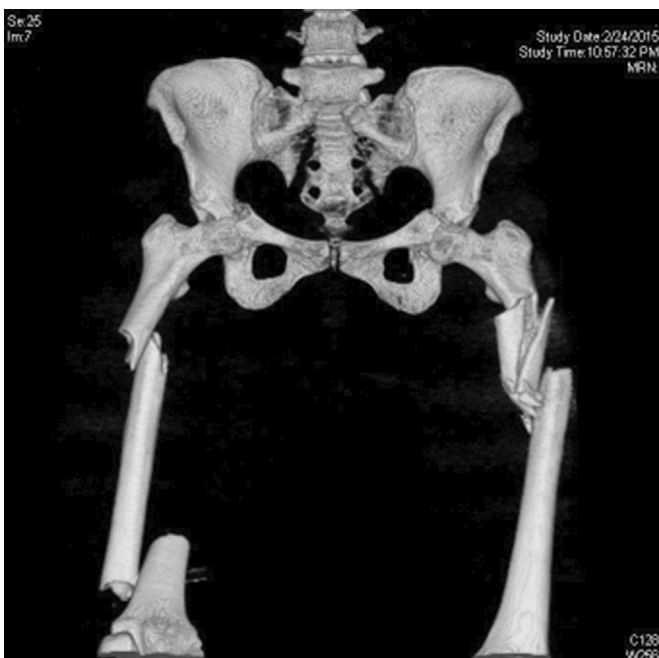

Fig. 2. 3-dimensional CT-scan showing bilateral segmental femur fractures, bilateral anterior column acetabulum fractures, and bilateral sacral fractures.

anterior column fractures of both the acetabulum were fixed with pre-contoured reconstruction plates through the bilateral ilioinguinal approach.

The postoperative courses after both surgeries were uneventful. She was allowed sitting in bed from the 2nd postoperative day and active and passive exercises were started. After 10 days, she was discharged after stitches removal. Physiotherapy and wheelchair mobilization were advised for 6 weeks. At a follow-up of 3 months, she had shown neurological recovery and the ankle dorsiflexors were improved from the Medical Research Council (MRC) grade 0 to grade 3 and at 6 months to grade 4+. Follow-up radiographs showed satisfactory healing of all the fractures in good alignment at 12 months (Figs. 4–6). She was allowed partial weight bearing

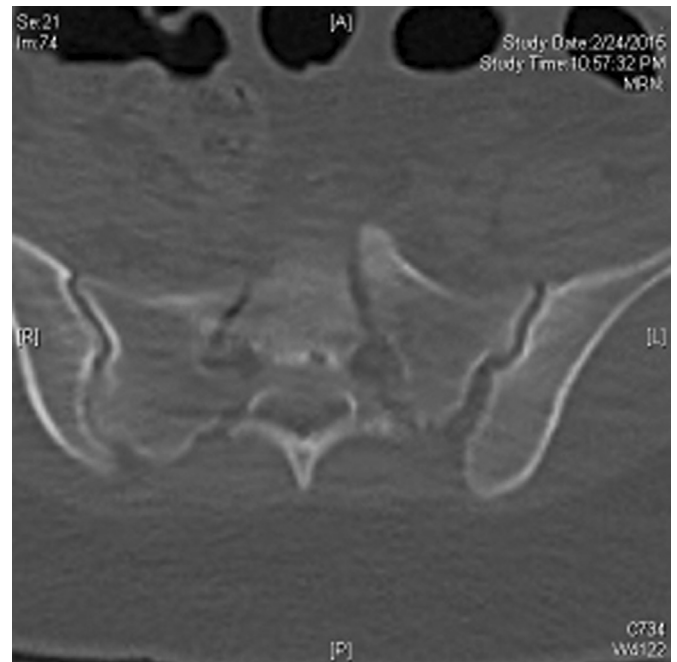


Fig. 3. Plain CT-scan of pelvis showing bilateral sacral fractures.

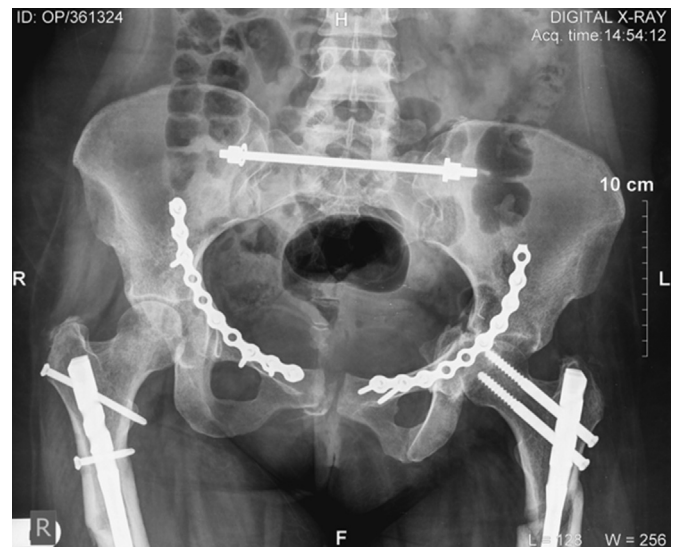

Fig. 4. X-rays pelvic anteroposterior view showing united bilateral anterior column acetabulum fractures and united bilateral sacral fractures.

mobilization with crutches after 2 months of the surgery. She not only survived this major accident but escaped from any major complication related to her fracture and treatment.

Discussion

There is paucity in the literature about the mechanism, priority and optimal treatment of the concomitant unstable pelvic and segmental femoral shaft fractures.⁴ Due to non-availability of suitable guidelines to treat such complex injuries, the optimal treatment of these fractures remains controversial. We consider that combined femoral shaft and unstable pelvic fractures are

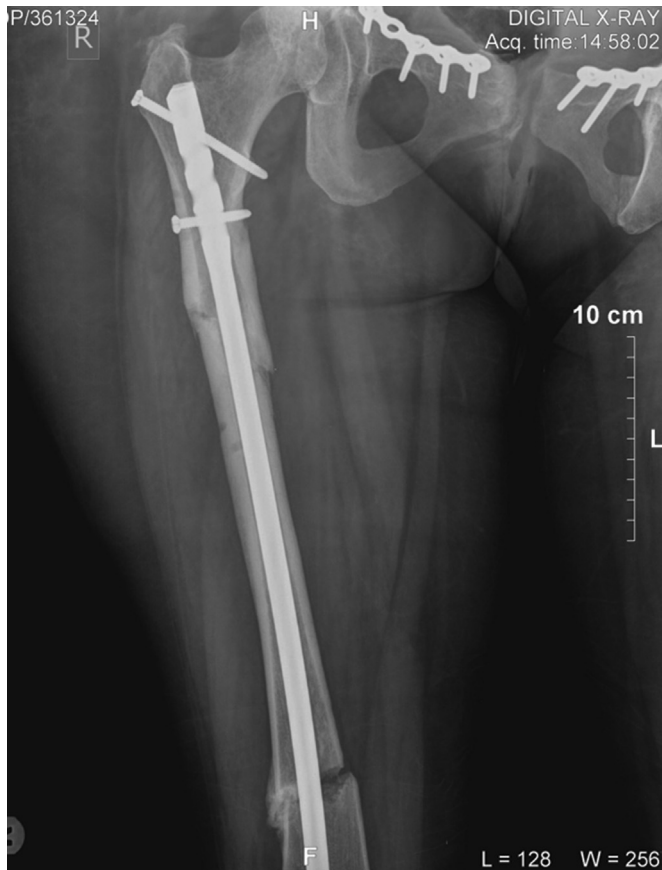

Fig. 5. X-rays anteroposterior view showing united right side segmental fractured femur with nail in situ at 6-month follow-up.

severe injuries and necessitate timely and aggressive management. The femoral fractures need precedence over pelvic fracture fixation.

Understanding the mechanism of such fracture pattern remains a challenge. Malgaigne's fracture is an unstable pelvic fracture through both pubic rami and the ilium or sacroiliac joint with vertical displacement. These fractures result from application of axial force through the femur, through extended knees when a motor vehicle occupant is bracing during frontal collision, or from dashboard injury to the knee, vertical shear forces are involved. A bucket handle fracture refers to an ipsilateral fracture of the pelvis and femur. It is an uncommon injury occurring from the axial force through the femur resulting in a posterior acetabular fracture and femoral shaft fracture. The mechanism of injury, in this case, could have been due to an axial force through the extended knee resulting in vertical shear force in the pelvis leading to bilateral acetabulum fracture and bilateral sacral fracture. The segmental comminuted fracture of bilateral shaft femur might have been due to crushing of both the bones between some heavy objects of the jeep body parts. It is, however, difficult to conceive and explain these injuries with any single mode of injury; as the 4 wheeler had tumbled many times after the initial strike and, therefore, a multi-hit theory only can explain such an injury pattern.

Bilateral femoral fractures associated with unstable pelvic fractures and visceral damage have been reported with a very high mortality and morbidity rate. These patients should be initially managed with the advanced trauma life support (ATLS) protocol^{5,6} and once stable, surgical intervention should be considered. If the patient remains unstable the principles of damage control orthopaedics (DCO) should be followed.⁶ This patient presented to us in a state of shock, thus priority for us was to stabilize the patient hemodynamically and once the patient was stabilized we proceeded for the definitive fixation of the fractures in staged manner, giving priority to femoral shaft fractures.

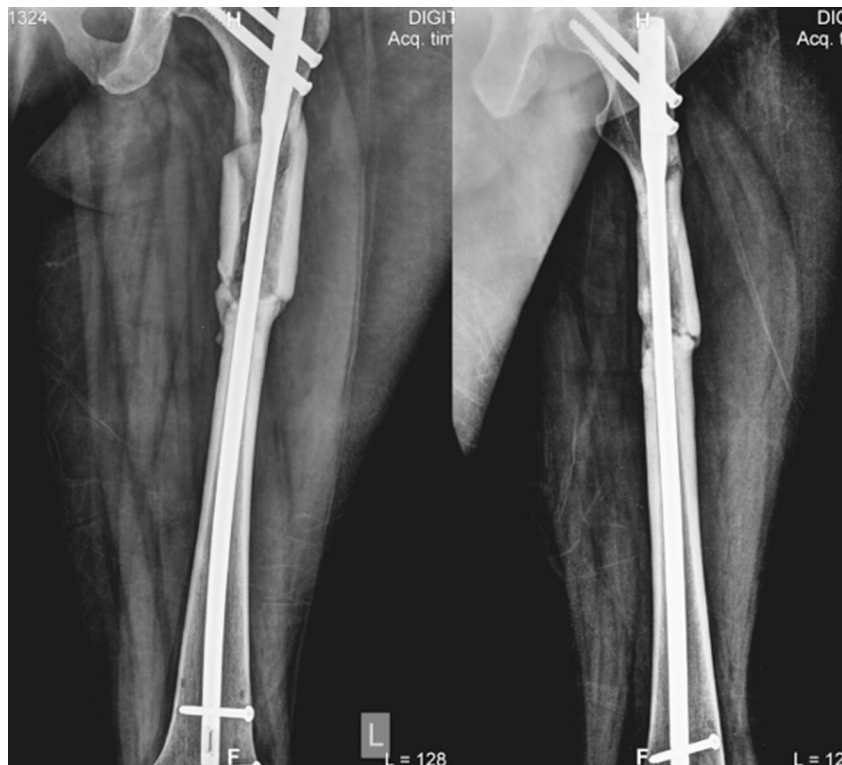

Fig. 6. X-rays anteroposterior and lateral views showing united left side segmental fractured femur with nail in situ at 6-month follow-up.

In this case, we fixed both the femora in the first sitting with an interlocking nail, with minimal reaming. All care was taken to avoid the displacement of the pelvic fracture. The patient was moved gently to the fracture table for the fixation of the femur and gentle traction was applied intraoperatively to prevent secondary injury to the pelvic fractures or to prevent re-bleeding from the pelvic cavity.² Subsequently, in the second sitting an open reduction and internal fixation (ORIF) of bilateral acetabulum fracture and bilateral sacral fractures was done. Tscherne et al⁷ suggested that in patients with multiple closed fractures, femur fractures must be given priority over pelvis.

An early and timely surgical intervention to fix all the major fractures helps the patient to overcome the medical complications and provide better rehabilitation. The data suggest that aggressive resuscitation for multiply-injured patients and early or delayed ORIF without application of external fixation will lead to overall low mortality rate.⁸

References

1. Wu CL, Tseng IC, Huang JW, et al. Unstable pelvic fractures associated with femoral shaft fractures: a retrospective analysis. *Biomed J.* 2013;36:77–83.
2. Willett K, Al-Khateeb H, Kotnis R, et al. Risk of mortality: the relationship with associated injuries and fracture treatment methods in patients with unilateral or bilateral femoral shaft. *J Trauma.* 2010;69:405–410.
3. Westhoff J, Hilderbrand F, Grotz M, et al. Trauma care in Germany. *Injury.* 2003;34:674–683.
4. Wu CC, Shih CH. Femoral shaft fractures associated with unstable pelvic fractures. *J Trauma.* 1993;34:76–81.
5. Stahel PF, Heyde CE, Wyrwich W, et al. Current concepts of polytrauma management: from ATLS to “damage control”. *Orthopade.* 2005;34:823–836.
6. Biffl WL, Smith WR, Moore EE, et al. Evolution of a multidisciplinary clinical pathway for the management of unstable patients with pelvic fractures. *Ann Surg.* 2001;233:843–850.
7. Tscherne H, Regel G, Pape HC, et al. Internal fixation of multiple fractures in patients with polytrauma. *Clin Orthop Relat Res.* 1998;347:62–78.
8. Gruen GS, Leit ME, Gruen RJ, et al. The acute management of hemodynamically unstable multiple trauma patients with pelvic ring fracture. *J Trauma.* 1994;36:706–711.