



Contents lists available at ScienceDirect

## International Journal of Surgery Case Reports

journal homepage: [www.casereports.com](http://www.casereports.com)

## Dieulafoy lesion of the gallbladder presenting with bleeding and a pseudo-mirizzi syndrome: A case report and review of the literature



Aaron Stanes\*, Sean Mackay

Eastern Health Surgical Research Group, Monash University, Eastern Health Clinical School, 5 Arnold St, Box Hill, Melbourne, Victoria 3128, Australia

## ARTICLE INFO

## Article history:

Received 26 January 2016

Received in revised form 27 January 2016

Accepted 28 January 2016

Available online 6 February 2016

## Keywords:

Cholecystectomy

Dieulafoy

Haemobilia

Gallbladder

Gastrointestinal bleeding

## ABSTRACT

**INTRODUCTION:** Gastrointestinal bleeding can have significant morbidity and mortality. Pathological processes that cause it are diverse, and timely investigation and management are vital. Dieulafoy lesions are a rare cause of gastrointestinal bleeding and here we describe a case of a gallbladder dieulafoy lesion causing gastrointestinal bleeding.

**PRESENTATION OF CASE:** Recently discharged from hospital following an open anterior resection and loop ileostomy for diverticular disease, an 84-year-old female re-presented with lower abdominal pain associated with jaundice and lymphocytosis. Imaging demonstrated two possible rectal stump collections (treated with antibiotics), and heterogeneous material in the gallbladder. The patient deteriorated, developing melena, coffee ground vomitus and right upper quadrant pain. Investigation sourced the bleeding to the gallbladder that resolved following cholecystectomy, and histopathology was consistent with a dieulafoy lesion. The patient made a full recovery.

**DISCUSSION:** Dieulafoy lesions have rarely been reported in the gallbladder, and as such can be an occult source of massive gastrointestinal bleeding. It should be considered where gastrointestinal bleeding accompanies jaundice and abdominal pain.

**CONCLUSION:** This case highlights that dieulafoy lesions can occur in the gallbladder. Massive gastrointestinal bleeding can occur within the gallbladder, and a gallbladder dieulafoy lesion should be considered as a potential cause of such, especially when a source has not been identified on endoscopy. It also demonstrates the effectiveness of cholecystectomy as a definitive management strategy.

© 2016 The Authors. Published by Elsevier Ltd. on behalf of IJS Publishing Group Ltd. This is an open access article under the CC BY-NC-ND license (<http://creativecommons.org/licenses/by-nc-nd/4.0/>).

## 1. Introduction

Gastrointestinal bleeding is a clinical presentation that can reflect a variety of pathological processes. Associated morbidity and mortality can be significant, and accordingly, knowledge of all of the potential causes is crucial. Dieulafoy lesions are known causes of gastrointestinal bleeding; however those occurring within the gallbladder are extremely rare. Here we present a case of a dieulafoy lesion within the gallbladder, with extrinsic biliary obstruction secondary to gallbladder distension.

## 2. Presentation of case

An 84-year-old female who lived alone was transferred to our surgical department from sub-acute care with worsening lower abdominal pain, having recently undergone an open anterior resection and loop ileostomy for diverticular disease. The pain was

sharp, constant, and gradual in onset with a sudden worsening on the day of presentation. There was a raised white cell count ( $33.8 \times 10^9/L$ ). She was commenced on routine deep venous thrombosis prophylaxis with 5000 units of dalteparin daily.

Her past history includes osteoarthritis, chronic kidney disease, type two diabetes mellitus, chronic obstructive airways disease and peripheral vascular disease.

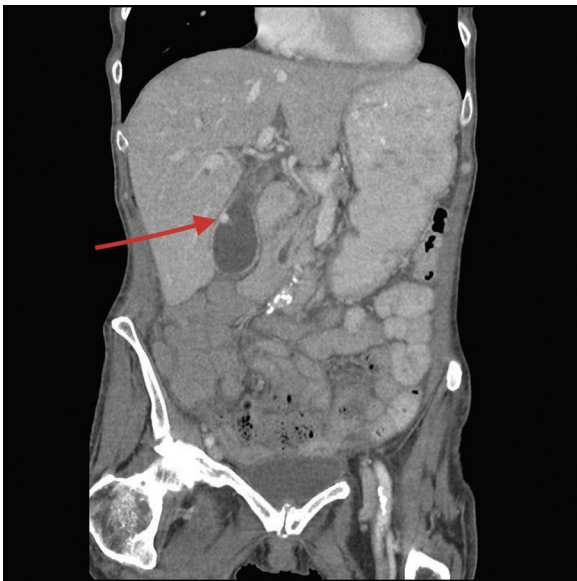On examination there was lower abdominal tenderness with diffuse voluntary guarding. The patient was afebrile, but clinically and biochemically jaundiced. The stoma was functional. CT showed a complex gallbladder with an enhancing mural nodule/hypervascular blush. The lumen was filled with heterogeneous density material (Fig. 1). Two possible collections were noted near the rectal stump. Intravenous antibiotics and pantoprazole were commenced.

The patient developed prolonged melena and haematemesis, and required six units of packed red blood cells. Her lower abdominal pain settled with antibiotics, but then a new abdominal pain developed, localized to the right upper quadrant, in addition to her jaundice and upper gastrointestinal bleeding.

Investigations aimed to characterise the lesion seen on the CT scan and identify the source of bleeding. They included

\* Corresponding author.

E-mail addresses: [aaron.stanes1990@gmail.com](mailto:aaron.stanes1990@gmail.com) (A. Stanes), [sean.mackay@monash.edu](mailto:sean.mackay@monash.edu) (S. Mackay).

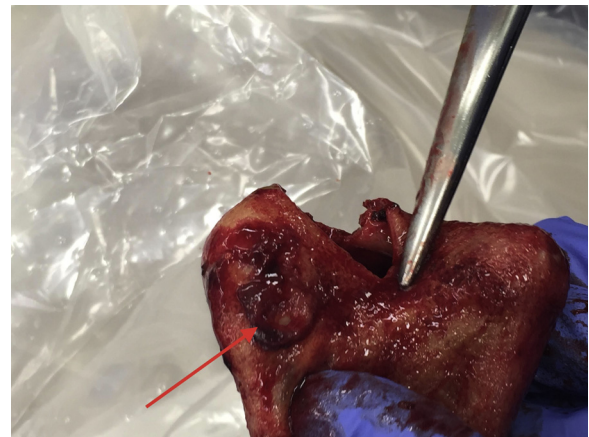


**Fig. 1.** CT axial portal venous showing hypervascular lesion within the gallbladder (arrow).

an abdominal ultrasound, (showing an avascular heterogeneous mass, and predominantly hypoechoic material with cystic spaces within the gallbladder); MRCP (showing biliary tree dilatation to the porta-hepatis where there was evidence of high grade obstruction, gallbladder distension, and fluid extending into Rutherford–Morrison’s pouch); and a gastroscopy (demonstrating an incidental small, superficial D1 ulcer with no active bleeding, and blood in D3). The patient was not tested for H. Pylori during the admission, nor treated for the ulcer, and is awaiting further follow up for investigation and management of this.

The initial presentation was one suggesting two concurrent pathological processes. The jaundice suggested a biliary disease, and this was reinforced by the abnormal gallbladder on CT scan at admission, however her initial pain was consistent with the para-rectal collections also seen on CT. The patient was accordingly treated with antibiotics for the collections. The development of the right upper quadrant pain prompted attention primarily towards the biliary tract.

A combination of these secondary symptoms and investigation findings, led to the localisation of the pathology to the gallbladder. The heterogeneous material in the gallbladder as seen on CT scan



**Fig. 3.** Post-operative photo of the opened gallbladder showing the Dieulafoy lesion macroscopically (arrow).

reinforced this. The initial impression was one of haemorrhagic cholecystitis, with the bleeding secondary to gallbladder inflammation.

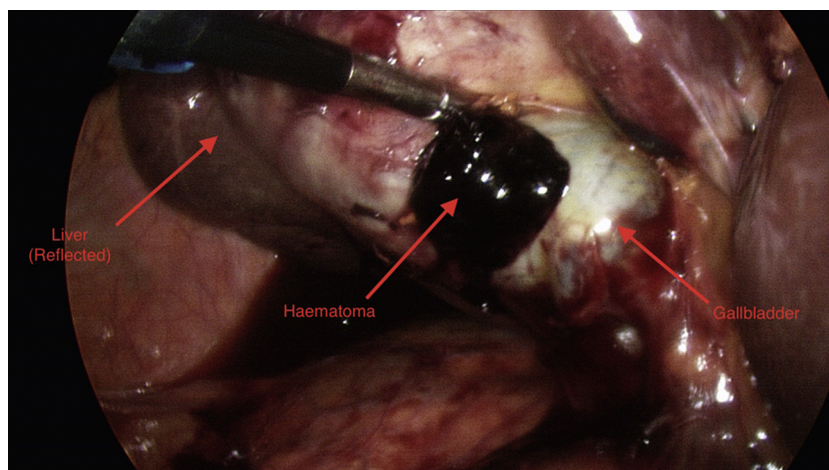
Cholecystectomy and cholangiogram were performed with the view that the bleeding was originating within the gallbladder and that biliary compression was secondary to extrinsic bile duct compression by the distended gall bladder (as there was no convincing pre-operative evidence of intra-ductal obstruction).

The gallbladder was distended and was inadvertently entered during the dissection, with a clot and organised haematoma expressed (Fig. 2). Intra-operative cholangiogram was normal reinforcing the impression of extrinsic biliary tract compression. The specimen was opened and a small ulcerative lesion noted (Fig. 3).

Histopathology demonstrated an 81 × 45 mm gallbladder with active chronic cholecystitis and mucosal ulceration. There was a 2 mm calibre artery seen at the ulcer base.

The final diagnosis was a dieulafoy lesion of the gallbladder with mild chronic cholecystitis. The obstructive jaundice was due to extrinsic compression of the common bile duct by the distended gallbladder.

Post-operatively the patient’s condition rapidly stabilized and improved due to the surgical removal of both the source of blood loss and biliary tree compression. Review at four weeks post surgery revealed a well patient. She was discharged from clinic, and is currently awaiting reversal of her ileostomy.



**Fig. 2.** Intraoperative photo showing haematoma following entering of the distended gallbladder.

### 3. Discussion

Our case constitutes the third reported diagnosis of a gallbladder dieulafoy lesion in the English literature. It is characterized by an abnormally large calibre, tortuous arteriole in the submucosa of the gastrointestinal tract with a base of fibrinoid necrosis that bleeds through mucosal erosion with an absence of inflammation at the boundaries of the erosion [1,2]. According to Reilly and Al-Kawas, there is a persistent calibre vessel in the submucosa that is exposed through pressure erosion [3].

Dieulafoy lesions are very rare in the gallbladder, but less so elsewhere in the gastrointestinal tract, and they account for approximately 5% of all gastrointestinal haemorrhages. They occur most frequently in the stomach, but can occur elsewhere inside and outside the gastrointestinal tract. The mortality is similar to other causes of gastrointestinal haemorrhage [4].

Lara et al. identified 63 cases of gastrointestinal dieulafoy lesions in a combined retrospective and prospective cohort across five years and three months and found that the majority of cases were male (40:23, M:F) and the mean age was 60.7 years. Additionally, 24 cases were anticoagulated (24% took aspirin, 8% took warfarin, 6% took clopidogrel), 56 cases were upper gastrointestinal, and the mortality was 17% [4].

Schmulewitz and Baillie in a review of 40 cases of dieulafoy lesions reported that between 61% and 82% are found in the proximal one third, and up to 98% in the proximal half of the stomach. They suggest that this may be related to the lesser curvature deriving its blood supply directly from gastric artery tributaries. They also described 17 cases having other abnormalities that could contribute to bleeding (oesophagitis, erosions, varices, angioectasias, diverticulosis) [2].

In the extensive literature review of dieulafoy lesions by Reilly and Al-Kawas (177 cases), the age range was 16–93 with a median of 58 years. 51% of their cases presented with haematemesis and melena, 28% presented with haematemesis alone and 18% presented with melena alone [3].

Our case is the third report of a dieulafoy lesion of the gallbladder in the English-speaking literature. Details of the previous two cases are as follows.

Hashimoto et al. described a 56-year-old male with no previous abdominal surgery presenting with severe epigastric pain and guarding with a leukocytosis, deranged LFT's and anaemia. Percutaneous transhepatic gallbladder drainage yielded large volume fresh blood, with urgent laparoscopic cholecystectomy following. Histopathology revealed mild chronic cholecystitis with a dieulafoy lesion [1].

Maszkowicz and Houdart described a 63-year-old female presenting with progressive abdominal pain, nausea and vomiting with focal RUQ tenderness. Investigations revealed normal leukocytes, but elevated LFT's and anaemia. CT demonstrated a distended gallbladder filled with hyperdense haemorrhagic bile, and the diagnosis of ischaemic cholecystitis with a dieulafoy lesion was made. Definitive management was a laparoscopic cholecystectomy [5].

Comparing these to our case, the presentations appear similar. Our patient presented with right upper quadrant pain, jaundice and upper gastrointestinal bleeding, a triad described in 1871 by German surgeon Heinrich Quincke that predicts haemobilia in 22–37.9% of cases [6,7].

The jaundice present in haemobilia is explained by Chin and Enns. In their review of haemobilia, they described how the differences in density between bile and blood lead to clot formation; with obstruction occurring secondary to this [7]. A clear cholangiogram in our case implies a different cause.

The obstructive picture was due to extrinsic compression of the common bile duct by the distended gallbladder. Mergener et al. and Ippolito both described a pseudo-mirizzi syndrome whereby their

cases of acute cholecystitis presented with an obstructive picture due to compression of the common hepatic duct by a massively distended gallbladder [8,9]. This principle of obstruction applies in our case, albeit the obstruction location and cause of the gallbladder distension differed.

Our case was managed definitively with laparoscopic cholecystectomy, and the efficacy of timely surgical intervention led to immediate stabilisation of our patient's clinical condition. It highlights the key clinical features of abdominal pain, gastrointestinal bleeding and jaundice that should immediately lead to the suspicion of gallbladder bleeding. Additionally it clarifies a novel pathophysiology of obstructive jaundice by extrinsic compression that may lead to diagnostic dilemmas in cases of a clear biliary tree if not previously known.

### 4. Conclusion

This case adds to the current literature that dieulafoy lesions can occur in the gallbladder—it should be on the list of rare but potentially serious causes of gastrointestinal bleeding, in cases where there is definite upper gastrointestinal tract loss, and an unremarkable upper gastrointestinal endoscopy. Additionally, obstructive jaundice may occur due to an intra-ductal clot, or a pseudo-Mirizzi syndrome with extrinsic biliary tree compression by a blood-distended gallbladder, and cholecystectomy is a definitive and timely surgical management strategy in haemodynamically stable patients.

### Consent

Written informed consent was obtained from the patient for publication of this case report and accompanying images. A copy of the written consent is available for review by the Editor-in-Chief of this journal on request.

### Authorship

All authors contributed equally to the research and preparation of this case report.

### Care guidelines

This case report was written and reported in accordance with the CARE guidelines and criteria [10].

### Conflicts of interest

None.

### References

- [1] Y. Hashimoto, S. Akagi, Y. Sakashita, M. Takamura, H. Iwako, Y. Watadani, et al., Dieulafoy's disease as a possible cause of gallbladder haemorrhage, *J. Gastroenterol. Hepatol.* 22 (2007) 1349–1351.
- [2] N. Schmulewitz, J. Baillie, Dieulafoy lesions: a review of 6 years of experience at a tertiary referral center, *Am. J. Gastroenterol.* 96 (6) (2001) 1688–1693.
- [3] H.F. Reilly, F.H. Al-Kawas, Dieulafoy's lesion diagnosis and management, *Dig. Dis. Sci.* 36 (12) (1991) 1702–1707.
- [4] L.F. Lara, J. Sreenarasimhaiah, S. Tang, B.B. Afonso, D.C. Rockey, Dieulafoy lesions of the GI tract: localisation and therapeutic outcomes, *Dig. Dis. Sci.* 55 (2010) 3436–3441.
- [5] D. Moszkowicz, R. Houdart, Dieulafoy's lesion of the gallbladder, *Surg. Radiol. Anat.* 36 (2014) 307–308.
- [6] H. Quincke, Ein fall von aneurysma der leberarterie, *Berl Klein Wochenschr.* 30 (1871) 349–352.
- [7] M.W. Chin, R. Enns, Hemobilia, *Curr. Gastroenterol. Rep.* 12 (2010) 121–129.

- [8] K. Mergener, R. Enns, W.S. Eubanks, J. Baillie, M.S. Branch, Pseudo-Mirizzi syndrome in acute cholecystitis, *Am. J. Gastroenterol.* 93 (1998) 2605–2606.
- [9] R.J. Ippolito, Acute acalculous cholecystitis associated with common hepatic duct obstruction: a variant of Mirizzi's syndrome, *Conn. Med.* 57 (1993) 451–455.
- [10] J.J. Gagnier, G. Kienle, D.G. Altman, D. Moher, H. Sox, D. Riley, The CARE guidelines: consensus-based clinical case reporting guideline development, *Headache* 53 (2013) 1541–1547.

#### Open Access

This article is published Open Access at [scimedirect.com](http://scimedirect.com). It is distributed under the [IJSCR Supplemental terms and conditions](#), which permits unrestricted non commercial use, distribution, and reproduction in any medium, provided the original authors and source are credited.