

# The Diagon/Gel Implant: A Preliminary Report of 894 Cases

Constantin Stan, MD\*  
Thomas Biggs, MD†

**Background:** The breast has always been perceived as the emblem of femininity. Desire of having an ideal breast form has been of interest for a long time.

**Methods:** This preliminary article is a retrospective analysis of 894 cases of breast augmentation with Diagon/Gel breast implants covered with a micropolyurethane foam (Microthane). The surgical technique employed is a modified dual plane, which enables us to use a new anatomical implant to move the glandular parenchyma into a higher position.

**Results:** The study extended from January 2010 to September 2015, during which no breast implant developed Baker grade III or IV capsular contracture (CC) and only a few adverse events occurred. Patients reported to be highly satisfied with the final outcome, which was very natural both in the form and movement.

**Conclusions:** The new concept of Diagon/Gel represents the next step in the evolutionary progress of breast implants and allows the surgeon to perform not only a breast augmentation but also parenchymal elevation, which otherwise would have required a mastopexy, and we have called it breast enhancement. (*Plast Reconstr Surg Glob Open* 2017;5:e1393; doi: 10.1097/GOX.0000000000001393; Published online 5 July 2017.)

## INTRODUCTION

Perusal of ancient art shows us that the female breast has been a distinct figure in representation of the female gender and clothing and artificial supports have been created in its enhancement.

The silicone breast implant has been the 20th century's contribution to this effort and, like all advances, the implant has undergone significant evolution.<sup>1-4</sup>

As with all evolutionary steps, problems arose warranting some alteration in the technique of the operation or in the implant itself. Without changing the basic structure of the silicone, molecular changes were made in the gel, shell, shape, and the technique for its insertion.<sup>5-8</sup>

Although some changes were faulty, most were steps forward in seeking our goal of perfection.<sup>9</sup>

This is a preliminary report of a new breast implant, the Diagon/Gel, with a further refined gel, a different shell, and a different technical maneuver, a modified dual plane, to improve the final shape of the breast. These changes (different shape and double gel implant, and

repositioning of parenchyma) with comparisons of traditional modern techniques depict another progress in breast augmentation.

We disclose our experience with the newest implant on this stage used in conjunction with a parenchymal elevation, which we choose to call "breast enhancement."

## MATERIALS AND METHODS

The change of implants resulted in the silicone-gel-filled Diagon/Gel implant series used for 894 patients from January 1, 2010, to September 30, 2015, in S Clinic by the same surgeon, the first author. The design enables a deliberately reduced range of sizes with a large variety of projections.

All the Diagon/Gel breast implants employed in this study were shaped with an anatomical profile and a round or an oval base, either horizontal or vertical.

The Diagon/Gel implants were filled with 2 highly cross-linked, cohesive, form-stable gels. The softer EasyFit Gel™ at the back facilitates a smooth fit of the implant to the rib cage.<sup>10</sup> In our experience, when this implant was placed on the chest wall beneath the pectoral muscle, it was felt to move more naturally than implants used in the past.

**Disclosure:** The authors have no financial interest to declare in relation to the content of this article. No funding was received for the creation of this article. The senior author (Thomas Biggs) is a consultant for Polytech Health & Aesthetics. The Article Processing Charge was paid for by the authors.

From the \*S Clinic, Bucharest, Romania; and †Houston, Tex.

Received for publication May 18, 2016; accepted May 5, 2017.

Copyright © 2017 The Authors. Published by Wolters Kluwer Health, Inc. on behalf of The American Society of Plastic Surgeons. This is an open-access article distributed under the terms of the Creative Commons Attribution-Non Commercial-No Derivatives License 4.0 (CCBY-NC-ND), where it is permissible to download and share the work provided it is properly cited. The work cannot be changed in any way or used commercially without permission from the journal.

DOI: 10.1097/GOX.0000000000001393

The firmer Shapar Gel at the front of the dome-shaped projection facilitates nipple positioning and supports the residual breast tissue in push-up style.<sup>10</sup>

The 2 different gels are obtained by 2 different thermodynamic curing cross-linking processes that lead to a minimal risk of delamination and to a low risk of gel fracture. The maximum implant projection is in the lower 25% of the anterior surface and is the only implant with this quality.<sup>10</sup>

The chemically and mechanically resistant elastic shell of the implants consists of several layers of a silicone elastomer, including a diffusion barrier layer. Due to the soft gel in the posterior implant section, the edges of the shell are almost imperceptible.<sup>10</sup>

The surface of the implant shell used in this study is covered by Microthane, a micropolyurethane foam (Polytech Health & Aesthetics, Dieburg, Germany). This surface is known for its reliability and has been proven to contribute to a significant reduction of capsular contracture (CC) rates. In addition, the foam adheres to the tissues, preventing rotation or slipping in its position.<sup>8,11-17</sup>

The surgical technique we have utilized for obtaining a breast enhancement with Diagon/Gel implants is a modified dual plane. In cases of mild or moderate ptosis, we create a second surgical space behind the glandular parenchyma superficial with respect to the pectoralis major, and the parenchyma from the upper pole is mobilized slightly higher and more medially with 2 absorbable sutures. This procedure allows us to not only place an implant for adding volume but also to rearrange the parenchyma, thus enacting more completely a breast enhancement rather than a simpler augmentation. The first author (C.S.) conducted each postoperative follow-up session at 10 days; 1, 3, 6, and 12 months; and steadily once a year with clinical examination and the aid of ultrasound imaging. Breast consistency, shape, volume, position, and patient's satisfaction were evaluated during each annual control visit.

To collect as much information as possible, a questionnaire was recently sent to all the 894 S Clinic patients, including patients living 300 km far from this center or outside Romania. The questionnaire was designed to discover any unnoticed complication or undesirable sensation.

Each patient who disclosed new symptoms was encouraged to come back to Dr. Stan's office for additional consultations.

## RESULTS

From January 1, 2010 to September 30, 2015, 894 women underwent breast augmentation at the S Clinic in Bucharest. Of these, 763 were primary aesthetic breast augmentations and 131 were secondary cases. All the patients received shaped Diagon/Gel breast implants covered with Microthane.

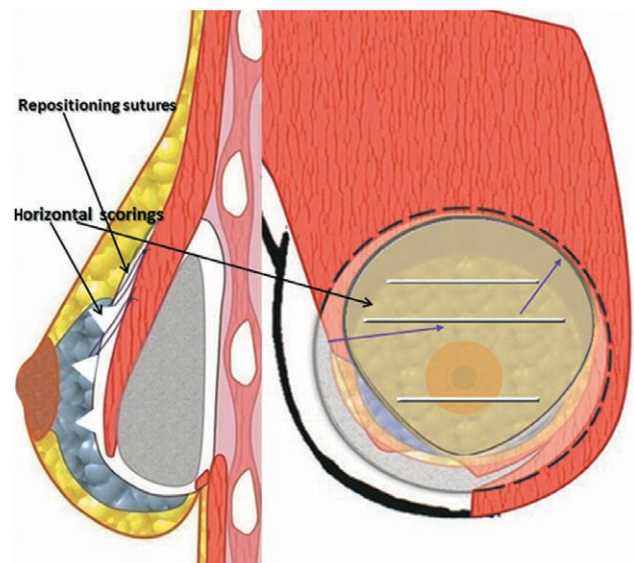
In all cases, the Diagon implant was combined with a modified dual-plane technique. Inframammary-fold incisions were the only incision sites employed. In cases of breasts without ptosis, implants were inserted in a submuscular pocket. The glandular parenchyma was dis-

sected from the muscle to allow a better expansion and repositioned. Some horizontal scorings have been done in the posterior parenchymal wall to improve the expansion of tight breasts. The origin of the pectoralis major was released all along the inferomedial fold. To prevent the problem of window shade effect, the release of the pectoralis major was very modest, taking care to never go beyond the lower edge of the areola. In case of moderate ptosis, 2 repositioning sutures were placed in the cephalad portion of the parenchyma and elevated into appropriate position onto the pectoralis major (Fig. 1).

Regarding the shape of breast implants, 760 were anatomical with oval base and 134 were anatomical with round base, whereas 93% had a extra-high projection and 7% a high projection. Implant volume varied dependent on the dimension of the implant, but the average in the series was 270 cc.

All the 894 women received breast implants for aesthetic purposes. Seven hundred sixty-three of them underwent a primary breast augmentation to enhance their body appearance limited by breast hypoplasia (62%), postpartum ptosis (25%), tuberous breast deformity (7%), or breast asymmetry (6%).

One hundred thirty-one women underwent a secondary breast augmentation due to difficulties after a previous insertion of textured breast implants of different brands. The primary cause was fibrous CC (71 patients), followed by implant rupture (47 patients) and seroma (13 patients). Whether the previous implant was placed in submuscular position, we have always performed a total capsulectomy inserting the new implant in the same submuscular pocket. In case the placement of the previous implant was subglandular, we have designed a new submuscular pocket, performing a partial capsulectomy in the lower part. The age range in the study was from 18 years to 61 years.



**Fig. 1.** Modified dual plane: indications and surgical principles. After the implant has been placed behind the pectoral muscle, in case of moderate ptosis 2 repositioning sutures are placed in the cephalad portion of the parenchyma and elevated into appropriate position onto the great pectoralis muscle.

Of the total patients, 10% were lost after 1 year of follow-up, 30% after 2 years of follow-up, 50% after 3 years of follow-up, and 60% after 4 years of follow-up.

Of the 1,788 breasts evaluated, no one was diagnosed with III or IV Baker grade CC. There was no incidence of dislocation or rotation of the implants.

Two late seromas arose after 3 years from breast augmentation with Microthane Diagon/Gel. Both the patients who underwent implant removal did not develop anaplastic large cell lymphoma (negative to CD30 test).

One patient showed an anterior bending of the implant that required a secondary breast augmentation with the same type of implants.

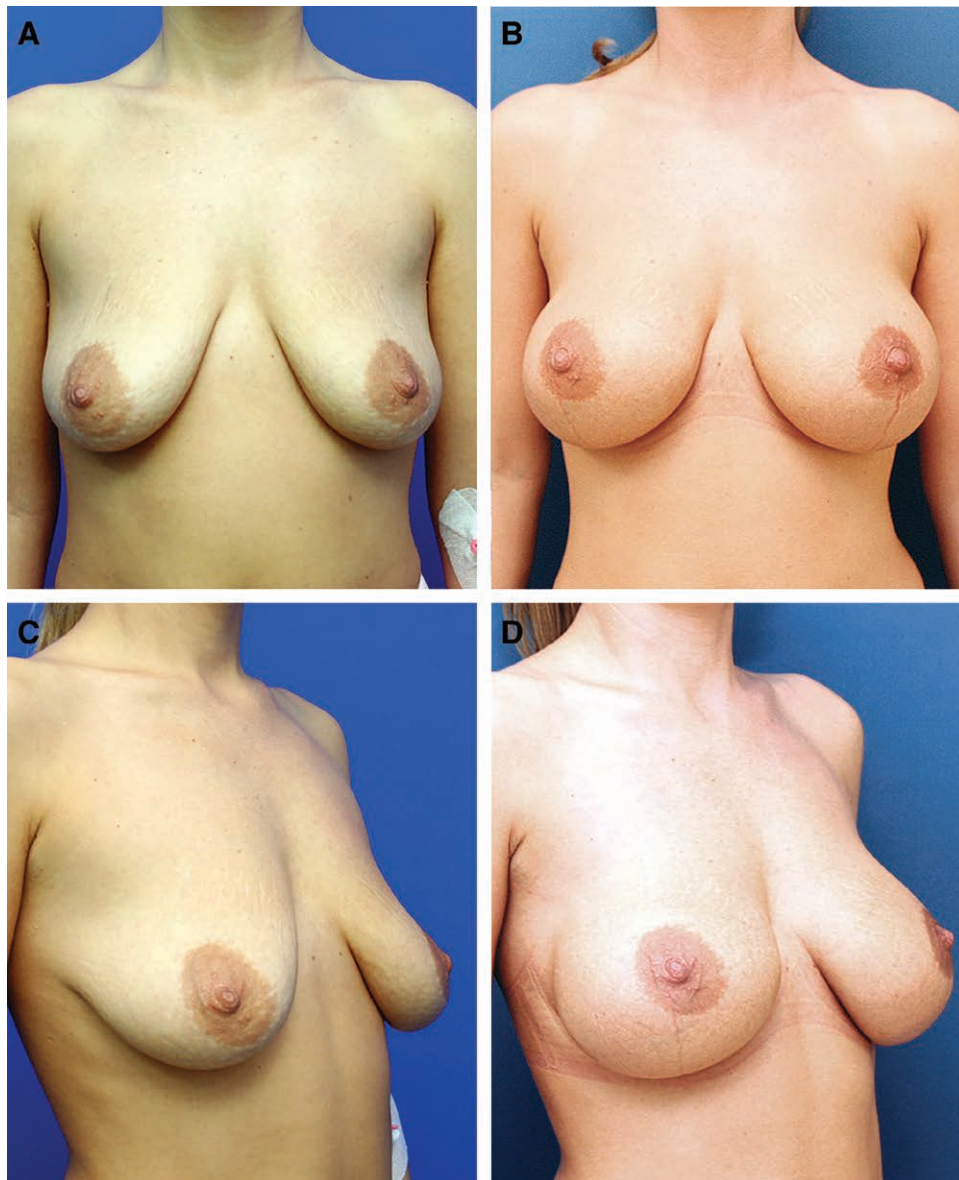Two patients underwent a revisional surgery for their desire to modify breast volume. In both cases, a total cap-

sulectomy was performed and new polyurethane-covered Diagon/Gel implants were inserted.

One 65-year-old patient, having received Diagon/Gel, wished to substitute these implants with softer devices. The implants were removed after a few months and replaced with polyurethane anatomic implants (Replicon, Sublime Line, Polytech Health & Aesthetics, GmbH).

Four cases of hypertrophic scars appeared after an average of 3 years from the breast surgery. All the cases were treated with 5-fluorouracil (5-FU) and corticosteroids as adjuvant therapy.

Ten cases of unsatisfactory breast shape in the outer lateral inferior quadrant emerged about 6 months after the surgery. These cases of pseudo-ptosis were settled with lipofilling sessions.



**Fig. 2.** Clinical case I: front view of a patient before surgery (A) and 2 years after surgery with anatomical Style 510 textured implants (Allergan) of 385 cc and dual-plane technique (B). Clinical case I: lateral view of a patient before surgery (C) and 2 years after surgery with anatomical Style 510 textured implants (Allergan) of 385 cc and dual-plane technique (D).

Two small seromas in the inferior pole (diagnosed with ultrasound imaging) resolved spontaneously.

Four small hematomas appeared immediately after the surgery, but they disappeared in a few hours.

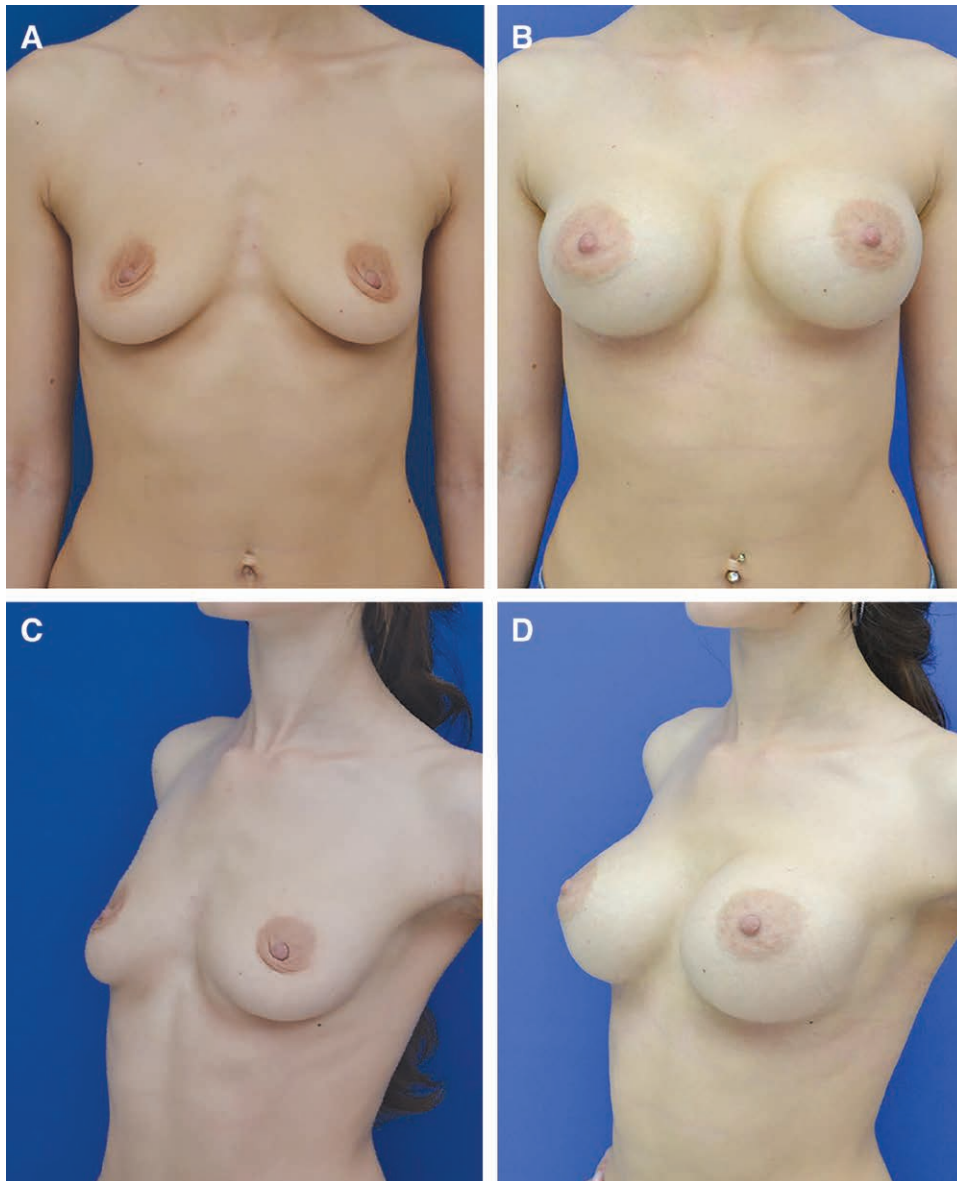
One case of moderate implant animation arose in a patient with a previous slight ptosis and was operated upon by performing a dissection of the pectoralis major. No postoperative intervention was required because the result was acceptable for the patient.

Patient's satisfaction was estimated on a scale from 1 to 5. At the end of the observation period, 90% of patients under constant control revealed to be either satisfied or extremely satisfied with the outcomes (levels of satisfaction that ranged from 4 to 5).

Figure 2 shows a patient before and after 2 years from the insertion of an old textured implant with the traditional surgical technique. In contrast, Figure 3 shows the outcomes of the breast enhancement using a modified dual plane with parenchymal elevation and the Diagon/Gel implant covered with Microthane.

## DISCUSSION

In an effort to achieve better results in breast augmentation, surgeons and manufacturers have created increasingly better implants.<sup>18,19</sup> In conjunction with better implants, techniques have improved.<sup>20,21</sup> This preliminary report indicates that the Diagon/Gel implant combined



**Fig. 3.** Clinical case II: front view of a patient before surgery (A) and 2 years after surgery with extra-high-profile Microthane Diagon/Gel implants (Polytech Health & Aesthetics) of 285 cc and modified dual-plane technique with repositioning sutures (B). Clinical case II: lateral view of a patient before surgery (C) and 2 years after surgery with extra-high-profile Microthane Diagon/Gel implants (Polytech Health & Aesthetics) of 285 cc and modified dual-plane technique with repositioning sutures (D).

with a micropolyurethane coat and the rotation of a portion of the upper pole parenchyma superiorly and often medially has taken us to a new level in our pursuit of excellence. The shape of the implant and its maximum projection in the lower 25%, in conjunction with the parenchymal replacement is, in effect, a mastopexy in more modest cases of ptosis enacted through the simple infra-mammary incision.

### CONCLUSIONS

This study, by its preliminary nature, does not reach the level of statistical significance, but the high level of satisfaction and the very low occurrence of any disturbing consequences validate both the new shape of the implant and the described technique of parenchymal modification for those who wish to accept them as further aspects of progress in breast augmentation or, preferably, breast enhancement.

Constantin Stan, MD  
S Clinic  
Bucharest  
Romania  
Email: drstan@cms.ro

### ACKNOWLEDGMENTS

The authors acknowledge the contribution of Dr. Luana Clerico, Polytech Health & Aesthetics, Dieburg, Germany, who assisted in Diagon/Gel breast implant description.

### REFERENCES

- Berry MG, Davies DM. Breast augmentation: part I—a review of the silicone prosthesis. *J Plast Reconstr Aesthet Surg.* 2010;63:1761–1768.
- Nahabedian MY. Explantation of 41-year-old implants following primary breast augmentation. *Ann Plast Surg.* 2007;58:91–94.
- Young VL, Watson ME. Breast implant research: where we have been, where we are, where we need to go. *Clin Plast Surg.* 2001;28:451–83, vi.
- Cronin T, Gerow FJ. Augmentation mammoplasty: a new “natural feel” prosthesis. In: *Transactions of the Third International Congress of Plastic Surgery.* Amsterdam, The Netherlands: Excerpta Medica Foundation; 1963:41–49.
- Ashley FL. A new type of breast prosthesis. Preliminary report. *Plast Reconstr Surg.* 1970;45:421–424.
- Ashley FL. Further studies on the natural-Y breast prosthesis. *Plast Reconstr Surg.* 1972;49:414–419.
- Biggs TM, Cukier J, Worthing LF. Augmentation mammoplasty: a review of 18 years. *Plast Reconstr Surg.* 1982;69:445–452.
- Handel N, Cordray T, Gutierrez J, et al. A long-term study of outcomes, complications, and patient satisfaction with breast implants. *Plast Reconstr Surg.* 2006;117:757–767; discussion 768.
- Somogyi RB, Brown MH. Outcomes in primary breast augmentation: a single surgeon’s review of 1539 consecutive cases. *Plast Reconstr Surg.* 2015;135:87–97.
- Brunnert KE. The micropolyurethane foam-coated Diagon/Gel4Two implant in aesthetic and reconstructive breast surgery—3-year results of an ongoing study. *GMS Interdiscip Plast Reconstr Surg DGPW.* 2015;4:Doc20.
- Gasperoni C, Salgarello M, Gargani G. Polyurethane-covered mammary implants: a 12-year experience. *Ann Plast Surg.* 1992;29:303–308.
- Vázquez G. A ten-year experience using polyurethane-covered breast implants. *Aesthetic Plast Surg.* 1999;23:189–196.
- Handel N, Gutierrez J. Long-term safety and efficacy of polyurethane foam-covered breast implants. *Aesthet Surg J.* 2006;26:265–274.
- Vázquez G, Pellón A. Polyurethane-coated silicone gel breast implants used for 18 years. *Aesthetic Plast Surg.* 2007;31:330–336.
- Pompei S, Arelli F, Labardi L, et al. Breast reconstruction with polyurethane implants: preliminary report. *Eur J Plastic Surg.* 2012;35:441–447.
- Pompei S, Evangelidou D, Arelli F, et al. The modern polyurethane-coated implant in breast augmentation: long-term clinical experience. *Aesthet Surg J.* 2016;36:1124–1129.
- Pompei S, Arelli F, Labardi L, et al. Polyurethane implants in 2-stage breast reconstruction: 9-year clinical experience. *Aesthet Surg J.* 2017;37:171–176.
- Henderson PW, Nash D, Laskowski M, et al. Objective comparison of commercially available breast implant devices. *Aesthetic Plast Surg.* 2015;39:724–732.
- del Yerro JL, Vegas MR, Fernandez V, et al. Selecting the implant height in breast augmentation with anatomical prosthesis: the “number Y”. *Plast Reconstr Surg.* 2013;131:1404–1412.
- Wise DM. The lower island flap transposition (LIFT) technique for control of the upper pole in circumvertical mastopexy. *Plast Reconstr Surg.* 2015;135:783e–784e.
- Beale EW, Ramanadham S, Harrison B, et al. Achieving predictability in augmentation mastopexy. *Plast Reconstr Surg.* 2014;133:284e–292e.