



Paediatric Cancer

Tuberculosis Coexistence in Pediatric Hodgkin's Lymphoma: A Tropical Country Experience

Maneya Padma¹ Nuthan Kumar¹ Jyothi Munireddy¹ Arun Kumar¹ Pooja Chebbi Gujjal¹
S. Chennagiri Premalata²

¹Department of Pediatric Oncology, Kidwai Cancer Institute, Bengaluru, Karnataka, India

²Department of Pathology, Kidwai Cancer Institute, Bengaluru, Karnataka, India

Address for correspondence Nuthan Kumar, MBBS MD.

Post doctoral fellowship in PHO, Department of Pediatric Oncology, Kidwai Cancer Institute, Bengaluru, Karnataka, India (e-mail: nuthanraga28@gmail.com).

South Asian J Cancer 2021;9:236–239.

Abstract



Dr Nuthan Kumar

Keywords

- ▶ acid-fast bacillus
- ▶ coexistence
- ▶ Hodgkin's lymphoma
- ▶ tuberculosis

Introduction Hodgkin's lymphoma (HL), being one of the common cancers among children, may occasionally masquerade as an infectious illness. Similarly, an underlying infection like tuberculosis (TB) may be missed in cases of HL because of similarity in clinical and radiological features. Here, we present our data of association of HL with histopathologically proven TB lymph node, their clinical presentation, treatment details, and outcome.

Materials and Methods A retrospective review of all the cases of HL diagnosed between January 2007 and December 2016 was done. The cases which had an association of TB, based on the histopathology, were reviewed separately.

Results A total of 262 children with HL were treated at our institute from January 2007 to December 2016. Of these cases, 42 children had received empirical antitubercular therapy (ATT) (due to suspicion of TB) before presenting to us, and only five cases had histopathologically proven TB lymph node. Ziehl–Neelsen (ZN) stain for acid-fast bacilli (AFB) was positive in the biopsy specimen of all the five cases, proving TB lymph node coexistence with HL. They were treated with six-drug ATT as per the Revised National Tuberculosis Control Program (RNTCP) guidelines along with chemotherapy with adriamycin, bleomycin, vinblastine, and dacarbazine regimen. All the five patients are healthy and disease free until their last follow-up.

Conclusion A high-end suspicion for concomitant TB and HL is needed, especially in our country where TB is still rampant. Biopsy with immunohistochemistry and demonstration of AFB can enable a definite diagnosis of both the entities.

Introduction

Lymphoma is the third most common cancer among children (aged 14 years or younger) worldwide. There are mainly two broad categories of lymphoma, namely Hodgkin's lymphoma (HL) and nonHodgkin's lymphoma (NHL). Lymphomas may occasionally masquerade as an infectious illness.¹ Similarly, an underlying infection like tuberculosis (TB) may be missed in

cases of lymphoma, especially HL, because of similarity in clinical and radiological features.² Cell-mediated immunodeficiency is well known in HL, which may result in infections such as TB, especially in developing countries like India where TB is still a major concern and is widely prevalent.^{3,4} Here, we present data from a tertiary care cancer center in South India on children who had an association of HL with histopathologically proven TB, their clinical presentation, treatment details, and outcome.

DOI <https://doi.org/10.1055/s-0041-1723629> **ISSN** 2278-330X.

How to cite this article: Padma M, Kumar N, Munireddy J, Kumar A, Gujjal P. C, Premalata S. C. Tuberculosis Coexistence in Pediatric Hodgkin's Lymphoma: A Tropical Country Experience. *South Asian J Cancer* 2021;9(4):236–239.

© 2021. MedIntel Services Pvt Ltd.

This is an open access article published by Thieme under the terms of the Creative Commons Attribution-NonDerivative-NonCommercial-License, permitting copying and reproduction so long as the original work is given appropriate credit. Contents may not be used for commercial purposes, or adapted, remixed, transformed or built upon. (<https://creativecommons.org/licenses/by-nc-nd/4.0/>).

Thieme Medical and Scientific Publishers Private Ltd A-12, Second Floor, Sector -2, NOIDA -201301, India

Materials and Methods

A retrospective review of all the cases of HL diagnosed between January 2007 and December 2016 was done. All the data were obtained from the patients' hospital case records for analysis. The cases which had an association of TB were reviewed separately. Those patients who had already received empirical antitubercular therapy (ATT) before presenting to us were excluded from the study, as there was no evidence to support the presence of TB. Only those patients who had histopathologically proven TB during the diagnosis of HL were included in this study. Demographic features such as age, sex, and socioeconomic status were noted. A detailed family history was taken in each case, including a history of contact with TB. Duration of symptoms was recorded from the time of onset to the time of presentation to the hospital. The presence of TB symptoms was defined as fever, loss of 10% or more of weight in the past 6 months, and drenching night sweats. All patients were examined clinically to look for the involvement of the different nodal groups such as cervical, axillary, mediastinal, inguinal, abdominal, and of the spleen. Bulky disease was defined as the size of lymph nodal mass > 6 cm or mediastinal mass size more than one-third of the maximal thoracic diameter on chest X-ray.⁵ The WHO charts were used for anthropometry.⁶ Diagnosis of HL was confirmed by histopathologic examination of lymph node biopsy and immunohistochemistry. The WHO system was used for pathologic classification.⁷ Staging investigations included baseline chest X-ray, ultrasound abdomen, and CT of neck, chest, abdomen, and pelvis. The Ann Arbor staging system was used to stage the patients.⁸ Koch's workup included Mantoux test and chest X-ray. TB lymph node was diagnosed in these cases of HL, based on the demonstration of acid-fast bacilli (AFB) in the biopsy specimens.

The chemotherapy regimen used at our institute during the study period was adriamycin, bleomycin, vinblastine, and dacarbazine (ABVD). Chemotherapy was initiated after 2 weeks of starting ATT. All patients received six cycles of ABVD as per the institution protocol. Response was assessed after each cycle clinically and radiologically after the completion of six cycles. End-of-therapy response assessment included either positron emission tomography (PET) CT or contrast-enhanced CT, depending on affordability. Complete remission (CR) was defined as complete disappearance of all

clinical and radiologic evidence of disease. Partial remission (PR) was defined as a reduction of > 50% of the tumor area (the product of the two greatest diameters) but less than a CR. The appearance of a new lesion or a 25% increase in an existing lesion was considered progressive disease (PD). All other responses were considered stable disease (SD).⁹ Radiotherapy was given to those who achieved PR and those who had bulky disease at presentation. External beam radiation therapy (EBRT)/involving field radiation therapy (IFRT) was used to deliver RT at a dose of 20 to 36 Gy. ATT as per the Revised National Tuberculosis Control Program (RNTCP) guidelines was initiated for those testing positive for TB adenitis.¹⁰ ATT was given along with the chemotherapy as per the schedule. The toxicity profile was retrieved from the patient files. After the completion of treatment, they were followed-up monthly in the 1st year, 2 monthly in the 2nd year, 3 monthly in the 3rd and 4th years, and 6 monthly in the 5th year.

Results

A total of 262 children with HL were treated at our institute from January 2007 to December 2016. Of these cases, 42 children had received empirical ATT (due to suspicion of TB) before presenting to us, and only five cases had histopathologically proven TB lymph node. The case details are presented in **Table 1**. The median age at diagnosis was 11 years (range: 5–13 years). A male sex preponderance was noted (male:female = 4:1). All the children belonged to lower class as per BG Prasad socioeconomic status classification.¹¹ The median duration of symptoms was 8 months (range: 5–24 months). TB symptoms (fever and weight loss) were present in three of them. The major group of lymph node in all the children was the cervical group. All five of them had concomitant cervical tubercular lymphadenitis and none had evidence of pulmonary/extrapulmonary TB. One child had a history of contact with TB. However, none of them were treated for TB before presenting to us. Three of them had bulky cervical node disease and two presented with multiple discrete lymph nodes. The other groups of lymph nodes involved were the retroperitoneal group in one child and axillary and inguinal group in the other. The remainder did not have any other group of lymph node involvement. Three of them had splenomegaly, with two of them demonstrating hypoechoic lesions on ultrasonography.

Table 1 Characteristics of the cases

Serial number	Age (years)/gender	Symptom duration (months)	History of Koch's contact	Nutritional status	Mantoux test	Bulky disease	B symptoms	Stage	Histology
1	10/male	5	No	Stunted	Negative	No	Yes	3BS	Nodular sclerosis
2	5/male	8	No	Underweight	Negative	Yes	No	2AX	Mixed cellularity
3	11/male	6	No	Underweight Severe stunting	Negative	No	Yes	3BS	Nodular sclerosis
4	13/male	24	Yes	Normal	Positive	Yes	No	3ASX	Nodular sclerosis
5	12/female	12	No	Normal	Negative	Yes	Yes	3BSX	Mixed cellularity

Abbreviations: A, no B symptoms; B, B symptoms; S, spleen; X, bulky.

The final staging of each case is shown in ▶Table 1. Cervical group of lymph nodes was biopsied in all of them. Nodular sclerosis was the histologic subtype in three of them and two had mixed cellularity subtype. Ziehl–Neelsen (ZN) stain for AFB was positive in the biopsy specimen of all the five cases, proving TB lymph node coexistence with HL.

They were treated with six-drug ATT with 2 months of isoniazid, rifampicin, pyrazinamide, and ethambutol followed by 4 months of isoniazid and rifampicin as per the RNTCP guidelines. Chemotherapy with ABVD regimen was initiated at least 2 weeks after starting ATT. All received six cycles of ABVD followed by clinical and radiological response assessment. Two of them attained CR, whereas three of them with bulky disease at presentation attained PR and hence required RT. There were no significant delays in chemotherapy. The median duration of each ABVD cycle was 14 days (range: 14–28 days). Chemotherapy delay was present in two children, one of whom had delay in two cycles, whereas the other had delay in three cycles. Cause of delay in both cases was found to be prolonged neutropenia. The toxicity profile is described in ▶Table 2. No significant toxicity attributable to the addition of ATT drugs to ABVD regimen was noted. All the five patients are healthy and disease-free till their last follow-up.

Discussion

HL is one of the most common malignancies of childhood involving lymph nodes and extranodal sites. Cell-mediated immunodeficiency is a well-known entity associated with HL. This may predispose children with HL to many infections. In India, TB, being one of the common diseases with an annual risk of infection between 2% and 5% in young individuals, can affect these children.⁴ TB can precede or can occur concomitantly with the diagnosis of HL. It can also occur during or after the treatment of HL. Concomitant TB with HL can create a confusion in the diagnosis because of similarities in their clinical, radiological, and pathological presentation. Similarly, TB occurring during or after the treatment of HL can pose difficulty in differentiating resistant or relapsed disease. In this study, we looked at our patients who had concomitant TB with HL at diagnosis.

Cell-mediated immunity plays an important role in the control of mycobacterial infections. T-cells produce a variety

of cytokines which are capable of activating macrophage bacterial activities. In malignancy, this cell-mediated immunity is affected, leading to the spread of the infection and cause symptomatic disease.¹² Many a times, TB in these patients would be in advanced stage before it could be diagnosed.

The distinction between TB and HL can be quite challenging. Both present with similar symptoms such as fever, cough, fatiguability, night sweating, and weight loss. Mantoux test can be negative in HL patients in spite of active TB due to impaired cell-mediated immunity.¹³ Chest X-ray and CT are the basic imaging modalities but might not categorically differentiate the two. Newer modalities such as single positron emission CT or/and PET imaging also do not aid in establishing the diagnosis, as hypermetabolic lesions are not specific for malignancy.¹⁴ Biopsy remains the most specific and sensitive diagnostic procedure. The findings of caseating or necrotizing granulomatous lesions typical for TB can also be found in HL and NHL.¹⁵ Reed–Sternberg cells (R–S cells) are not entirely specific for HL. The expression of CD15 and CD30 antigens on R–S cells is necessary for the diagnosis of classical HL (▶Fig. 1). Similarly, the presence of AFB in biopsy and/or culture is required for the confirmation of TB (▶Fig. 2). A total of five patients had histologically proven HL with concomitant TB lymph node (AFB positive on ZN stain) at our center among those analyzed in the study period.

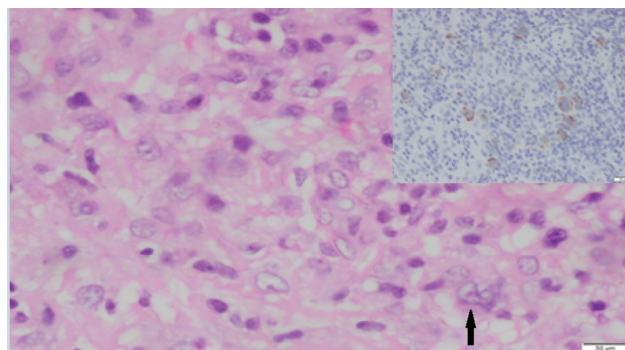


Fig. 1 Hodgkin’s Reed–Sternberg (HRS) cells (arrow) in a background of histiocytes and lymphocytes with prominent acidophilic nucleoli (H and E, ×400). Inset–immunohistochemistry for CD30 showing the characteristic membrane and Golgi pattern of staining in HRS cells (horseradish peroxidase [HRP] polymer method, ×400).

Table 2 Toxicity profile and the outcome of the cases

Serial number	Median/maximum duration of ABVD cycle	Cause for chemotherapy delay	Toxicity	Indication for RT	RT dose	RT modality	Outcome	Follow-up in years
1	15/28	Febrile neutropenia	Grade 4 neutropenia	–	–	–	Survive in CR	7
2	14/17	Febrile neutropenia	Grade 3 neutropenia	BD	24	EBRT	Survive in CR	6
3	15/15	None	Grade 3 neutropenia	–	–	–	Survive in CR	8
4	14/24	Febrile neutropenia	Mild CINV	BD	36	IMRT	Survive in CR	4
5	14/14	None	Mild CINV Hypothyroidism	BD	36	IMRT	Survive in CR	1.5

Abbreviations: ABVD, adriamycin, bleomycin, vinblastine, and dacarbazine; BD, bulky disease; CINV, chemotherapy-induced nausea and vomiting; CR, complete remission; EMRT, external beam radiation therapy; IMRT, intensity-modulated radiation therapy; RT, radiation therapy.

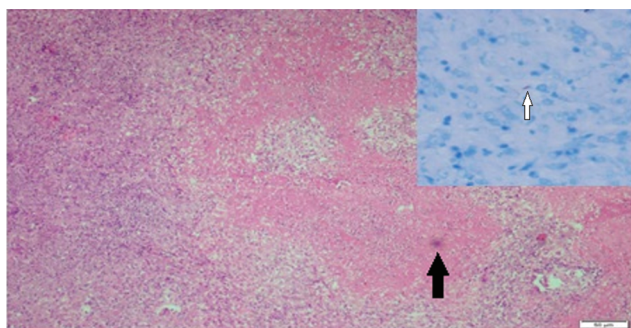


Fig. 2 Caseation necrosis bordered by epithelioid cells and a few giant cells (arrow) (H and E, ×100). Inset showing an acid-fast bacillus AFB) (Ziehl-Neelsen [ZN] stain, ×400).

A large Indian study from Chennai by Radhakrishnan et al comprised 172 patients with HL. Although 32 of them had received empirical ATT before the diagnosis of HL, none had evidence of active TB at diagnosis.¹⁶ In our cohort, 42 had received empirical ATT, while only five had active TB at diagnosis. Karakas et al studied the association of pulmonary TB, specifically with HL.¹⁷ In this study, 14 among 70 children diagnosed in the study period had pulmonary TB, and only two of them had concomitant HL and TB at the time of diagnosis, seven of them developed TB during treatment, and two of them after the cessation of treatment.

TB associated with malignancy can present with atypical features too involving extrapulmonary sites.¹⁸ Codrich et al described TB associated with primary pulmonary Hodgkin's disease.¹⁹ Several reports have described the coexistence of TB and NHL in lymph nodes. It has been reported that the risk of NHL is significantly increased (odds ratio: 1.8) in individuals with a history of TB.²⁰

Conclusion

A high-end suspicion for concomitant TB and HD is needed, especially in our country where TB is still rampant. The difficulty in differentiating the two can sometimes cause delay in the diagnosis and hence the treatment. Biopsy with immunohistochemistry and demonstration of AFB can enable a definite diagnosis in difficult cases.

Funding

Nil.

Conflict of Interest

None declared.

Acknowledgments

The authors would like to thank Dr. L. Appaji and Dr. Aruna Kumari BS for their general support.

References

- Centkowski P, Sawczuk-Chabin J, Prochorec M, Warzocha K. Hodgkin's lymphoma and tuberculosis coexistence in cervical lymph nodes. *Leuk Lymphoma* 2005;46(3):471-475

- Badyal RK, Sharma P, Prakash G, Malhotra P, Varma N. Hodgkin lymphoma masquerading as tuberculosis in a young chronic smoker. *Indian J Hematol Blood Transfus* 2014;30, (Suppl 1):428-432
- John TJ. Tuberculosis control: detect and treat infection in children. *Indian Pediatr* 2008;45(4):261-264
- Kabra SK, Lodha R, Seth V. Some current concepts on childhood tuberculosis. *Indian J Med Res* 2004;120(4):387-397
- Nachman JB, Sposto R, Herzog P, et al; Children's Cancer Group. Randomized comparison of low-dose involved-field radiotherapy and no radiotherapy for children with Hodgkin's disease who achieve a complete response to chemotherapy. *J Clin Oncol* 2002;20(18):3765-3771
- World Health Organization; WHO Multicentre Growth Reference Study Group. *Who Child Growth Standards: Length/Height-for-Age, Weight-for-Age, Weight-for-Length, Weight-for-Height and Body Mass Index-for-Age: Methods and Development*. Geneva, Switzerland: World Health Organization; 2006. Available at: <http://www.who.int/childgrowth/standards/en/>. Accessed November 19, 2020
- Pileri SA, Ascani S, Leoncini L, et al. Hodgkin's lymphoma: the pathologist's viewpoint. *J Clin Pathol* 2002;55(3):162-176
- Lister TA, Crowther D, Sutcliffe SB, et al. Report of a committee convened to discuss the evaluation and staging of patients with Hodgkin's disease: Cotswolds meeting. *J Clin Oncol* 1989;7(11):1630-1636
- Cheson BD, Horning SJ, Coiffier B, et al; NCI Sponsored International Working Group. Report of an international workshop to standardize response criteria for non-Hodgkin's lymphomas. *J Clin Oncol* 1999;17(4):1244
- Revised National Tuberculosis Control Programme (RNTCP) – Guidelines for TB Control in India. Available at: http://www.searo.who.int/india/tuberculosis/topic/tb_rntcpguidelines/en/. Accessed November 19, 2020
- Pandey VK, Aggarwal P, Kakkar R, Modified BG. Prasad's Socio-economic Classification-2018: The need of an update in the present scenario. *Indian J Community Health* 2018;30:82-84
- Dannenbergh AM Jr. Delayed-type hypersensitivity and cell-mediated immunity in the pathogenesis of tuberculosis. *Immunol Today* 1991;12(7):228-233
- Starke JR, Smith MH. Tuberculosis. In: Feigin RD, Cherry JD, eds. *Textbook of Pediatric Infectious Diseases*. 4th ed. Philadelphia: WB Saunders Company; 1998 1196-239
- Sandherr M, von Schilling C, Link T, et al. Pitfalls in imaging Hodgkin's disease with computed tomography and positron emission tomography using fluorine-18-fluorodeoxyglucose. *Ann Oncol* 2001;12(5):719-722
- Johnson LN, Iseri O, Knodell RG. Caseating hepatic granulomas in Hodgkin's lymphoma. *Gastroenterology* 1990; 99(6):1837-1840
- Radhakrishnan V, Dhanushkodi M, Ganesan TS, et al. Pediatric Hodgkin lymphoma treated at cancer institute, Chennai, India: Long-term outcome. *J Glob Oncol* 2016;3(5):545-554
- Karakas Z, Agaoglu L, Taravari B, et al. Pulmonary tuberculosis in children with Hodgkin's lymphoma. *Hematol J* 2003;4(1):78-81
- Dres M, Demoule A, Schmidt M, Similowski T. Tuberculosis hiding a non-Hodgkin lymphoma "there may be more to this than meets the eye". *Respir Med Case Rep* 2012;7:15-16
- Codrich D, Monai M, Pelizzo G, et al. Primary pulmonary Hodgkin's disease and tuberculosis in an 11-year-old boy: case report and review of the literature. *Pediatr Pulmonol* 2006;41(7):694-698
- Tavani A, La Vecchia C, Franceschi S, Serraino D, Carbone A. Medical history and risk of Hodgkin's and non-Hodgkin's lymphomas. *Eur J Cancer Prev* 2000;9(1):59-64