

Giant abdominal aortic aneurysms

Joshua I. Ng, BSE, Tuong Nguyen, MD, Anand Tarpara, MD, Dawn Salvatore, MD, FACS, Paul DiMuzio, MD, FACS, and Babak Abai, MD, FACS, Philadelphia, Pa

ABSTRACT

Giant abdominal aortic aneurysms (AAAs) are defined as AAAs >10 to 13 cm in the maximum transverse diameter. We have described a case of a patient who had presented for open repair of an 18-cm AAA and a review of reported cases of giant AAAs >10 cm in the maximum transverse diameter. Forty cases were compiled. The average maximum AAA diameter was 14.5 ± 4.1 cm. The AAA was ruptured on presentation in 12 patients (30%). Of the 40 cases, 34 (85%) were repaired with open surgery. The reported mortality was 15%. Despite the case complexity, five endovascular repairs were attempted. (J Vasc Surg Cases Innov Tech 2021;7:659-64.)

Keywords: Giant abdominal aortic aneurysm; Giant aneurysm; Abdominal aortic aneurysm; Open repair of abdominal aortic aneurysm; Endovascular repair of abdominal aortic aneurysm

Giant abdominal aortic aneurysms (AAAs) have a varied definition, including >10 cm,¹ 11 cm,² and 13 cm^{3,4} in diameter. Regardless of the diameter used for classification, AAAs of this caliber are rare, with previous studies reporting a prevalence of AAAs >8 cm of 0.03%.⁵ This low prevalence could have resulted from the current practice of close follow-up for AAAs >4 cm and prompt elective repair of AAAs >5.5 cm.⁶ Furthermore, the high annual rupture rates of 30% to 50% for AAAs >8 cm have limited the maximum diameter of AAAs found at presentation.⁷

When patients do present with giant AAAs, these AAAs pose unique challenges for repair. We aimed to elucidate the unique characteristics of giant AAAs and highlight the challenges in their management by presenting one case from our institution and to conducting a review of the reported data. We used the most inclusive definition of giant AAAs reported (ie, >10 cm).

A review of the medical records of a patient who had presented to our institution for repair of an 18-cm AAA was conducted. The demographic data, medical history, aneurysm characteristics, and perioperative course were recorded. The available preoperative imaging studies and intraoperative video were also reviewed.

A search for reported cases was performed using the terms "giant" or "massive" and "abdominal aortic

aneurysm." Only studies detailing the repair of AAAs meeting our definition of a giant AAA of >10 cm in diameter were included, with 37 reports found. The references listed in the reviewed studies were also investigated. No limits were set on the publication date; the final list included studies reported from 1988 to 2020. The cases from our review and the case at our institution yielded a total of 40 unique patients (Table I). The patient demographics, including age, gender, and comorbidities, were recorded. The AAA characteristics, including size, location, acuity, presenting symptoms, chosen intervention, and postoperative course, were also recorded.

CASE REPORT

A 68-year-old man with a medical history of alcohol use disorder and 70 pack-year smoking history was transferred from an outside hospital for management of an incidentally discovered giant AAA. He had been brought to the outside hospital after being found down at home owing to alcohol intoxication. On presentation, the patient's vital signs were as follows: blood pressure, 106/81 mm Hg; heart rate, 80 bpm; respiratory rate, 22 breaths per minute; and oxygen saturation on room air, 99%. On a review of the systems, he reported an abdominal mass that had been increasing in size for several years without any associated abdominal or back pain. Despite the enlarging abdominal mass, he had not sought care and had undergone no previous workup for the AAA. The physical examination revealed a firm, pulsatile abdominal mass and a right inguinal hernia.

Computed tomography with intravenous contrast demonstrated a massive, fusiform aneurysm of the abdominal aorta measuring 18 cm in the transverse diameter beginning at the level of the renal arteries and extending to the aortic bifurcation (Fig 1). In addition, a 90° angulation was present at the level of the renal arteries. No retroperitoneal collection was observed to suggest aneurysm rupture had occurred. Additionally, the right iliac artery was occluded.

The patient was brought to the operating room for open AAA repair (Fig 2) with a rifampin-soaked, bifurcated, 24-mm × 12-mm Dacron graft (Maquet Cardiovascular, Wayne, NJ). The graft

From the Division of Vascular and Endovascular Surgery, Thomas Jefferson University Hospital.

Author conflict of interest: none.

Correspondence: Babak Abai, MD, FACS, Division of Vascular and Endovascular Surgery, Thomas Jefferson University Hospital, 111 South 11th St, Gibbon Bldg, Ste 6270, Philadelphia, PA 19107 (e-mail: babak.abai@jefferson.edu).

The editors and reviewers of this article have no relevant financial relationships to disclose per the Journal policy that requires reviewers to decline review of any manuscript for which they may have a conflict of interest.

2468-4287

© 2021 The Authors. Published by Elsevier Inc. on behalf of Society for Vascular Surgery. This is an open access article under the CC BY-NC-ND license (<http://creativecommons.org/licenses/by-nc-nd/4.0/>).

<https://doi.org/10.1016/j.jvscit.2021.04.016>

Table I. Compiled AAA cases

Size, cm	Age, years	Gender	Type	Acuity	Intervention	Outcome	Ref
10	65	Male	Juxtarenal	Intact	Open	Rehab, POD 6	13
10	65	Male	Infrarenal	Ruptured	Open	Home, POD 58	14
10	69	Male	Juxtarenal	Intact	Open	Home, POD 12	27
10	71	Male	Infrarenal	Intact	Open	Home, POD 10	28
10	79	Male	NR	Ruptured	Open	Death in OR	24
10	82	Male	NR	Intact	EVAR	Home, POD 5	29
10	82	Male	Infrarenal	Intact	Open	Death, POD 4	15
10	83	Female	Infrarenal	Intact	Open	Home, NR	17
10.1	77	Male	Pararenal	Intact	EVAR	Home, POD 14	30
10.3	84	Male	Infrarenal	Intact	EVAR	Home, POD 27	18
11	33	Male	Infrarenal	Ruptured	Open	Home, POD 14	9
11	73	Male	Crawford IV	Intact	Open	Home, POD 15	27
11	88	Male	Infrarenal	Intact	Open	Home, NR	31
12	74	Male	Pararenal	Intact	Open	Home, POD 7	32
13	31	Male	Suprarenal	Intact	Open	Home, NR	33
13	76	Male	Infrarenal	Ruptured	Open	Home, POD 10	34
13.2	80	Male	Infrarenal	Intact	EVAR to open	SNF, POD 26	3
13.5	75	Male	Infrarenal	Ruptured	Open	Home, NR	35
13.5	79	Female	Juxtarenal	Intact	Open	Home, POD 9	3
14	70	Male	Juxtarenal	Intact	Open	Home, POD 3	36
14	73	Male	Infrarenal	Intact	Open	NR	22
14.7	35	Male	Juxtarenal	Intact	Open	Home, POD 5	8
14.8	71	Male	Infrarenal	Ruptured	Open	SNF, POD 11	3
15	69	Female	Infrarenal	Intact	Open	NR	37
15	74	Male	Infrarenal	Intact	Open	Home, POD 15	38
15	76	Male	Infrarenal	Intact	Open	Home, POD 19	12
15	89	Male	Infrarenal	Intact	Open	Home, POD 8	39
15	90	Female	NR	Intact	Nonoperative	Death, NR	20
15	110	Male	Infrarenal	Ruptured	Open	Home, POD 12	40
15.5	71	Male	Juxtarenal	Intact	Open	Home, POD 6	3
18	60	Male	Infrarenal	Intact	Open	Home, POD 6	2
18	68	Male	Pararenal	Intact	Open	Home, POD 5	
18	83	Male	Infrarenal	Ruptured	Open	Death, POD 2	25
18	83	Male	NR	Ruptured	Open	Home, POD 7	41
19.8	64	Male	Infrarenal	Ruptured	Open	Death, POD 21	23
20	34	Male	Infrarenal	Intact	Open	Home, POD 10	11
20.6	76	Male	Infrarenal	Ruptured	Open	Home, POD 8	4
22	66	Male	Infrarenal	Ruptured	Open	Home, POD 121	21
25	73	Female	Infrarenal	Intact	EVAR	Death, POD 8	1
25.6	79	Male	Infrarenal	Intact	Open	Home, POD 39	42

AAA, Abdominal aortic aneurysm; EVAR, endovascular aneurysm repair; NR, not reported; OR, operating room; POD, postoperative day; Ref, reference; Rehab, rehabilitation; SNF, skilled nursing facility.

was soaked in rifampin in accordance with our institutional guidelines and surgeon preference, despite the absence of concern for active infection. An open technique was selected owing to the short, angulated aortic neck that would have

complicated endovascular repair. The patient was placed in the right lateral decubitus position for a retroperitoneal approach through the eighth intercostal space. A retroperitoneal approach was preferred because of the improved exposure for possible

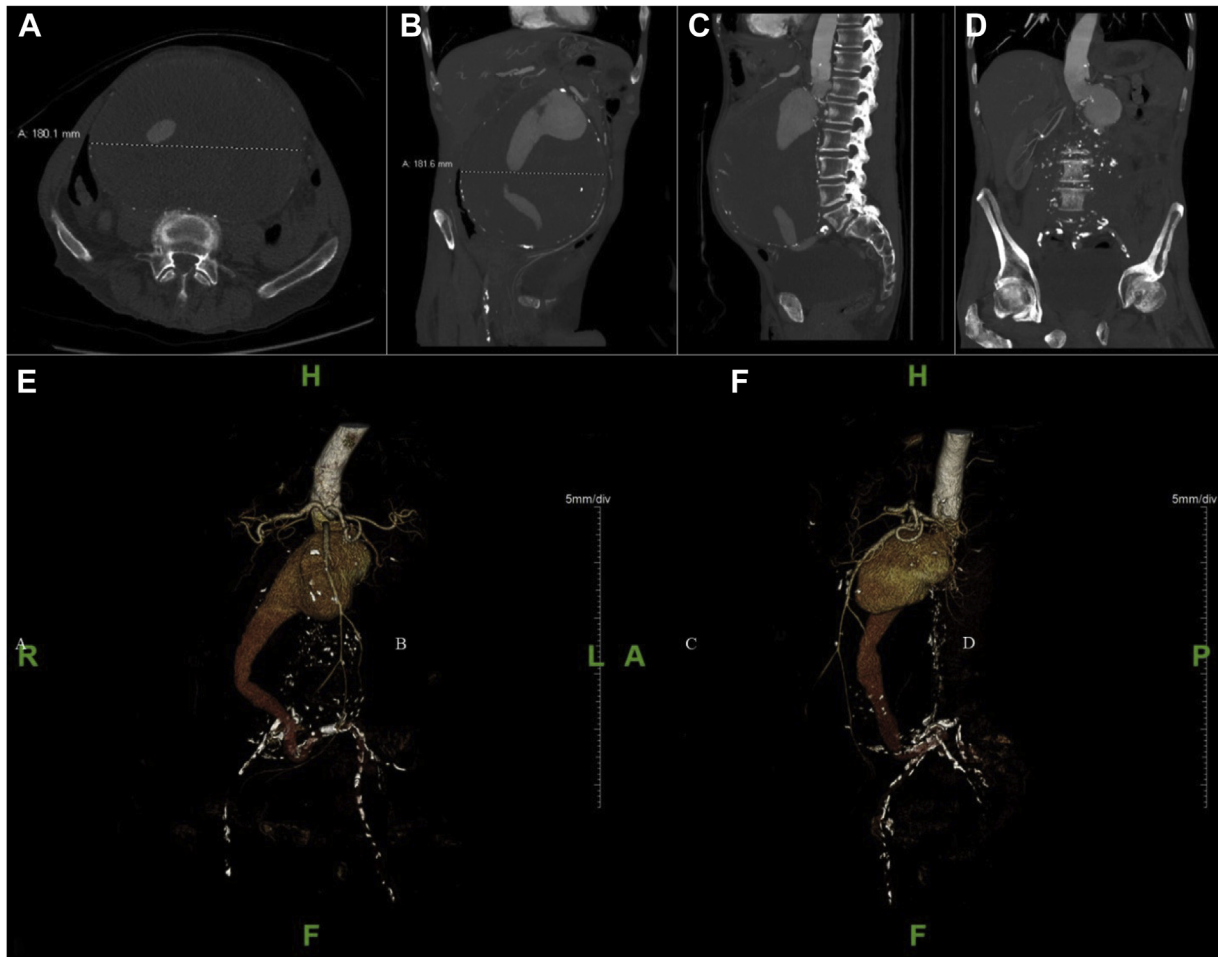


Fig 1. Preoperative computed tomography angiograms demonstrating an 18-cm abdominal aortic aneurysm (AAA) with severe neck angulation. **A**, Axial imaging study demonstrating a maximum diameter of 18 cm and large amount of intramural thrombus. **B**, Coronal imaging study demonstrating maximum diameter of 18 cm. **C**, Sagittal imaging study demonstrating aortic neck angulation. **D**, Coronal imaging study demonstrating aortic neck angulation. **E**, Anteroposterior view of preoperative computed tomography angiogram with three-dimensional reconstruction. **F**, Lateral view of preoperative computed tomography angiogram with three-dimensional reconstruction.

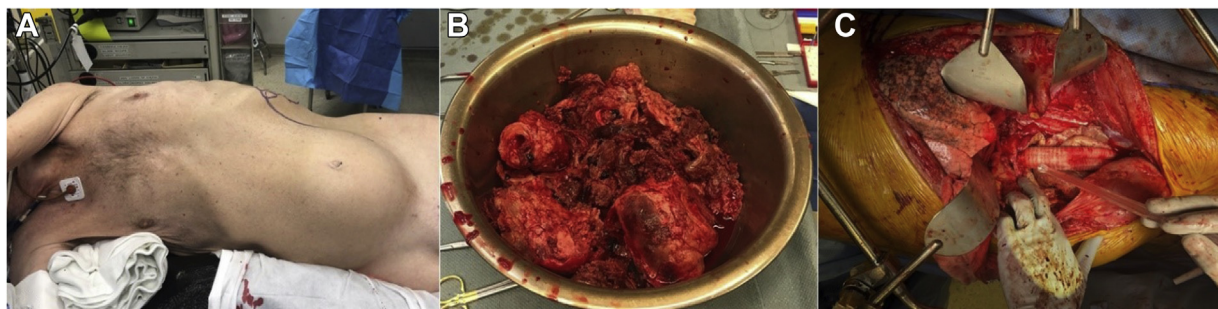

Fig 2. Intraoperative photographs. **A**, The patient was placed in the right lateral decubitus position. **B**, A large amount of intramural thrombus was evacuated. **C**, Final placement of aortic graft before closure of the aneurysmal sac around the graft.

suprarenal clamping. Proximal control was obtained by clamping above the superior mesenteric artery, below the celiac artery. Distal control was obtained at the left common iliac artery, because

the right common iliac artery was occluded on imaging. The estimated blood loss was 2.2 L, and the patient received 5 U of packed red blood cells, 5 U of fresh frozen plasma, and 2 U of

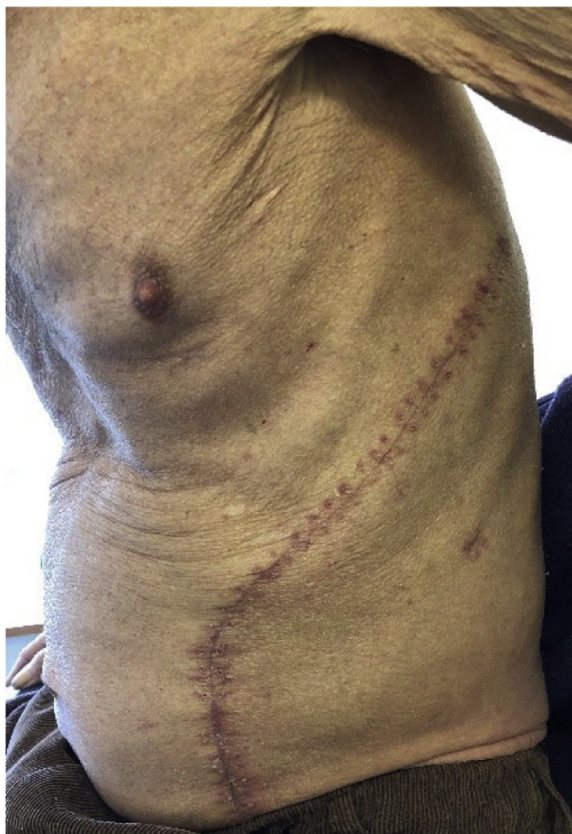

Fig 3. One-month postoperative image in outpatient clinic.

platelets. Endarterectomy of the right common iliac was also performed.

The patient recovered well postoperatively and was discharged 5 days after surgery. He was seen in the office at 10 days, 1 month, and 5 months after discharge and was doing well without any complications (Fig 3). The patient provided written informed consent for the report of his case.

DISCUSSION

The average age of the patients in our literature review was 72 ± 16 years, with an 87.5% male predominance (Table II). The common comorbid conditions included smoking (53.1%) and hypertension (50%). Coronary artery disease, myocardial infarction, cerebrovascular accident, and hyperlipidemia were recorded for fewer patients (Table II). These common comorbid conditions also matched the findings from other studies.^{5,6} Unique comorbid conditions included Takayasu arteritis,⁸ Marfan syndrome,⁹ Behçet disease,^{10,11} a Jehovah's witness requiring an autologous transfusion,¹² and ischemic cardiomyopathy requiring cardiopulmonary bypass during AAA repair.¹³ Complete data for the included cases are listed in the [Supplementary Table](#) (online only).

Abdominal pain (47.2%), back pain (36.1%), and nausea or vomiting (25%) were the most common presenting symptoms (Table III). Only 3 of the 40 patients (9.4%)

Table II. Summarized case demographics (n = 40)

Variable	Mean \pm SD or % (No.)
Age, years	72 \pm 16
Gender	
Male	87.5 (35)
Female	12.5 (5)
Comorbidity	
Smoking	53.1 (17)
HTN	50 (16)
CAD/MI	21.9 (7)
CVA	6.25 (2)
HLD	12.5 (4)
Previous AAA	9.4 (3)

AAA, Abdominal aortic aneurysm; CAD, coronary artery disease; CVA, cerebrovascular accident; HLD, hyperlipidemia; HTN, hypertension; MI, myocardial infarction; SD, standard deviation.

Table III. Summarized AAA characteristics and management

Variable	Mean \pm SD or % (No.)
Maximum diameter, cm	14.5 \pm 4.1
Ruptured	30 (12)
Presenting symptoms (36 reported)	
Abdominal pain	47.2 (17)
Back pain	36.1 (13)
Nausea and vomiting	25 (9)
AAA location (36 reported)	
Suprarenal	5.6 (2)
Pararenal	8.3 (3)
Juxtarenal	16.7 (6)
Infrarenal	69.4 (25)
Intervention	
Open surgery	85 (34)
EVAR	10 (4)
EVAR converted to open surgery	2.5 (1)
Nonoperative	2.5 (1)
Patients with complications	32.5 (13)
Average POD at discharge (of 28 reporting)	18.5 \pm 23.2 (1 outlier of 121 days)
Deaths (of 38 reporting outcomes)	15.8 (6; 4 open, 1 EVAR, 1 nonoperative)

AAA, Abdominal aortic aneurysm; EVAR, endovascular aneurysm repair; POD, postoperative day; SD, standard deviation.

had had a previously identified AAA. Finally, 30% of the AAAs were ruptured on presentation.

The average maximum giant AAA diameter was 14.5 ± 4.1 cm. Most of the giant AAAs were infrarenal (69.4%), followed by juxtarenal (16.7%), pararenal, and

suprarenal. Unique aneurysm characteristics included cases of aortoenteric fistula,¹⁴ duodenal obstruction,¹⁵⁻¹⁹ extrahepatic bile duct compression,²⁰ and vertebral erosion with associated lower extremity weakness.²¹

Open repair was the preferred intervention (85%). Only five endovascular aneurysm repairs (EVARs) were attempted, one of which was converted to open surgery owing to difficulty in advancing the guidewire. Four cases were reported before 1999.^{15,22-24} One patient refused surgical intervention and was treated nonoperatively. Complications were reported in 13 cases (32.5%) and included perigraft seroma,²⁵ ischemic colitis,^{13,26} acute respiratory distress syndrome,¹ and renal failure.³

The average time to discharge after intervention was 18.5 ± 23.2 days. Six deaths were reported, which included four open cases, one EVAR, and the one nonoperative patient. Of the deaths that occurred after open surgery, the causes included gastritis leading to perforation,¹⁵ myocardial infarction,²⁷ aortocaval fistula,²⁸ and acute respiratory distress syndrome.^{1,26} The death that occurred after EVAR was attributed to respiratory complications.¹

Our review of giant AAAs revealed epidemiologic trends consistent with the current understanding of AAA risk factors. However, many of the giant AAAs included in our study had not presented with rupture ($n = 28$), which was not consistent with studies reporting high rupture rates with an increasing aneurysm size. Furthermore, some of the patients had remained asymptomatic. Studies have postulated that certain factors, including peak wall stress, aneurysm symmetry, and intraluminal thrombus formation, are key predictors of aneurysm rupture.⁴ However, it was difficult to find these highly specific details in our review of the case reports, and it remains unclear why giant AAAs had reached a large caliber without rupture. Nevertheless, giant AAAs remain challenging operative entities, with unique anatomic considerations, including short and angulated aneurysm necks, adherence to abdominal organs, and fistula formation.²⁹ These challenges were reflected by the predominance of open procedures (85%; $n = 34$; Table III) compared with the use of EVAR (12.5%; $n = 5$). Despite the preference for open procedures, the three successful EVARs have demonstrated the efficacy of the endovascular technique for appropriately selected patients and provide an exciting outlook for the future of giant AAA repair.

REFERENCES

1. Yoshida RA, Yoshida WB, Kolvenbach R, Jaldin RC, Sobreira ML, Hirga M. Endovascular repair of a complex giant infrarenal abdominal aortic aneurysm. *Vascular* 2015;23:534-8.
2. Droz NM, Miner J, Pecchioni L. An 18-cm unruptured abdominal aortic aneurysm. *J Vasc Surg Cases Innov Tech* 2017;3:16-9.
3. Ullery BW, Itoga NK, Lee JT. Giant abdominal aortic aneurysms: a case series and review of the literature. *Vasc Endovascular Surg* 2015;49:242-6.
4. Duijzer C, Schuur TC, Wisselink W. Giant, 20 cm diameter, ruptured abdominal aortic aneurysm: a case report. *EJVES Short Rep* 2019;42:18-20.
5. Lederle FA, Johnson GR, Wilson SE, Chute EP, Hye RJ, Makaroun MS, et al. The aneurysm detection and management study screening program: validation cohort and final results. *Arch Intern Med* 2000;160:1425-30.
6. Chaikof EL, Dalman RL, Eskandari MK, Jackson BM, Lee WA, Mansour MA, et al. The Society for Vascular Surgery practice guidelines on the care of patients with an abdominal aortic aneurysm. *J Vasc Surg* 2018;67:2-77.e2.
7. Brewster DC, Cronenwett JL, Hallett JW, Johnston KW, Krupski WC, Matsumura JS. Guidelines for the treatment of abdominal aortic aneurysms: report of a subcommittee of the Joint Council of the American Association for Vascular Surgery and Society for Vascular Surgery. *J Vasc Surg* 2003;37:1106-17.
8. Kallappa Parameshwarappa S, Mandjiny N, Kavumkal Rajagopalan B, Radhakrishnan N, Samavedam S, Unnikrishnan M. Intact giant abdominal aortic aneurysm due to Takayasu arteritis. *Ann Vasc Surg* 2013;27:671.e11-4.
9. Zhang TH, Chi DC, Jiang WL, Qiang S. Marfan syndrome combined with huge abdominal aortic aneurysm size of 20 × 11 cm: a case report of surgical approach. *Medicine (Baltimore)* 2018;97:e09398.
10. Coşkun I, Demirtürk OS, Günday M, Tünel MG, Güvener M. Endovascular stent-grafting infection in active Behçet's disease concomitant with familial Mediterranean fever. *Turkish J Thorac Cardiovasc Surg* 2013;21:1097-101.
11. Desai SC, Gangadharan AN, Basavanthappa RP, Anagavalli Ramswamy C, Shetty R. Giant abdominal aortic aneurysm of uncommon etiology due to Behçet disease. *J Vasc Surg* 2019;70:937-40.
12. Bayam L, Tait WF, Macartney ID. Successful repair of a giant abdominal aortoiliac aneurysm in a Jehovah's witness. *Vasc Endovascular Surg* 2007;41:460-2.
13. Pocar M, Moneta A, Passolunghi D, Donatelli F. Femoro-axillary cardiopulmonary bypass for giant abdominal aortic aneurysm repair prior to staged cardiac operation for ischaemic cardiomyopathy. *Eur J Cardiothorac Surg* 2010;37:972-4.
14. Huang M, Piao H, Wang Y, Wang W, Wei S, Xie C, et al. Novel surgical treatment of abdominal aortic aneurysm complicated with primary aorto-colic fistula: a case report. *Medicine (Baltimore)* 2018;97:e11890.
15. Quigley FC, Faris IB, Jamieson GC. Duodenal obstruction as the presenting symptom of aortic aneurysm. *ANZ J Surg* 1988;58:909-11.
16. Renard R, Alsac JM. Duodenal obstruction by a giant aortic aneurysm: another cause of "aneurysm cachexia"? *Eur J Vasc Endovasc Surg* 2020;59:427.
17. Deitch JS, Heller JA, McGagh D, D'Ayala M, Kent KC, Plonk GW, et al. Abdominal aortic aneurysm causing duodenal obstruction: two case reports and review of the literature. *J Vasc Surg* 2004;40:543-7.
18. Newman J, Calley JL, Lim CS, Naji Y, Das S. Successful endovascular treatment of duodenal obstruction caused by large abdominal aortic aneurysm. *Ann Vasc Surg* 2015;29:1322.e1-4.
19. Redmond PL, Price GJ, Nolan DJ. Abdominal aortic aneurysm causing duodenal obstruction. *Clin Radiol* 1987;38:513-4.
20. Sakakura K, Takayashiki N, Tokuda Y, Satoh H. Biliary tract compression caused by a giant abdominal aneurysm. *Intern Med* 2013;52:925.
21. Figueroa CB, Molinos AD, de la Torre Scherak O, Castillo ÁL, Moy Petersen JC, Farraís Expósito FJ, et al. Lower extremity weakness as the first sign of an abdominal aortic aneurysm. *J Vasc Surg Cases Innov Tech* 2020;6:221-3.
22. Baumgartner F, Omari B, Donayre C. Suprarenal abdominal aortic dissection with retrograde formation of a massive descending thoracic aneurysm. *J Vasc Surg* 1998;27:180-2.
23. Schubert F. Giant aneurysm of the abdominal aorta. *Australas Radiol* 1995;39:58-60.
24. Shafei H, Attar A, Al-Ebrahim K. Ruptured large abdominal aortic aneurysm in a centenarian: a case report with a favorable outcome. *Vasc Endovascular Surg* 1994;28:437-40.

25. Kat E, Jones DN, Burnett J, Foreman R, Chok R, Sage MR. Perigraft seroma of open aortic reconstruction. *AJR Am J Roentgenol* 2002;178:1462-4.
26. Aurelian SV, Adrian M, Dan B, Bruno S, Alexandru O, Catalin T, et al. Giant infrarenal aortic aneurysm rupture preceded by left lower limb motor deficit. *Ann Vasc Surg* 2017;43:317.e11-4.
27. Clancy K, Wong J, Spicher A. Abdominal aortic aneurysm: a case report and literature review. *Perm J* 2019;23:18-218.
28. Nessi F, Ferrero E, Gaggiano A. Rupture of a giant aneurysm in the sub-renal abdominal aorta with aortocaval fistulae. *Minerva Chir* 2008;63:255.
29. Maras D, Lioupis C, Moulakakis KG, Sfyroeras C, Pavlidis P, Bountouris I, et al. Giant abdominal aortic aneurysms: clinical and technical considerations. *Acta Chir Belg* 2009;109:376-80.

Submitted Jan 12, 2021; accepted Apr 23, 2021.

Additional material for this article may be found online at www.jvascsurg.org.