

## MINI-FOCUS ISSUE: ARRHYTHMIAS AND EP

INTERMEDIATE

## TECHNICAL CORNER: CLINICAL CASE

# Direct Current Ablation of Deep Substrate Arrhythmia

Ying Chi Yang, MD,<sup>a</sup> Thein Tun Aung, MD,<sup>b</sup> Steven J. Bailin, MD,<sup>b</sup> Steven R. Mickelsen, MD<sup>b</sup>

## ABSTRACT

Direct-current ablation has been reinvestigated in animal models with considerably good outcomes and safety margins. Its modified version using biphasic energy lowers the current density further, minimizing its complications. We report a first-in-human ablation of ventricular tachycardia using biphasic direct current with short-term success and no procedural complications. (**Level of Difficulty: Intermediate.**) (J Am Coll Cardiol Case Rep 2020;2:1762-5)  
© 2020 The Authors. Published by Elsevier on behalf of the American College of Cardiology Foundation.  
This is an open access article under the CC BY-NC-ND license (<http://creativecommons.org/licenses/by-nc-nd/4.0/>).

## HISTORY OF PRESENTATION

A 61-year-old male was admitted for recurrent ventricular tachycardia (VT). The patient had a medical history of nonischemic cardiomyopathy status post-biventricular cardioverter-defibrillator implantation and VT, which was refractory to multiple antiarrhythmic drug therapy, and 4 prior attempts at radiofrequency (RF) ablation and cardiac

sympathetic denervation. He had undergone his last RF ablation 8 months earlier and cardiac sympathetic denervation 3 months previously. The patient was taking the maximum doses of mexiletine and metoprolol.

## DIFFERENTIAL DIAGNOSIS

Diagnosis was consistent with recurrent VT based on an arrhythmia log from his implanted cardioverter-defibrillator.

## LEARNING OBJECTIVES

- The effectiveness of radiofrequency ablation drops exponentially with distance, limiting the ablation of deep substrate arrhythmia.
- Direct-current ablation has been reinvestigated in animal models and has shown considerably good outcomes and safety margins with better lesion depths.
- Modified version of direct-current ablation using biphasic energy lowers the current density to further minimize its complications.

## INVESTIGATION

He underwent an electrophysiology study, results of which were consistent with clinical VT.

## MANAGEMENT

With the refractory VT, the patient underwent an unconventional procedure: electroporation or direct-current (DC) ablation. The 3-dimensional (3D) electroanatomical mapping showed deep septal focus correlating with his clinical VT. Burst pacing from the quadripolar catheter inside the right ventricle

From the <sup>a</sup>Department of Internal Medicine, University of Iowa, Iowa City, Iowa; and the <sup>b</sup>Department of Cardiac Electrophysiology, University of Iowa, Iowa City, Iowa. The authors have reported that they have no relationships relevant to the contents of this paper to disclose.

The authors attest they are in compliance with human studies committees and animal welfare regulations of the authors' institutions and Food and Drug Administration guidelines, including patient consent where appropriate. For more information, visit the *JACC: Case Reports* [author instructions page](#).

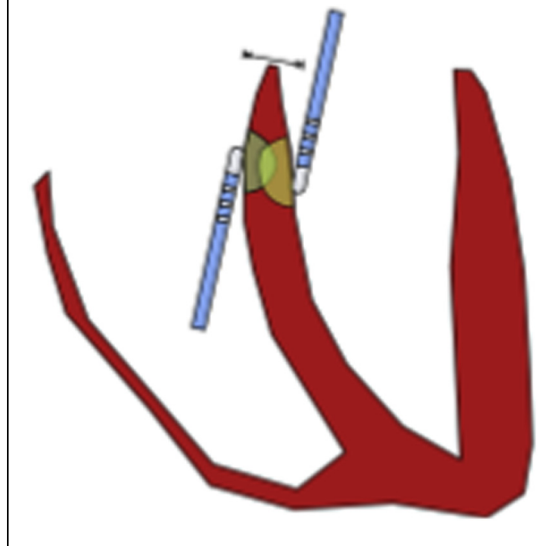
Manuscript received April 27, 2020; revised manuscript received June 5, 2020, accepted June 23, 2020.

**FIGURE 1** A Modified Cable Adapter



Standard outlet cords of a biphasic defibrillator (**blue and white**) were manually wired to 2 proprietary cables (**black**), and the latter cables were connected to each standard ablation catheter in bipolar fashion.

**FIGURE 2** Ablation Catheters, Ventricular Septum, and Hypothetical Ablation Zones



induced unsustained VT. Both the left and right ventricles were mapped using the Rhythmia mapping system (Boston Scientific, Cambridge, Massachusetts) and Intellimap Orion mapping catheter (Boston Scientific). The earliest activation was noted at the septal wall of the right ventricular outflow tract (RVOT) just below the pulmonary valve. On the left side, the high septum of the left ventricle just below the aortic valve was the earliest activation site. Pace mapping was also performed, and the paced morphology was 96% matched to the clinical VT.

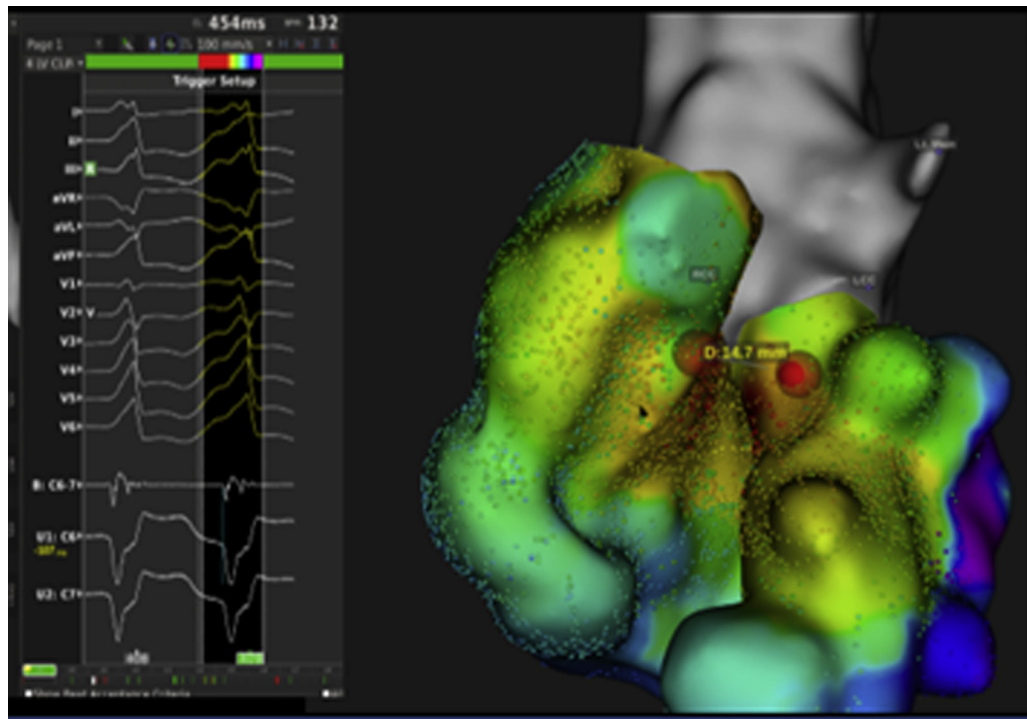
Two Intellanav MIFI (Boston Scientific) open-irrigated RF ablation catheters were connected to a standard biphasic defibrillator through the modified cable adapter (**Figure 1**). One of the catheters was placed on the RVOT septal wall just beneath the pulmonary valve, and the other was placed on the left ventricular outflow tract (LVOT) septal wall just below the aortic valve. The catheter tips were positioned 1.5 cm apart from each other to create a vector across the VT target (**Figures 2 and 3**). The catheter positions were confirmed by using 3D mapping, fluoroscopy, and intracardiac echocardiography (**Figure 4**).

DC ablation was initiated at 70 J, which was discharged simultaneously from both catheters in synchrony with the R-wave. The patient went into temporary atrial flutter and then spontaneously converted to normal sinus rhythm. Repeated mapping showed persistence of voltage and

electrograms in the ablated region. Three more DC ablations with synchronized biphasic energy of 100 J were applied to the same location. The final map then showed a different activation pattern with lower voltage in RVOT toward the pulmonic valve (**Figure 5**). Aggressive pacing with up to triple extra stimuli did not reproduce VT. The patient was discharged the next day with no immediate complications.

## DISCUSSION

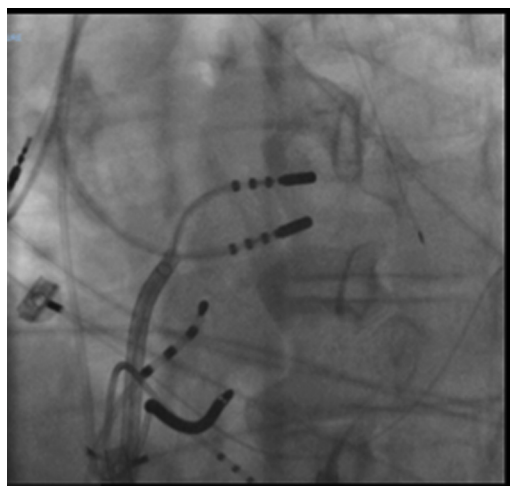
The technique of cardiac ablation using direct electric current was developed in the 1980s to ablate the atrioventricular node for the treatment of refractory supraventricular arrhythmia (1). The average amount of energy used was extremely high. In a study of 49 patients who received DC ablation, the average of amount of energy required for successful ablation was  $661 \pm 360$  J, and atrioventricular block was achieved with a success rate of 89.5% in 42 of 49 patients. However, an extremely high amount of energy and lack of arc control resulted in numerous complications such as myocardial stunning, catheter tip gas explosion with embolic complications, and adjacent tissues injuries (2). According to data from the Percutaneous Cardiac Mapping and Ablation Registry published in 1988, there were 8 cases of sudden death among a total of 480 patients (1.8%) who underwent the procedure, and most of them died within

**FIGURE 3** Surface Electrogram of Ventricular Tachycardia Morphology

Activation maps of the right ventricular outflow tract and the left ventricular outflow tract are illustrated along with catheter tip positions (red balls).

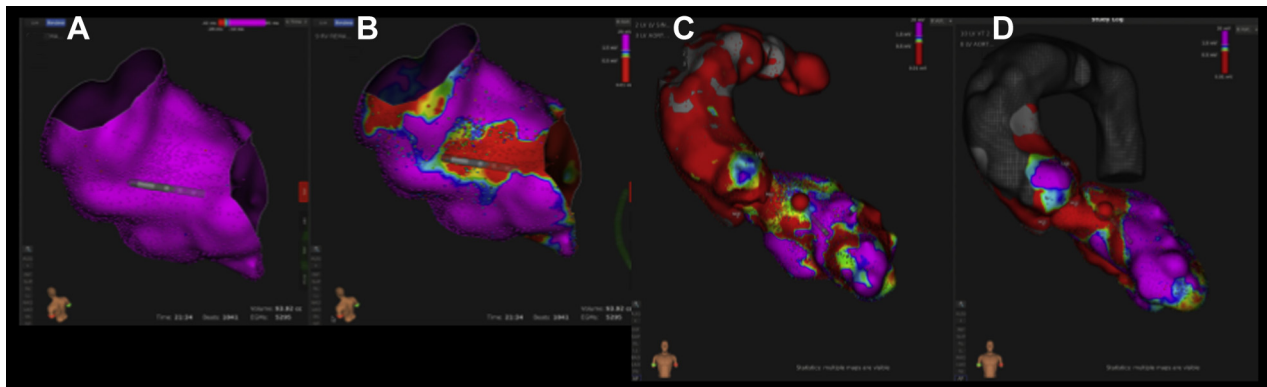
6 months post-procedure (3). Thus, DC ablation fell out of favor, especially with the subsequent development of RF ablation in the early 1990s (4). However, RF ablation carries its own limitations. It is less

effective for ablating deeper myocardial substrates and has complications such as “steam pop” from excessive thermal energy, cardiac perforation/tamponade, pulmonary vein stenosis, and adjacent coronary artery injury (5).

**FIGURE 4** Fluoroscopic Image of Catheter Positions

Recently, DC ablation has been reinvestigated as an alternative source of energy in cardiac ablation with the advancement in catheter technology where the catheter can deliver relatively low energy as well as low current density without creating an arc (6). The mechanism of DC ablation is disruption of cell membranes using electrical energy, resulting in apoptosis (7). An animal study showed 100- to 300-J-unipolar DC ablation resulted in larger and deeper lesions (8 to 10 mm) than standard RF ablation (4 to 5 mm) (8). Coronary luminal diameters were also unaffected by DC ablation in porcine models (9). Recently, Lavee et al. (10) proposed an ablation modality for atrial arrhythmia using biphasic DC in animal models. Unfortunately, there have been no data in humans about the efficacy and safety for VT. This study reports the first-in-human case of VT ablation using biphasic DC with short-term success and no procedural complications.

**FIGURE 5** Electroanatomic Mapping of Tissue Voltage



(A) Right ventricular outflow tract pre-ablation; (B) right ventricular outflow tract post-ablation; (C) left ventricular outflow tract pre-ablation; (D) left ventricular outflow tract post-ablation.

## FOLLOW-UP

The present patient had recurrent VT at 4 months following the procedure. He underwent a second DC ablation with short-term success. However, his VT returned 2 months later. No procedure-related complication have been reported at this writing during 1-year follow-up.

## CONCLUSIONS

With the advancement in catheter technology that allows the use of minimal current density and energy,

the current risk profile of DC ablation is significantly lower than its predecessors from the 1980s. DC ablation may be considered an alternative tool in electrophysiologists' armory for ablation of deep substrate arrhythmia, but further studies and longer follow-up examinations are warranted for its efficacy and safety.

**ADDRESS FOR CORRESPONDENCE:** Dr. Ying Chi Yang, Department of Internal Medicine, University of Iowa, 200 Hawkins Drive, Iowa City, Iowa 52242. E-mail: [myomintun3@gmail.com](mailto:myomintun3@gmail.com).

## REFERENCES

1. Gallagher JJ, Svenson RH, Kasell JH, et al. Catheter technique for closed-chest ablation of the atrioventricular conduction system. *N Engl J Med* 1982;306:194-200.
2. Rosenqvist M, Lee MA, Moulinier L, et al. Long-term follow-up of patients after transcatheter direct-current ablation of the atrioventricular junction. *J Am Coll Cardiol* 1990;16:1467-74.
3. Evans GT, Scheinman MM, Zipes DP, et al. The Percutaneous Cardiac Mapping and Ablation Registry: final summary of results. *Pacing Clin Electrophysiol* 1988;11:1621-6.
4. Morady F, Calkins H, Langberg JJ, et al. Prospective randomized comparison of direct-current and radiofrequency ablation of the atrioventricular junction. *J Am Coll Cardiol* 1993;21:102-9.
5. Taylor GW, Kay GN, Zheng X, Bishop S, Ideker RE. Pathological effects of extensive radiofrequency energy applications in the pulmonary veins in dogs. *Circulation* 2000;101:1736-42.
6. Barnett A, Bahnson T, Piccini J. Recent advances in lesion formation for catheter ablation of atrial fibrillation. *Circ Arrhythm Electrophysiol* 2016 May 9 [E-pub ahead of print].
7. Davalos RV, Mir IL, Rubinsky B. Tissue ablation with irreversible electroporation. *Ann Biomed Eng* 2005;33:223-31.
8. Huang SK, Graham AR, Lee MA, Ring ME, Gorman GD, Schiffman R. Comparison of catheter ablation using radiofrequency versus direct-current energy: biophysical, electrophysiologic and pathologic observations. *J Am Coll Cardiol* 1991;18:1091-7.
9. Neven K, Van Driel V, Van Wessel H, et al. Safety and feasibility of closed chest epicardial catheter ablation using electroporation. *Circ Arrhythm Electrophysiol* 2014;7:913-9.
10. Lavee J, Onik G, Mikus P, Rubinsky B. A novel nonthermal energy source for surgical epicardial atrial ablation: Irreversible electroporation. *Heart Surg Forum* 2007;10:E162-7.

**KEY WORDS** direct-current ablation, electrophysiology, ventricular arrhythmia