

Role of ^{18}F -fluorodeoxyglucose positron emission tomography/computed tomography in the evaluation of breast carcinoma: Indications and pitfalls with illustrative case examples

ABSTRACT

Whole-body ^{18}F -fluorodeoxyglucose positron emission tomography (PET) has been used extensively in the last decade for the primary staging and restaging and to assess response to therapy in these patients. We aim to discuss the diagnostic performance of PET/computed tomography in the initial staging of breast carcinoma including the locally advanced disease and to illustrate its role in restaging the disease and in the assessment of response to therapy, particularly after the neoadjuvant chemotherapy. Causes of common pitfalls during image interpretations will be also discussed.

Keywords: ^{18}F -fluorodeoxyglucose, breast carcinoma, positron emission tomography/computed tomography

INTRODUCTION

Locoregional staging with ^{18}F -fluorodeoxyglucose positron emission tomography

Breast cancer is the most common malignancy in women worldwide and is second only to lung cancer as a cause of cancer death. The incidence of breast cancer has increased steadily over the past few decades, but breast cancer mortality seems to be declining, suggesting a benefit from early detection and more effective treatment.^[1]

^{18}F -fluorodeoxyglucose (FDG) positron emission tomography (PET) is not used for primary breast cancer detection because of false-negative findings, particularly in patients with tumor < 1 cm and low tumor grade.^[2]

Dedicated breast positron emission mammography (PEM) units have been developed to overcome such limitations of whole-body PET. Owing to its improved count sensitivity, higher spatial resolution, shorter acquisition time, and reduced attenuation, this system can detect smaller lesions < 10 mm.^[3]

Pritchard *et al.*^[4] conducted a prospective, four-center study of 325 patients in Ontario with Stages I and II breast cancer and clinically negative axilla, who underwent ^{18}F -FDG PET and PET/computed tomography (CT) for axillary nodal staging. Not surprisingly, they had 100% specificity with only 24% sensitivity.

As far as the detection, in 13 patients who were suspected of having distant metastases by ^{18}F -FDG

MOHEIELDIN M. ABOUZIED, AHMED FATHALA, AHMAD ALMUHAIDEB, MOHAMMED H AL QAHTANI¹

Departments of Radiology and ¹Cyclotron and Radiopharmaceuticals, King Faisal Specialist Hospital and Research Centre, Riyadh, Saudi Arabia


Address for correspondence: Dr. Moheieldin M. Abouzied, Department of Radiology, King Faisal Specialist Hospital and Research Centre, Riyadh, Saudi Arabia.
E-mail: mohei.abouzied@gmail.com

Submission: 01-Dec-19, **Revised:** 15-Feb-20, **Accepted:** 02-Mar-20, **Published:** 01-Jul-20

This is an open access journal, and articles are distributed under the terms of the Creative Commons Attribution-NonCommercial-ShareAlike 4.0 License, which allows others to remix, tweak, and build upon the work non-commercially, as long as appropriate credit is given and the new creations are licensed under the identical terms.

For reprints contact: WKHLRPMedknow_reprints@wolterskluwer.com

How to cite this article: Abouzied MM, Fathala A, AlMuhaideb A, Al Qahtani MH. Role of ^{18}F -fluorodeoxyglucose positron emission tomography/computed tomography in the evaluation of breast carcinoma: Indications and pitfalls with illustrative case examples. World J Nucl Med 2020;19:187-96.

Access this article online	
Website: www.wjnm.org	Quick Response Code 
DOI: 10.4103/wjnm.WJNM_88_19	

PET, 10 had false-positive findings and only three were confirmed to have Stage IV disease by biopsy or clinical follow-up.

The study clearly confirms the limited sensitivity of ¹⁸F-FDG PET for axillary nodal metastases and limited yield for distant disease in early-stage breast cancer. Several others have also stated that ¹⁸F-FDG PET/CT has a low diagnostic yield for breast cancer patients with Stage I and early Stage II.^[5] Many of the findings are falsely positive,^[6] while on the other hand, in patients with large, Stage III tumors or inflammatory breast cancer; ¹⁸F-FDG PET detects occult metastases in a substantial proportion of patients (10%–21%) not found by CT and bone scan [Figure 1].^[7-9] The current National Comprehensive Cancer Network (NCCN) consensus guidelines stated that systemic staging, including ¹⁸F-FDG PET/CT, is not indicated for early-stage breast cancer in the absence of signs or symptoms suggesting metastasis.^[10]

There is currently no clinical role for routine ¹⁸F-FDG PET axillary staging in women with newly diagnosed early-stage breast cancer. A large prospective multicenter study evaluated 360 patients with newly diagnosed breast carcinoma aiming to evaluate its ability to stage the axilla with ¹⁸F-FDG PET before surgery. PET results were compared with those of pathologic analysis of axillary nodes. Overall, ¹⁸F-FDG PET was 61% sensitive and 80% specific for axillary metastases, with a positive predictive value of 62% and a negative predictive value of 79%. Receiver operating characteristic curve analysis demonstrated that ¹⁸F-FDG PET had high specificity for nodal disease when a threshold standardized uptake value (SUV) of 1.8 was used; however, this increased specificity reduced sensitivity for nodal

disease to 32%. On the basis of the results of their analysis, the authors concluded that “¹⁸F-FDG PET is not routinely recommended for axillary staging” in women with breast cancer.^[11]

However, in a subset of patients with locally advanced breast carcinoma (Stages III and IV disease) or inflammatory breast carcinoma, there is a high likelihood of axillary nodal metastases. Therefore, once confirmed with preoperative ¹⁸F-FDG PET, then ultrasound (US)-guided tissue biopsy of any abnormal-appearing nodes can establish the presence of axillary metastases. Patients might proceed directly to axillary dissection rather than sentinel lymph node biopsy. This approach has been supported by several authors [Figure 2].^[12,13]

Similarly, internal mammary nodal chain can be detected with ¹⁸F-FDG PET. Even though its clinical significance is uncertain, yet its detection might justify its inclusion within the radiation therapy port. In some authors’ experience, its detection particularly in locally advanced disease carries a worse prognosis [Figure 3].^[14]

SYSTEMIC RESTAGING OF RECURRENT DISEASE WITH ¹⁸F-FLUORODEOXYGLUCOSE POSITRON EMISSION TOMOGRAPHY

¹⁸F-FDG PET and ¹⁸F-FDG PET/CT can improve staging and alter therapeutic options in patients suspected to have breast cancer recurrence and distant metastatic disease, primarily by demonstrating local or distant metastases not detected by other imaging studies.^[15,16]

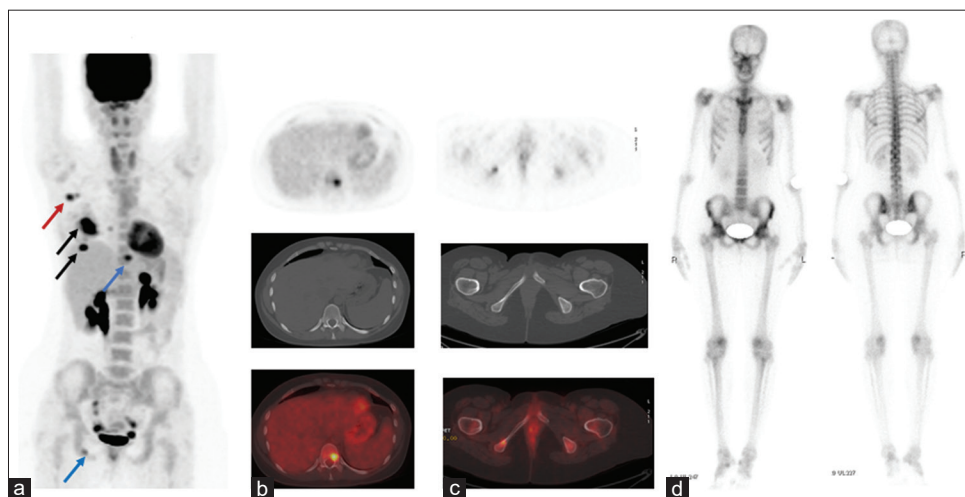


Figure 1: ¹⁸F-fluorodeoxyglucose maximum intensity projection image (a) demonstrates multifocal fluorodeoxyglucose-avid primary right breast carcinoma lesions (black arrows) with right axillary nodal metastases (red arrow) in addition to T-10 and right pubic bone metastases (blue arrow) shown in axial positron emission tomography, computed tomography, and fused positron emission tomography/computed tomography images and (b and c), bone scan (d) performed in the same week failed to identify the bone lesions

In a retrospective analysis of 233 scans carried out in 122 patients by a group from Royal Marsden hospital,^[17] PET/CT was used effectively for the clarification of indeterminate lesions on CT in 18 patients, on magnetic resonance imaging (MRI) in 15 patients, and on bone scan in 13 patients.

In patients with suspicious of recurrence, ¹⁸F-FDG PET can affect treatment decision in up to 44%.^[18] For example, local recurrence alone can be treated differently when compared to patients with local recurrence plus metastatic disease [Figure 4].

Accurate staging is particularly important in these patients because their treatment options may include surgery,

radiation, chemotherapy, and hormonal therapy, depending on the distribution and burden of their disease.

One of the more encountered problems in breast cancer patients is rising tumor markers in a symptomatic patient. In this clinical scenario, ¹⁸F-FDG PET allows more accurate diagnosis of metastatic disease compared with conventional imaging (CI).

Radan *et al.*^[18] showed in their study that ¹⁸F-FDG PET/CT was 90% sensitive for diagnosing recurrent tumor in patients with elevated levels of tumor markers and affected clinical management in 51% of the patients.^[20] In this study, ¹⁸F-FDG PET/CT demonstrated improved sensitivity, specificity, accuracy, and predictive value compared with CT alone.

Bone metastases is one of the most common sites for breast cancer metastases, accounting for 90% of all the metastatic sites that can appear as osteolytic, osteoblastic, mixed, or even intramedullary without obvious bone changes.^[19,20]

¹⁸F-FDG PET is superior to bone scintigraphy in detecting lytic and intramedullary metastases [Figure 5].

In many centers, bone scintigraphy and CT remains the standard imaging combination for staging breast cancer, and ¹⁸F-FDG PET/CT remained as a second resort to clarify difficult or equivocal cases.

Historically, ¹⁸F-FDG PET frequently failed to demonstrate plastic lesions, which are readily detected with bone scintigraphy. However, CT component of ¹⁸F-FDG PET/CT can now easily recognize the osteoplastic non-¹⁸F-FDG-avid lesions.^[21-23]

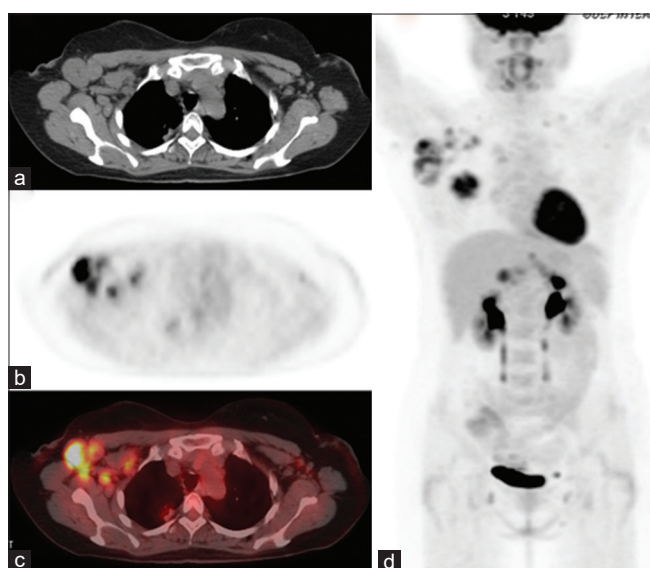


Figure 2: Axial computed tomography, positron emission tomography, fused positron emission tomography/computed tomography, and maximum intensity projection images (a-d) of a patient with locally advanced right breast carcinoma and nodal metastases involving the right axilla as well as the right subpectoral nodal metastatic lesions

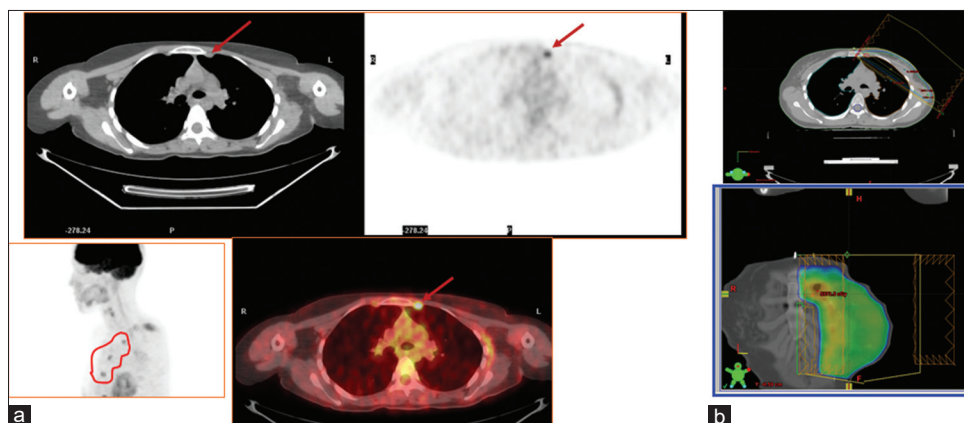


Figure 3: Axial computed tomography, positron emission tomography, positron emission tomography/computed tomography (a) of a left breast cancer with left internal mammary chain involvement (red arrows and circle) that required a subjective justification to widen the radiation field more medially to include the internal mammary chain in the radiation treatment volume (b)

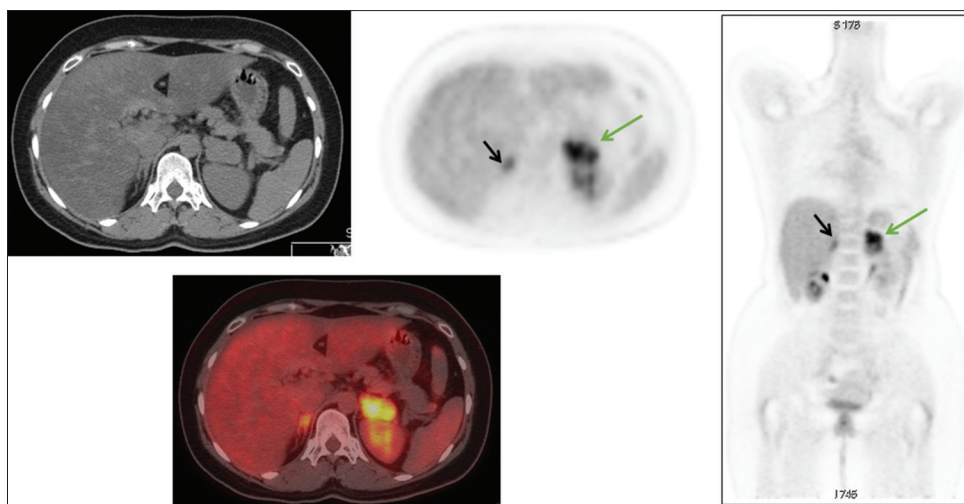


Figure 4: Axial computed tomography, positron emission tomography, positron emission tomography/computed tomography, and coronal positron emission tomography of a patient with biopsy-proven left adrenal metastases (green arrows) diagnosed 2 years post left modified radical mastectomy (MRM) and chemoradiotherapy. →There is also mild fluorodeoxyglucose uptake noted at the site of the normal-looking right adrenal gland (black arrows) that could be physiological

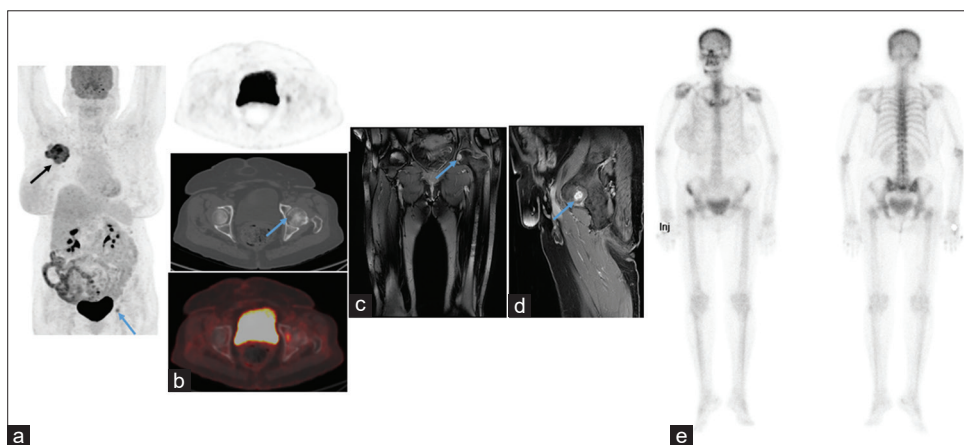


Figure 5 : ¹⁸F-fluorodeoxyglucose maximum intensity projection image (a) and axial positron emission tomography, computed tomography, and fused positron emission tomography/computed tomography images (b) demonstrating fluorodeoxyglucose-avid primary right breast carcinoma lesion (black arrows) with single-bone metastases (blue arrow) involving the head of the left femur that correspond to a lytic lesion on computed tomography bone window and an enhancing lesion on coronal (c) and sagittal T1 fast spin postcontrast images (d), bone scan (e) performed in the same week failed to identify the bone lesion

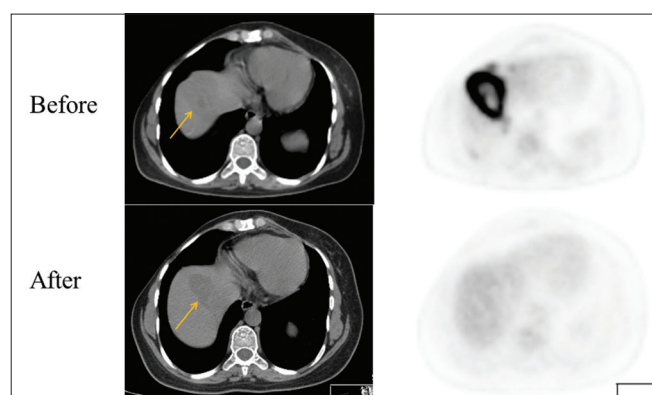


Figure 6: Axial CT, PET is showing single metastases involving the right lobe of the liver before and after chemotherapy, notice lacking of significant structural changes in the CT component of PET/CT (Yellow arrows), meantime the corresponding PET images is showing complete metabolic response

The use of ¹⁸F-FDG PET/CT as a single-staging examination is the subject of ongoing studies and has yet to be determined. We evaluated 77 consecutive PET-CT scans in 39 breast cancer patients with suspected local recurrence or distant metastases. All patients had an initial evaluation with enhanced CT of the chest, abdomen, and pelvis along with bone scan Conventional Modalities (CM) within maximum 2 weeks of low-dose nonenhanced PET/CT. Histology (*n* = 11) or follow-up clinically and radiologically (*n* = 28) for at least 6 months was employed as the standard of reference for imaging findings.

PET-CT was true negative in ten patients in excluding local recurrence and distant metastases without false-negative reading, with a sensitivity and negative predictive value of

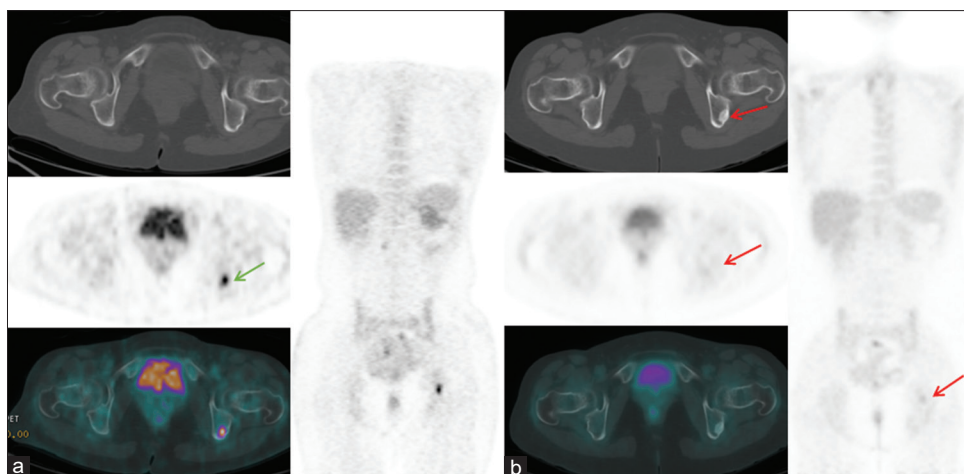


Figure 7: Axial computed tomography, positron emission tomography, positron emission tomography/computed tomography, and coronal positron emission tomography before (a) and after chemotherapy (b) showing an abnormal focal uptake in the left ischium (green arrow) that represents bone metastases is showing an marked interval decrease in the metabolic activity with the presence of osteoblastic changes (red arrows) suggestive of good response to therapy

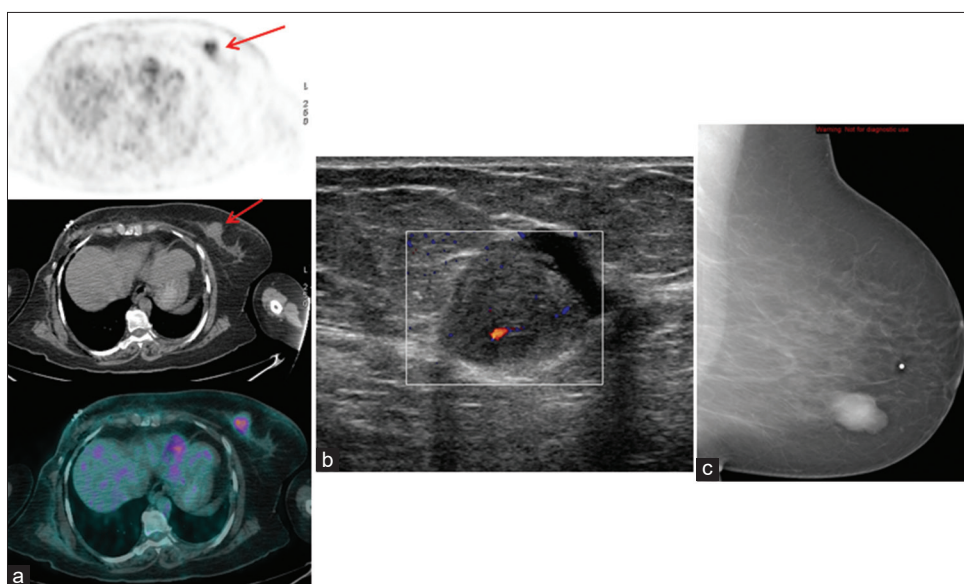


Figure 8: A 54-year-old female with a history of right breast carcinoma post modified radical mastectomy (MRM) restaging positron emission tomography/computed tomography (a) revealing left breast hypermetabolic lesion with maximum standardized uptake value of 7 (red arrows), ultrasound (b) revealing well-circumscribed hypoechoic lesion (2.5 cm x 2.0 cm), most of the lesion is solid with the exception of its anterior component, with increased vascularity on the color Doppler, Her mammogram revealed a well-circumscribed oval mass in the inner lower quadrant (c). Excisional biopsy revealed intraductal papilloma with florid ductal hyperplasia

100%. CM was also true negative in ten patients with two false-negative reading, with a sensitivity of 92% and a negative predictive value of 83%.

PET-CT was true positive in 26 and false positive in three patients, in whom the histopathological examination revealed granulomatous disease, with a specificity and a positive predictive value of 76.9% and 89%, respectively. CM was true positive in 24 and false positive in three patients, with a specificity and a positive predictive value of 76.9% and 88%, respectively. The overall accuracy for PET/CT and CM was 92% and 87%, respectively.

We concluded that hybrid ¹⁸F-FDG PET/CT outperformed CM in restaging breast cancer patients.^[22]

Therefore, ¹⁸F-FDG PET/CT has been recommended in the NCCN guidelines as an optional staging study for patients with locally advanced, inflammatory, and recurrent/metastatic breast cancer (MBC), especially when there are questions arising from standard staging studies.^[10]

MONITORING RESPONSE TO THERAPY WITH ¹⁸F-FLUORODEOXYGLUCOSE POSITRON EMISSION TOMOGRAPHY/COMPUTED TOMOGRAPHY

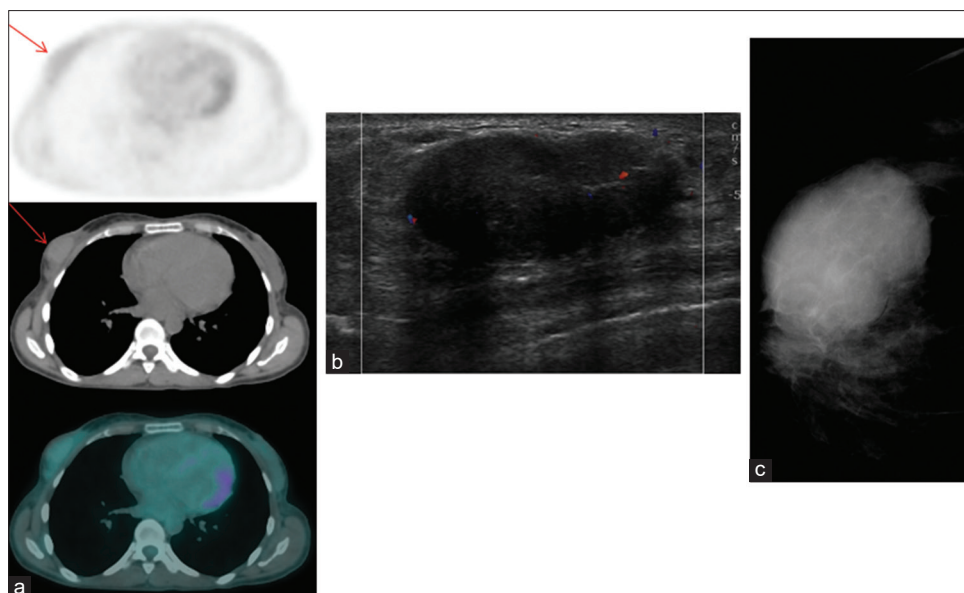


Figure 9: A 45-year-old female with a history of gastrointestinal stromal tumor; restaging positron emission tomography/computed tomography revealing mild hypermetabolic mass in the right breast (red arrows, a), ultrasound revealing a well-defined solid hypoechoic nodule (3.7 cm × 2 cm × 3.2 cm) with minimal vascularity (b) seen also on mammogram (c). → The patient mentioned that she had the mass for over 18 years suggestive of benign etiology/fibroadenoma

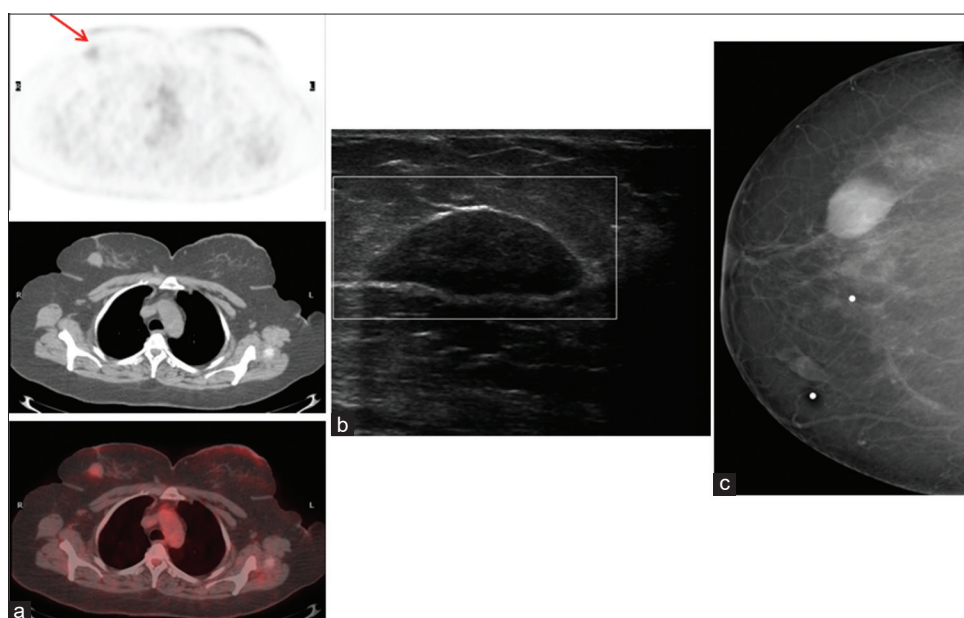


Figure 10: A 45-year-old female with a history of left breast carcinoma. Her staging positron emission tomography/computed tomography (a) revealing mild hypermetabolic mass in the right breast (red arrow), ultrasound (b) revealing a well-defined hypoechoic mass with pseudocapsule (2.7 cm × 1.1 cm × 2.5 cm) with no vascularity suggestive of benign etiology/fibroadenoma. Her mammogram (c) revealing a well-defined mass in the left upper quadrant suggestive of benign etiology

Neoadjuvant therapy response

Neoadjuvant (preoperative) systemic therapy has become the standard treatment for patients with locally advanced breast cancer.

It has an impact on improving surgical options by shrinking the size of the tumor and allowing less radical surgery, but has not been shown to improve survival.^[24]

Size-based approach to assess the tumor response by structural radiological modalities such as CT, MRI, and US cannot distinguish between pathological complete response from other types of responses.^[24] Changes in ¹⁸F-FDG metabolism often precede morphologic changes in tumor, and therefore functional imaging with ¹⁸F-FDG PET plays a major role in showing response sooner than CI techniques [Figure 6].

Most studies evaluating ¹⁸F-FDG PET to assess response to neoadjuvant therapy have measured change in ¹⁸F-FDG uptake at mid-therapy, compared with baseline, as a measure of response.

Early on, Wahl *et al.*^[25] followed by several other authors have shown significant quantitative differences in the ¹⁸F-FDG uptake measured before and after 2 months of therapy for responders versus nonresponders.

Several studies have suggested that ¹⁸F-FDG PET may serve as an early predictor of chemotherapy response and, most importantly, as an accurate predictor of lack of response.^[26-29]

Rousseau *et al.*^[30] found that, using a 60% decrease in baseline SUV as the threshold for response, ¹⁸F-FDG PET was 61%

sensitive and 96% specific after a single cycle, which increased to 89% sensitive and 95% specific after two cycles of therapy.

¹⁸F-FDG PET may miss small-volume residual disease after therapy, however, the presence or absence of ¹⁸F-FDG uptake may carry prognostic significance that may be important in directing the intensity of additional therapy and postsurgery surveillance.^[31]

Recurrent or metastatic disease response

Assessing the response to therapy in the clinical setting of metastatic disease is a challenging task for the conventional modalities. Even though complete cure is rare, often, these patients show response to therapy.

Cachin *et al.*^[32] evaluated the therapeutic response of MBC patients to high-dose chemotherapy and autologous stem cell transplantation. In their study, 47 patients with MBC were treated with a maximum of three cycles of HDC. The therapeutic response was assessed with CI and by ¹⁸F-FDG PET study performed after the last cycle of HDC.

Complete responses were observed in 16 patients (37%) with CI and 34 patients (72%) with ¹⁸F-FDG PET. The ¹⁸F-FDG PET result was the most powerful and independent predictor of survival; patients with a negative posttreatment ¹⁸F-FDG-PET had a longer median survival than patients with a positive ¹⁸F-FDG PET (24 months vs. 10 months; $P < 0.001$).

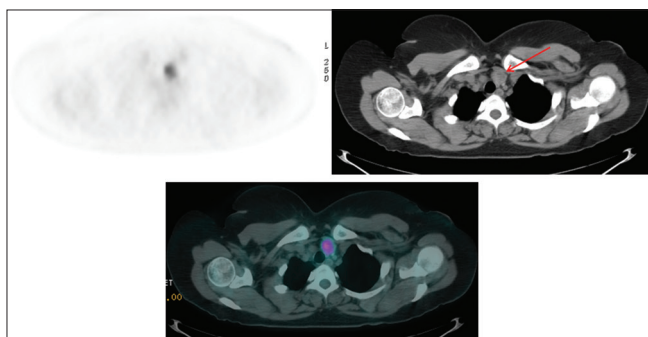


Figure 11: Axial positron emission tomography, computed tomography, and fused positron emission tomography/computed tomography is showing focal hypermetabolic thyroid nodule involving the left lobe (red arrow) in a newly diagnosed left breast carcinoma patient, and fine-needle aspiration guided by ultrasound revealing papillary thyroid carcinoma

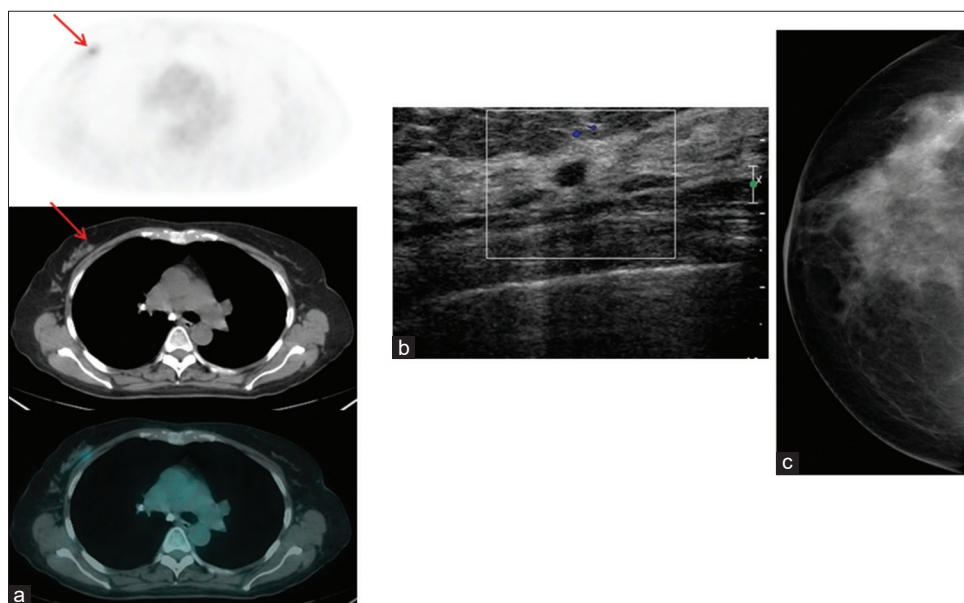


Figure 12: A 57-year-old female with a history of adenocarcinoma of the head of the pancreas. Staging ¹⁸F-fluorodeoxyglucose positron emission tomography/computed tomography (a) revealing hypermetabolic lesion in the right breast (red arrow). Ultrasound (b) revealing 0.5 cm x 0.4 cm hypoechoic lesion without increased vascularity. Her mammogram (c) was not conclusive. Biopsy revealed invasive duct carcinoma

Dose Schwarz *et al.*^[33] have evaluated the use of sequential ¹⁸F-FDG PET to predict response after the first and second cycles of standardized chemotherapy for MBC and have shown that response might be visible as early as after a single cycle of chemotherapy.

One particular problem in assessing response to therapy is bone metastases as none of the current modalities, bone scan, MRI, and CT, can accurately assess response to therapy in bone sites.

Bone scan with its known flare phenomenon can even be more confusing. Even though the majority of untreated bone metastases are positive on PET scans and have a lytic pattern on CT, after treatment, incongruent CT-positive/PET-negative lesions are significantly more prevalent and are generally osteoblastic, which presumably reflects a direct effect of treatment [Figure 7].^[34]

Recent studies have suggested that serial ¹⁸F-FDG PET can be helpful in measuring bone metastasis response and that changes in ¹⁸F-FDG uptake correlate with clinical response and changes in breast cancer tumor markers.^[35]

COMMONLY ENCOUNTERED PITFALLS

False-positive uptake

¹⁸F-FDG is not a tumor-specific probe. In addition to its physiologic accumulation in different organs, it can accumulate

in benign nonneoplastic pathologic conditions; including infection, whether acute or chronic infection such as abscess formation; tuberculosis; granulomatous diseases such as sarcoidosis; and autoimmune disease such as Grave's disease.^[36]

In addition, the ¹⁸F-FDG uptake can be enhanced by inflammatory-induced changes, which include postoperative healing scars and postradiation therapy. The degree of uptake is usually less than the uptake within the neoplastic tissues.^[36] However, there is clearly an overlap between the two conditions and in some cases, the uptake could even exceed the neoplastic uptake. Furthermore, the image interpreter should be aware of the accumulation of ¹⁸F-FDG to some extent in some benign tumors, such as fibro-adenoma, fibrocystic changes of the breast, atypical ductal dysplasia, duct ectasia, and phyllodes tumor [Figures 8-10].^[37]

False-negative uptake

There are many factors that can affect ¹⁸F-FDG avidity to breast cancer: small tumor size <1 cm and some less aggressive malignancies such as carcinoma *in situ*, lobular carcinoma, and tubular subtype of breast carcinoma;^[2] such lesions can be easily overlooked by ¹⁸F-FDG PET.

Detection of an unexpected primary cancer

The detection of unexpected malignancy could have a major clinical significance not only in breast cancer patients but also in any kind of malignant process staging.

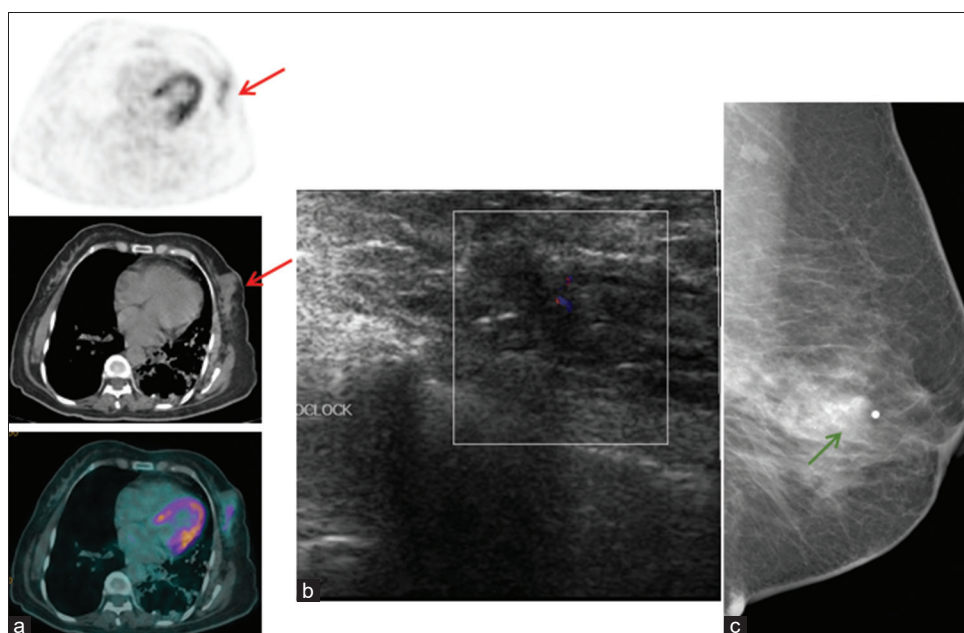


Figure 13: A 58-year-old female with a history of rectal carcinoma; positron emission tomography/computed tomography revealing mild hypermetabolic left breast lesion (red arrows, a), ultrasound (b) revealing a hypoechoic mass infiltrating posteriorly to the chest wall that correspond to a lower outer quadrant mass seen by mammogram (c) extending to retro-areolar region with amorphous calcification (green arrow). Tru-cut biopsy revealing papillary sclerosing duct papilloma; lumpectomy revealing 1-cm invasive ductal carcinoma with extensive intraductal carcinoma solid, cribriform, and micropapillary pattern

In one study, the prevalence of pathology-proved additional primary malignancies at PET/CT performed for known or suspected malignancies was 1.2%.^[38] Further diagnostic work-up would be needed in this clinical scenario as the patient's management is anticipated with the new diagnosis of second primary.

On the other hand, detection of unexpected focal hypermetabolic lesion in the breast parenchyma in patients who are undergoing PET/CT for reasons other than breast cancer staging may represent malignancy [Figures 11-13].

CONCLUSIONS

There has been growing evidence in literatures that ¹⁸F-FDG PET/CT is now playing a major role in the early staging of locally advanced and inflammatory breast carcinoma, restaging patients with clinical suspicious of recurrence and in the evaluation of response to therapy post either neoadjuvant chemotherapy or chemotherapy for metastatic breast carcinoma.

One must be familiar with PET/CT limitations such as its limited spatial resolution; an encountered problem in early stages of breast cancer that has been resolved by the new introduction of PEM.

More studies are needed to explore the potential benefits of new tracers other than ¹⁸F-FDG; for example, ¹⁸F-fluorestradiol to image estrogen receptor expression, ¹⁸F-Z (Her-2):342-Affibody to image epidermal growth factor expression (Her-2 neu), and ¹⁸F-Fluoride to specifically assess the bony skeletal structures.

Declaration of patient consent

The authors certify that they have obtained all appropriate patient consent forms. In the form the patient(s) has/have given his/her/their consent for his/her/their images and other clinical information to be reported in the journal. The patients understand that their names and initials will not be published and due efforts will be made to conceal their identity, but anonymity cannot be guaranteed.

Financial support and sponsorship

Nil.

Conflicts of interest

There are no conflicts of interest.

REFERENCES

- Jemal A, Siegel R, Xu J, Ward E. Cancer statistics, 2010. *CA Cancer J Clin* 2010;60:277-300.
- Kumar R, Chauhan A, Zhuang H, Chandra P, Schnall M, Alavi A. Clinicopathologic factors associated with false negative FDG-PET in primary breast cancer. *Breast Cancer Res Treat* 2006;98:267-74.
- Rosen EL, Turkington TG, Soo MS, Baker JA, Coleman RE. Detection of primary breast carcinoma with a dedicated, large-field-of-view FDG PET mammography device: Initial experience. *Radiology* 2005;234:527-34.
- Pritchard KI, Julian JA, Holloway CM, McCready D, Gulenchyn KY, George R, et al. Prospective study of 2-[¹⁸F] fluorodeoxyglucose positron emission tomography in the assessment of regional nodal spread of disease in patients with breast cancer: An Ontario clinical oncology group study. *J Clin Oncol* 2012;30:1274-9.
- Lovrics PJ, Chen V, Coates G, Cornacchi SD, Goldsmith CH, Law C, et al. A prospective evaluation of positron emission tomography scanning, sentinel lymph node biopsy, and standard axillary dissection for axillary staging in patients with early stage breast cancer. *Ann Surg Oncol* 2004;11:846-53.
- Norum J, Andreassen T. Screening for metastatic disease in newly diagnosed breast cancer patients. What is cost-effective? *Anticancer Res* 2000;20:2193-6.
- van der Hoeven JJ, Krak NC, Hoekstra OS, Comans EF, Boom RP, van Geldere D, et al. 18F-2-fluoro-2-deoxy-d-glucose positron emission tomography in staging of locally advanced breast cancer. *J Clin Oncol* 2004;22:1253-9.
- Carkaci S, Macapinlac HA, Cristofanilli M, Mawlawi O, Rohren E, Gonzalez Angulo AM, et al. Retrospective study of 18F-FDG PET/CT in the diagnosis of inflammatory breast cancer: Preliminary data. *J Nucl Med* 2009;50:231-8.
- Niikura N, Liu J, Costelloe CM, Palla SL, Madewell JE, Hayashi N, et al. Initial staging impact of fluorodeoxyglucose positron emission tomography/computed tomography in locally advanced breast cancer. *Oncologist* 2011;16:772-82.
- Carlson RW, Allred DC, Anderson BO, Burstein HJ, Carter WB, Edge SB, et al. Invasive breast cancer. *J Natl Compr Canc Netw* 2011;9:136-222.
- Wahl RL, Siegel BA, Coleman RE, Gatsonis CG, PET Study Group. Prospective multicenter study of axillary nodal staging by positron emission tomography in breast cancer: A report of the staging breast cancer with PET Study Group. *J Clin Oncol* 2004;22:277-85.
- Gil-Rendo A, Zornoza G, Garcia-Velloso MJ, Regueira FM, Beorlegui C, Cervera M. Fluorodeoxyglucose positron emission tomography with sentinel lymph node biopsy for evaluation of axillary involvement in breast cancer. *Br J Surg* 2006;93:707-12.
- Zornoza G, Garcia-Velloso MJ, Sola J, Regueira FM, Pina L, Beorlegui C. 18F-FDG PET complemented with sentinel lymph node biopsy in the detection of axillary involvement in breast cancer. *Eur J Surg Oncol* 2004;30:15-9.
- Bellon JR, Livingston RB, Eubank WB, Gralow JR, Ellis GK, Dunnwald LK, et al. Evaluation of the internal mammary lymph nodes by FDG-PET in locally advanced breast cancer (LABC). *Am J Clin Oncol* 2004;27:407-10.
- Rosen EL, Eubank WB, Mankoff DA. FDG PET, PET/CT, and breast cancer imaging. *Radiographics* 2007;27 Suppl 1:S215-29.
- Constantinidou A, Martin A, Sharma B, Johnston SR. Positron emission tomography/computed tomography in the management of recurrent/metastatic breast cancer: A large retrospective study from the Royal Marsden Hospital. *Ann Oncol* 2011;22:307-14.
- Eubank WB, Mankoff D, Bhattacharya M, Gralow J, Linden H, Ellis G, et al. Impact of FDG PET on defining the extent of disease and on the treatment of patients with recurrent or metastatic breast cancer. *AJR Am J Roentgenol* 2004;183:479-86.
- Radan L, Ben-Haim S, Bar-Shalom R, Guralnik L, Israel O. The role of FDG-PET/CT in suspected recurrence of breast cancer. *Cancer* 2006;107:2545-51.

1. Jemal A, Siegel R, Xu J, Ward E. Cancer statistics, 2010. *CA Cancer J Clin*

19. Abouzied M, Tuli M, Alsugair A, Alblushi N, Rifai A. Does bone scan add any incremental value to 18FDG PET/CT in restaging patients with breast carcinoma? *Radiology*; (Supp. 1), 302, November 2007.
20. Cook GJ, Houston S, Rubens R, Maisey MN, Fogelman I. Detection of bone metastases in breast cancer by ¹⁸F-FDG PET: Differing metabolic activity in osteoblastic and osteolytic lesions. *J Clin Oncol* 1998;16:3375-9.
21. Nakai T, Okuyama C, Kubota T, Yamada K, Ushijima Y, Taniike K, *et al.* Pitfalls of FDG-PET for the diagnosis of osteoblastic bone metastases in patients with breast cancer. *Eur J Nucl Med Mol Imaging* 2005;32:1253-8.
22. Algafri A, Al-Tweigeri T, Al-Sugair A, Al-Seabee M, Al-Alawi E, Fathala A, *et al.* The Diagnostic Accuracy of FDG PET Low Dose None Enhanced CT in the Detection of Local Recurrence and Distant Metastases during Follow-up of Breast Cancer Patients: A Comparison to Enhanced CT and Bone Scan. Vienna, Austria: The European Congress of Radiology; 2012.
23. Gralow JR, Zujewski JA, Winer E. Preoperative therapy in invasive breast cancer: Reviewing the state of the science and exploring new research directions. *J Clin Oncol* 2008;26:696-7.
24. Feldman LD, Hortobagyi GN, Buzdar AU, Ames FC, Blumenschein GR. Pathological assessment of response to induction chemotherapy in breast cancer. *Cancer Res* 1986;46:2578-81.
25. Wahl RL, Zasadny K, Helvie M, Hutchins GD, Weber B, Cody R. Metabolic monitoring of breast cancer chemohormonotherapy using positron emission tomography: Initial evaluation. *J Clin Oncol* 1993;11:2101-11.
26. Mankoff DA, Dunnwald LK. Changes in glucose metabolism and blood flow following chemotherapy for breast cancer. *PET Clin* 2006;1:71-81.
27. Schelling M, Avril N, Nühric J, Kuhn W, Römer W, Sattler D, *et al.* Positron emission tomography using [(18)F] Fluorodeoxyglucose for monitoring primary chemotherapy in breast cancer. *J Clin Oncol* 2000;18:1689-95.
28. Smith I, Welch AE, Hutcheon AW, Miller ID, Payne S, Chilcott F, *et al.* Positron emission tomography using [18F]-fluorodeoxy-d-glucose to predict the pathologic response of breast cancer to primary chemotherapy. *J Clin Oncol* 2000;18:1676-88.
29. Berriolo-Riedinger A, Touzery C, Riedinger JM, Toubeau M, Coudert B, Arnould L, *et al.* [18F]FDG-PET predicts complete pathological response of breast cancer to neoadjuvant chemotherapy. *Eur J Nucl Med Mol Imaging* 2007;34:1915-24.
30. Rousseau C, Devillers A, Sagan C, Ferrer L, Bridji B, Campion L, *et al.* Monitoring of early response to neoadjuvant chemotherapy in stage II and III breast cancer by [18F]fluorodeoxyglucose positron emission tomography. *J Clin Oncol* 2006;24:5366-72.
31. Kim SJ, Kim SK, Lee ES, Ro J, Kang S. Predictive value of [18F] FDG PET for pathological response of breast cancer to neo-adjuvant chemotherapy. *Ann Oncol* 2004;15:1352-7.
32. Cachin F, Prince HM, Hogg A, Ware RE, Hicks RJ. Powerful prognostic stratification by [18F]fluorodeoxyglucose positron emission tomography in patients with metastatic breast cancer treated with high-dose chemotherapy. *J Clin Oncol* 2006;24:3026-31.
33. Dose Schwarz J, Bader M, Jenicke L, Hemminger G, Jänicke F, Avril N. Early prediction of response to chemotherapy in metastatic breast cancer using sequential 18F-FDG PET. *J Nucl Med* 2005;46:1144-50.
34. Fogelman I, Cook G, Israel O, Van der Wall H. Positron emission tomography and bone metastases. *Semin Nucl Med* 2005;35:135-42.
35. Stafford SE, Gralow JR, Schubert EK, Rinn KJ, Dunnwald LK, Livingston RB, *et al.* Use of serial FDG PET to measure the response of bone-dominant breast cancer to therapy. *Acad Radiol* 2002;9:913-21.
36. Abouzied MM, Crawford ES, Nabi HA. 18F-FDG imaging: Pitfalls and artifacts. *J Nucl Med Technol* 2005;33:145-55.
37. Adejolu M, Huo L, Rohren E, Santiago L, Yang WT. False-positive lesions mimicking breast cancer on FDG PET and PET/CT. *AJR Am J Roentgenol* 2012;198:W304-14.
38. Ishimori T, Patel PV, Wahl RL. Detection of unexpected additional primary malignancies with PET/CT. *J Nucl Med* 2005;46:752-7.