


Case Report

A case of transvaginal lithotripsy for a giant vaginal calculus

Shunsuke Owa,¹  Shigenori Yonemura,¹ Masaki Sakurai¹ and Takahiro Inoue²

¹Department of Urology, Matsusaka Municipal Hospital, Matsusaka, and ²Department of Nephro-Urologic Surgery and Andrology, Mie University Hospital, Tsu, Mie, Japan

Abbreviations & Acronym

CP = calcium phosphate
CT = computed tomography
MAP = magnesium ammonium phosphate

Correspondence: Takahiro Inoue M.D., Ph.D., Department of Nephro-Urologic Surgery and Andrology, Mie University Graduate School of Medicine, 174-2, Edobashi, Tsu, Mie 514-8507 Japan.
Email: tinoue28@gmail.com

How to cite this article: Owa S, Yonemura S, Sakurai M *et al.* A case of transvaginal lithotripsy for a giant vaginal calculus. *IJU Case Rep.* 2022; 5: 157–160.

This is an open access article under the terms of the Creative Commons Attribution-NonCommercial-NoDerivs License, which permits use and distribution in any medium, provided the original work is properly cited, the use is non-commercial and no modifications or adaptations are made.

Received 23 October 2021;
accepted 25 January 2022.
Online publication 21 February 2022

Introduction: Primary vaginal calculi are relatively rare, compared with secondary calculi. Primary calculi are often a result of urogenital sinus abnormalities, neurogenic bladder, or chronic incontinence.

Case presentation: Forty-seven years old female with cerebral palsy since infancy had longstanding urinary incontinence. She visited her doctor for a fever and was referred to us with a urinary tract infection. Imaging revealed a large vaginal calculus. It was not possible to remove the calculus vaginally without crushing it, so we performed rigid cystoscopy with lithotripsy, using a pneumatic lithotripsy device. The calculus was completely removed without complications.

Conclusion: We were able to remove a large primary vaginal calculus using ultrasonic and pneumatic lithotripsy through a rigid cystoscope. Minimally invasive surgery is a good option for patients with large vaginal calculi.

Key words: pneumatic lithotripsy device, primary vaginal calculus.

Keynote message

Minimally invasive treatment using a rigid cystoscope with pneumatic lithotripsy is a good option for treating patients with large primary vaginal calculi.

Introduction

Primary vaginal calculi are relatively rare, compared with secondary calculi. Secondary vaginal calculi are most often associated with a foreign body and are, therefore, treated by removing this foreign body. No definitive treatment has been established for primary vaginal calculi.

Case report

A 47-year-old woman with a history of cerebral palsy since infancy was brought to her doctor with a fever. At her baseline status, she was unable to communicate and was bedridden. She had a known small bladder stone, diagnosed around the age of 20 years but never removed. She was diagnosed with a urinary tract infection and referred to us for treatment.

Abdominal radiography showed a large stone shadow in the lower abdomen and scoliosis of the spine. Simple abdominal CT showed a 7-mm stone in the left ureter with left-sided hydronephrosis and a 4-mm stone in the right central ureter. There was another calculus, measuring $8.1 \times 5.6 \times 7.0$ cm, in the pelvis. This large stone was positioned between the bladder and rectum; we determined that this was a vaginal calculus.

We inserted a double J stent to relieve her left hydronephrosis. Because vaginal calculi are sometimes associated with urogenital sinus abnormalities, such as vesicovaginal fistulas,¹ we performed cystography; no obvious fistula was found (Fig. 1). Inspection of the vagina with a flexible cystoscope showed a calculus occupying the vagina but no adhesions to the vaginal mucosa (Fig. 2). When a ureteral stent was placed, retrograde left urethrography was performed, but no abnormalities in left ureteral travel were observed. The CT findings also did not show any obvious travel abnormality of the right ureter. Antimicrobial therapy was then administered for the urinary tract infection, and the patient improved quickly. Urine culture test showed *Pseudomonas aeruginosa*, resistance to piperacillin, ceftazidime, tazobactam/piperacillin, and minocycline, sulfamethoxazole-trimethoprim.

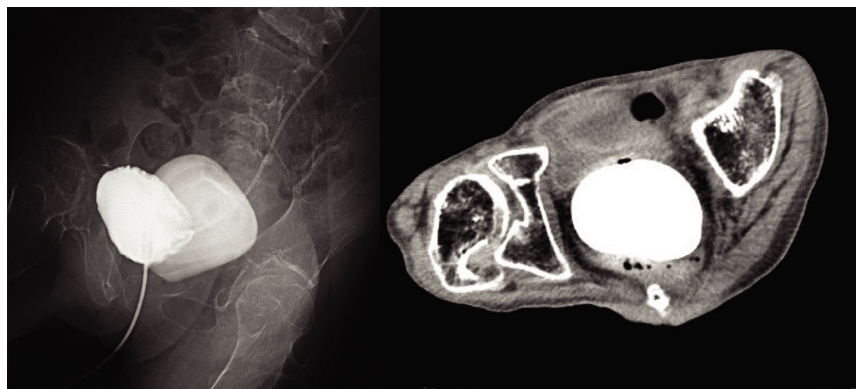


Fig. 1 Abdominal CT shows a calculus in the pelvis, measuring $8.1 \times 5.6 \times 7.0$ cm. The calculus is posterior to the bladder and anterior to the rectum. Cystography shows a stone posterior to the bladder with no evidence of a fistula between the bladder and the vagina.

For stone removal, we selected minimally invasive lithotripsy using a compressed-air system (Swiss LithoClast™; Boston Scientific, Nyon, Switzerland). Although the patient did have some lower-limb contractures, she was able to open and raise her legs a little, so the procedure was performed in the lithotomy position. A rigid cystoscope was inserted into the vagina, and the stones were crushed using the ultrasonic-pneumatic lithotripsy instrument with saline irrigation to flush out the stone fragments. The surgery took about 5 h. After removal of the calculus, we performed left ureteral lithotripsy. The composition of the vaginal calculus was 77% MAP and 23% CP.

Discussion

Vaginal calculi are rare. Depending on their etiology, they are classified as primary or secondary calculi. Primary vaginal calculus is caused by chronic stasis of urine in the vagina due to anatomical abnormalities of the urinary tract or neurogenic bladder.¹ Secondary vaginal calculi are often caused by a foreign-body nucleus, such as sutures or mesh from previous surgery.² To see a primary vaginal calculus without an anatomical abnormality is very rare, with only 10 cases reported in the literature (Table 1).

We believe that the main reason why our patient's vaginal calculus had grown to such a large size is that she was not able to communicate any subjective symptoms. If she had been able to report pain or discomfort in her lower abdomen, the calculus might have been diagnosed earlier, at a smaller size. Most vaginal calculi can be easily identified on abdominal radiography, but due to their rarity, they are often misdiagnosed as bladder stones. When abdominal CT shows a stone between the bladder and the rectum, this should raise suspicion for a vaginal calculus. In the 10 cases reported in the literature, most of the vaginal calculi were found incidentally. They were often discovered on close examination of fever with suspicion of genital bleeding or urinary tract infection. It is important to consider the possibility of vaginal stones in patients with urinary incontinence who present with pelvic stones on abdominal radiographs. It is important to consider the possibility of vaginal calculi when patients with urinary incontinence are unable to complain of symptoms.

A secondary mechanism for our patient's vaginal calculus was her cerebral palsy with long-term urinary incontinence;

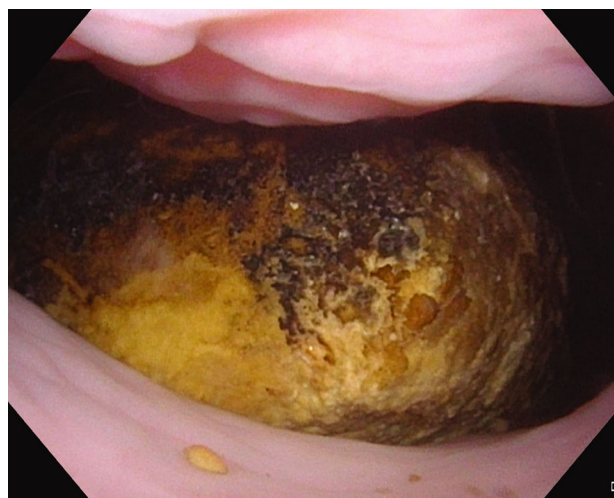

Fig. 2 The cystoscope was inserted into the vagina and a huge yellowish-brown calculus was present. The calculus was not adherent to the vaginal mucosa. There was no fistula with the bladder in the vagina.

the calculus might have formed because of chronic urine retention in the vagina. This patient had been bedridden and had urinary incontinence since childhood, so a vaginal calculus might have formed over a long period of time.

In all 10 reported patients with a primary vaginal calculus without an anatomical abnormality, MAP was the main component of the stone. MAP calculi are associated with urease-producing bacteria, such as *Proteus mirabilis* and *Pseudomonas aeruginosa*, that break down urea to produce ammonia. The urine becomes alkalized and phosphate precipitates, crystallizing MAP.³ Bacterial infection of the urinary tract may be difficult to avoid in patients with an impaired physical function who develop primary vaginal calculi. Cetinkursun *et al.* report that intermittent urinary catheterization and repositioning after treating vaginal calculi could prevent a recurrence.⁴ In bedridden patients, repositioning is often done many times during the day to avoid skin ulceration. We believe that intervening in the control of urination can contribute to the prevention of recurrence.

There is no standard treatment for vaginal calculi. When calculi are associated with mesh or other material, the foreign body must be removed. Previous reports have described laparotomy and forceps removal for primary vaginal calculi.

Table 1 Reports of primary vaginal calculi

	Patient age (years)	Medical history	Mobility	Subjective symptoms	Size of the calculus (cm)	Extraction method	Components of calculus
Buono <i>et al.</i> ¹	86	Obesity, cardiac arrhythmia, hypothyroidism, midurethral sling placed 15 years previously	Front-wheel walker	Obstipation	8.8 × 6.6 × 6.4	Sumex® handheld electric drill	80% MAP, 20% CP
Ikeda <i>et al.</i> ³	42	Cerebral palsy, congenital scoliosis	Bedridden	None (pelvic stones noted incidentally)	Maximum diameter 2.5	Kocher forceps	MAP
Cetinkursun <i>et al.</i> ⁴	13	Cerebral palsy	Unknown	Abdominal pain	4 × 3 × 2	Kocher forceps	85% MAP
Avsar <i>et al.</i> ⁵	22	Paraplegia	Wheelchair	Chronic abdominopelvic pain	9 × 7 × 2	Right-sided episiotomy	MAP
Tokgöz <i>et al.</i> ⁶	14	Unidentified neurodegenerative disease	Bedridden	Cough, poor feeding, vomiting	Maximum diameter 3.8	Under general anesthesia	MAP
Castellan <i>et al.</i> ⁷	34	West syndrome	Quadriplegia with complete fecal and urinary incontinence	Fever, left hydronephrosis	5.1 × 3.7 × 3.1	Surgical pliers	MAP
Fedrigon <i>et al.</i> ⁸	61	Global neurologic deficits, cerebral palsy	Bedridden	Vaginal bleeding	11 × 9 × 8	Endoscopic ultrasonic lithotripsy	60% MAP, 40% CP
Lin <i>et al.</i> ⁹	43	Cerebral palsy	Bedridden	Acute abdominal distension	10 × 8 × 4.5	Laparotomy	Unknown
Yoshimura <i>et al.</i> ¹⁰	11	Cerebral infarction	Bedridden	None (pelvic stones noted incidentally)	4 × 3 × 3	Removed through the vulva	MAP
Jaspers <i>et al.</i> ¹¹	5	Infantile encephalopathy, psychomotor retardation, epilepsy	Wheelchair	Repeated urinary tract infections	3 × 2 and 2 × 1	Ultrasonic device	MAP
Current patient	47	Cerebral palsy	Bedridden	Fever	8.1 × 5.6 × 7.0	Compressed air lithotripsy system	77% MAP, 23% CP

Of the 10 previously reported patients, 5 were able to undergo transvaginal calculus removal without crushing. In 3 patients, lithotripsy was performed using ultrasound equipment and other instruments. We initially considered laparotomy to remove our patient's calculus, but this is a highly invasive procedure. Instead, we opted for minimally invasive transvaginal lithotripsy using equipment that is typically used for bladder lithotripsy.

The CT findings showed that the maximum CT value at the largest diameter part of the calculus was about 1600 and the average CT value was about 1000, suggesting that the stone was quite hard. In addition, unlike cystolithotripsy, vaginal calculus could be removed from the vulva if the stone fragments could be broken down to a coarse size of about 1 cm. For this reason, we decided to use a compressed air lithotripsy system instead of a laser lithotripsy system. Intraoperatively, saline was pumped into the vagina as in the transurethral cystolithotripsy technique. Small calculus fragments flowed out from the side of the cystoscope, and large calculus fragments were removed using a vaginal speculum and a Kocher forceps. This was repeated and the giant vaginal calculus was finally removed completely.

When treating primary vaginal calculus, the choice of treatment should be based on the size of the stone. For small calculus, transvaginal grasping and removal are useful, and for large calculus requiring disruption, a compressed air lithotripsy system is useful and minimally invasive.

Conclusion

Minimally invasive lithotripsy of a primary vaginal calculus is possible using a combined ultrasonic-pneumatic lithotripsy system.

Author Contributions

Shunsuke Owa: Conceptualization; Data curation; Formal analysis; Writing – original draft; Writing – review & editing. Shigenori Yonemura: Supervision. Masaki Sakurai: Supervision. Takahiro Inoue: Supervision.

Conflict of interest

The authors declare no conflict of interest.

Approval of the research protocol by an Institutional Review Board

Not applicable.

Informed consent

As we were unable to obtain the consent of the patient, we obtained consent from the family for the presentation of this case.

Registry and the Registration No. of the study/trial

Not applicable.

References

- 1 Buono K, Wadensweiler P, Lane F, Brueseke T. Extraction of a large vaginal calculus utilizing an ear, nose, throat mallet and osteotomes. *Int. Urogynecol. J.* 2021; **32**: 211–3.
- 2 Ismail SIMF, Gasson JN. Vaginal stone formation on top of recurrent tension-free vaginal tape mesh erosion. *J. Obstet. Gynaecol.* 2014; **34**: 452–3.
- 3 Ikeda Y, Oda K, Matsuzawa N, Shimizu K. Primary vaginal calculus in a middle-aged woman with mental and physical disabilities. *Int. Urogynecol. J.* 2013; **24**: 1229–31.
- 4 Cetinkursun S, Surer I, Demirbag S, Oztürk H. A primary vaginal stone in a disabled child. *Obstet. Gynecol.* 2001; **98**: 978–9.
- 5 Avsar AF, Keskin HL, Catma T, Kaya B, Sivaslioglu AA. A large primary vaginal calculus in a woman with paraplegia. *J. Low. Genit. Tract. Dis.* 2013; **17**: 61–5.
- 6 Tokgöz Y, Erdem AO, Özbey BC, Terlemez S. A rare reason in a child with feeding intolerance: intravaginal struvite stone. *Turk. J. Pediatr.* 2018; **60**: 86–8.
- 7 Castellan P, Nicolai M, De Francesco P *et al.* Primary vaginal calculus in a woman with disability: case report and literature review. *J. Endourol. Case Rep.* 2017; **3**: 182–5.
- 8 Fedrigo D, Bretschneider CE, Muncey W, Stern K. Removal of large primary vaginal calculus using the nephroscope and endoscopic ultrasonic lithotrite: a case report. *J. Endourol. Case Rep.* 2020; **6**: 92–5.
- 9 Lin CJ, Chen CP, Wu CH, Chen HY, Hsu HH. Huge primary vaginal stone in a recumbent woman. *Taiwan J. Obstet. Gynecol.* 2005; **44**: 80–2.
- 10 Yoshimura T, Nagata Y, Matsuura K, Okamura H. Primary vaginal stone in an 11-year-old recumbent girl. *Gynecol. Obstet. Invest.* 2000; **50**: 64–6.
- 11 Jaspers JW, Kuppens SM, van Zundert AA, de Wildt MJ. Vaginal stones in a 5-year-old girl: a novel approach of removal. *J. Pediatr. Adolesc. Gynecol.* 2010; **23**: e23–5.