

## Fetal Choledochal Cyst Diagnosed at 22 Weeks of Gestation by Three-Dimensional Ultrasonography: A Case Report

Choledochal cyst is a cystic or fusiform dilatation of the extra- or intrahepatic bile duct that has rarely been reported in prenatal cases. Here we report a fetus with choledochal cyst diagnosed prenatally by three-dimensional (3-D) ultrasonography at 22 weeks of gestation. We demonstrated an image of choledochal cyst by using a new ultrasound technique, a 3-D multislice view. After close intrauterine follow-up, surgery was successfully performed and postoperative course was uneventful.

**Key Words :** *Choledochal Cyst; Three-Dimensional Multislice View; Prenatal Diagnosis*

**Il-Han Lee and Gwang-Jun Kim**

Department of Obstetrics and Gynecology, College of Medicine, Chungang University Hospital, Seoul, Korea

Received : 21 September 2007

Accepted : 10 December 2007

**Address for correspondence**

Gwang Jun Kim, M.D.

Department of Obstetric and Gynecology, Chungang University Hospital, Chungang University School of Medicine, 224-1 Heukseok-dong, Dongjak-gu, Seoul 156-756, Korea

Tel : +82.2-6299-1656, Fax : +82.2-6298-8351

E-mail : gjkim@cau.ac.kr

### INTRODUCTION

In recent years, high-resolution sonography combined with a three-dimensional (3-D) technique has advanced our ability to detect congenital diseases. Three-dimensional ultrasonography simultaneously visualizes pathologic lesions in various planes, including sagittal, coronal, transverse and oblique views. For fetal intra-abdominal cysts, this technique enables us to investigate the correct anatomic location and relation to adjacent organs. Greater appreciation of prenatal sonographic features of fetal abdominal cysts may attract medical attention for newborns earlier and may favorably impact the prognosis. Many disease entities are suspected when cystic shadows are detected in the fetal abdomen. To differentiate cystic lesions by prenatal ultrasonography, we postulate that 3-D ultrasonography may be helpful in evaluating the detailed anatomical structure, relation to adjacent organs such as the pancreas, gallbladder and liver, and estimating the remaining normal bile duct. Especially in this report, we describe the use of 3-D multislice view (Accuvix, Medison Co. Ltd., Seoul, Korea) in assisting the diagnosis of choledochal cyst.

### CASE REPORT

A 29-yr-old, gravida 1, para 0 woman was referred to our obstetric ultrasound unit at 22 weeks of gestation because of a suspected fetal abdominal cystic mass. The course of preg-

nancy had been uneventful. Her medical and family histories were unremarkable.

Detailed ultrasonography revealed a single fetus sized 22 weeks of gestation which was consistent with her estimated date of delivery. The only abnormality seen on ultrasound examination was a  $2.37 \times 1.75 \times 1.78$ -cm anechoic cyst in the right upper quadrant abdomen (Fig. 1). We obtained the image of this cyst using 3-D multislice view (3-D XI™, Medison Co. Ltd., Seoul, Korea), a new ultrasound technique. The 3-D multislice view showed that the cyst originated from the midportion of the common bile duct and was well distinct from the gallbladder, stomach and urinary bladder (Fig. 2). Thus, a tentative diagnosis of choledochal cyst was made. Repeated ultrasound examinations at 32, 36, 37, 38, and 40 weeks of gestation confirmed the presence of the cyst without changes in size. A boy weighted 3.14 kg was born at full term by Cesarean section due to abnormal presentation. The newborn baby was anicteric with cholic stools. The postnatal total and direct bilirubin levels were 8.5 and 3.4 mg/dL and postnatal ultrasonography and computerized tomography confirmed a choledochal cyst. At 44 days of age, the baby underwent a Roux-en-Y hepaticojejunostomy. The intraoperative cholangiograms and operative findings showed a type 1 choledochal cyst located at the midportion of the common bile duct (Fig. 3, 4). Histopathology was consistent with choledochal cyst. The infant is now at 10 months of age with normal liver function tests and grows normally.

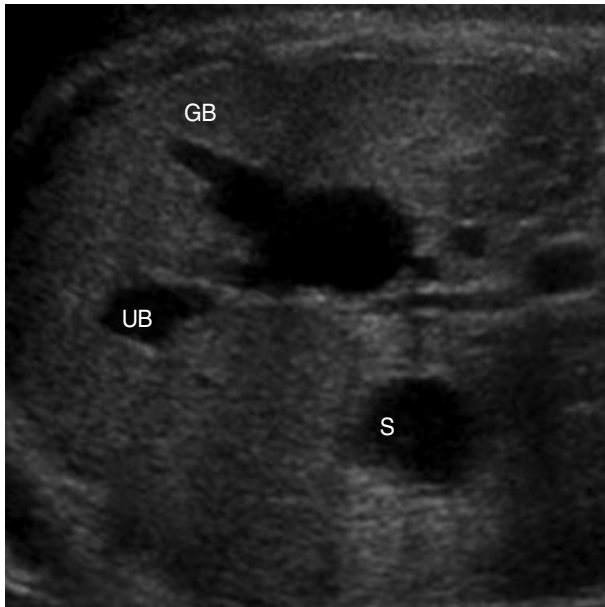


Fig. 1. Prenatal 2-D ultrasound scan at 22 weeks of gestation with an intrahepatic anechoic cystic structure ( $2.37 \times 1.75$  cm). GB, gallbladder; UB, umbilical vein; S, stomach.

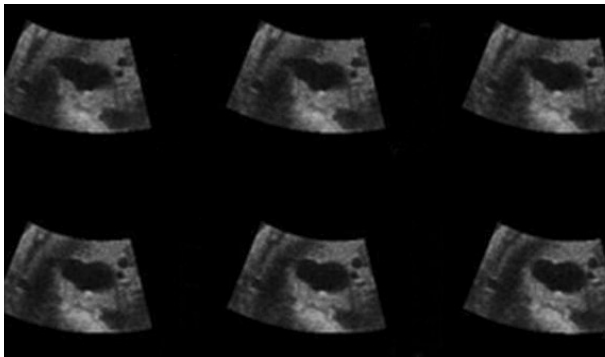


Fig. 2. Transverse view of 3-D multislice ultrasonography shows serial dimensions of an anechoic cyst.

## DISCUSSION

Choledochal cysts are rare anomalies that appear as cystic or fusiform dilatations of the extra- or intrahepatic biliary tree. The reported incidence of choledochal cysts are only 1 in 2 million live births (1). They are more commonly found among females (4:1) and in Asian populations (2). Choledochal cysts are poorly documented, and their pathogenesis is not well understood. However, two predominant theories exist, which are not actually exclusive: the theory of long common channel and the theory of distal obstruction (3). Neither one of the theories adequately accounts for the presence of all choledochal cysts.

The predominant clinical manifestations of choledochal cyst are obstructive jaundice, pain and palpable mass (4).

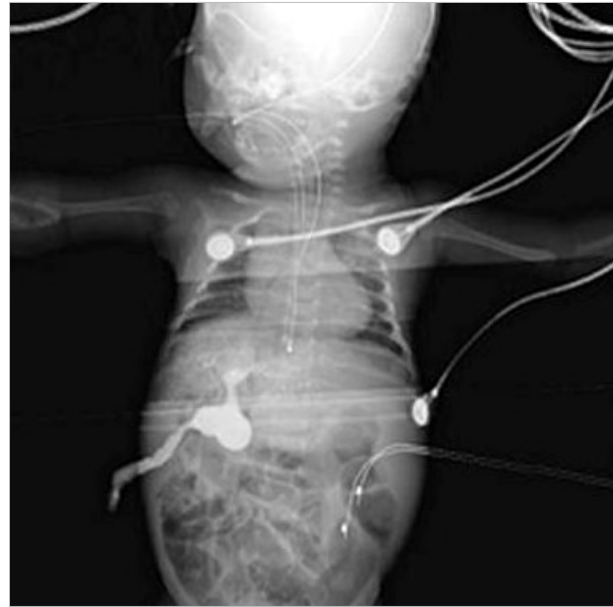


Fig. 3. Preoperative cholangiography shows a choledochal cyst.

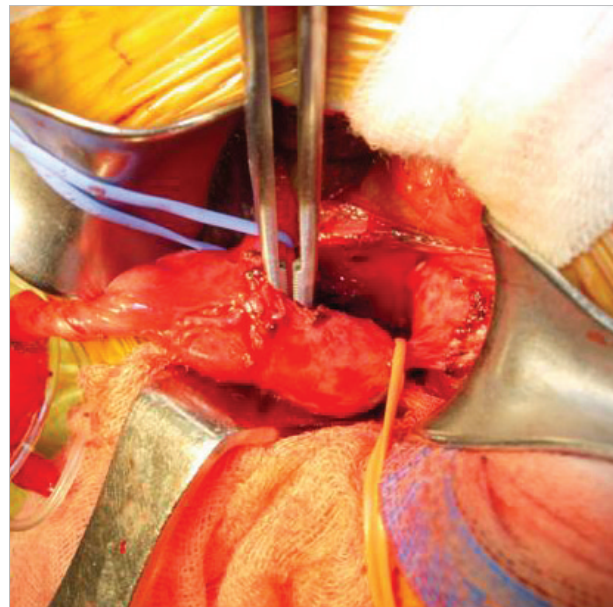


Fig. 4. Intraoperative photograph shows a  $2 \times 2 \times 2$ -cm Todani type 1 choledochal cyst located in the midportion of the common bile duct.

Diagnosis of choledochal cyst by prenatal ultrasonography allows prompt intervention in the neonate (5). The common bile duct was noted prenatally as early as at 15-16 weeks of gestation and the median gestational age at the initial diagnosis was 20 weeks in 10 reported cases (4). Fetal choledochal cyst usually appears as a fluid filled, anechoic mass in the region of the porta hepatis. Demonstration of continuity with the gall bladder or hepatic ducts or associated dilatations of intra- and extrahepatic ducts further aids the diagnosis. The

differential diagnosis of choledochal cyst includes simple hepatic cyst, biliary atresia, ovarian, omental or mesenteric cyst, duodenal or gallbladder duplication, adrenal cyst, renal cyst, dilated loops of the bowel, hydronephrotic renal pelvis and situs inversus. In a series of 13 patients with biliary disease and abnormal antenatal scans, the correct diagnosis was made prenatally in only 15% of cases (4). The difficulty in differential diagnosis lies between choledochal cyst and cystic biliary atresia. There is evidence that the outcome of surgery for cystic biliary atresia has improved with earlier operations (6). Since it is difficult to distinguish between choledochal cyst and cystic biliary atresia by prenatal ultrasonography, a child with presumptive choledochal cyst should undergo early exploration to rule out biliary atresia. Because of the different prognosis between choledochal cyst and biliary atresia, an accurate diagnosis is desirable for correct counseling. However, choledochal cyst and biliary atresia may substantially share many of the same structural deformities, and as of yet, there are no ultrasound differential parameters that are unequivocally accepted. Casaccia et al. (7) reported that the prenatal ultrasound patterns make an antenatal differential diagnosis of biliary anomalies. Muller et al. (8) have reported that fetuses with choledochal cyst have significantly lower amniotic fluid gamma-glutamyl transferase values which indicate decreased bile excretion *in utero*. The 3-D multislice view enables 3-D anatomy to be displayed as serial images similar to magnetic resonance imaging or computed tomography. This technology transforms 3-D volume data obtained from a single 3-D scan into sequential images at variable intervals (0.5 to 5 mm). Kim et al. (9) have reported that 3-D ultrasonography using multislice view helps provide an external panoramic view in order to diagnose anatomic details in terms of location and relation to the fetal airway. However, the usefulness of the 3-D multislice view for examining fetal hepatobiliary structures has not yet been ascertained. In the case reported here, we suggest that the 3-D multislice view can reveal a more definite location and anatomic relation of the cyst than conventional 2-D ultrasound examination.

Choledochal cysts should be completely resected, if possible, due to long-term complications such as cholangitis, liver cirrhosis, pancreatitis, and cancer. The timing of treatment has not yet been clearly defined. If the patient's clinical status permits, early definite surgery, generally before 6 months of age, seems to be ideal for most patients. It is acknowledged that the best long-term therapy is resection of a cyst with

bilioenteric reconstruction, most commonly through Roux-en-Y hepaticojejunostomy. In conclusion, fetal choledochal cyst is a rare disorder that can be recognized in the early second trimester by ultrasonography. Here we suggest that precise imaging such as 3-D ultrasonography may facilitate prenatal counseling, timing of delivery, and perinatal management of fetal choledochal cyst.

## ACKNOWLEDGMENT

The authors thank Dr. SJ Cha (Department of General Surgery, Chungang University Hospital, Seoul, Korea) for performing this difficult operation.

## REFERENCES

1. Dewbury KC, Aluwihare AP, Birch SJ, Freeman NV. *Prenatal ultrasound demonstration of a choledochal cyst. Br J Radiol* 1980; 53: 906-7.
2. Todani T, Urushihara N, Morotomi Y, Watanabe Y, Uemura S, Noda T, Sasaki K, Yoshikawa M. *Characteristics of choledochal cysts in neonates and early infants. Eur J Pediatr Surg* 1995; 5: 143-5.
3. Babbitt DP. *Congenital choledochal cysts: new etiological concept based on anomalous relationships of the common bile duct and pancreatic bulb. Ann Radiol (Paris)* 1969; 12: 231-40.
4. Schroeder D, Smith L, Prain HC. *Antenatal diagnosis of choledochal cyst at 15 weeks' gestation: etiologic implications and management. J Pediatr Surg* 1989; 24: 936-8.
5. Redkar R, Davenport M, Howard ER. *Antenatal diagnosis of congenital anomalies of the biliary tract. J Pediatr Surg* 1998; 33: 700-4.
6. Grosfeld JL, Rescorla FJ, Skinner MA, West KW, Scherer LR 3rd. *The spectrum of biliary tract disorders in infants and children. Experience with 300 cases. Arch Surg* 1994; 129: 513-8.
7. Casaccia G, Bilancioni E, Nahom A, Trucchi A, Aite L, Marcellini M, Bagolan P. *Cystic anomalies of biliary tree in the fetus: is it possible to make a more specific prenatal diagnosis? J Pediatr Surg* 2002; 37: 1191-4.
8. Muller F, Gauthier F, Laurent J, Schmitt M, Boué J. *Amniotic fluid GGT and congenital extrahepatic biliary damage. Lancet* 1991; 337: 232-3.
9. Kim SK, Won HS, Lee SW, Kim JK, Shim JY, Lee PR, Kim A. *Prenatal diagnosis of congenital epulis by three-dimensional ultrasound and magnetic resonance imaging. Prenat Diagn* 2006; 26: 171-4.