

# Myocarditis associated with immune checkpoint inhibitors: Practical considerations in diagnosis and management

id *Muhammet Gürdoğan*, id *Kenan Yalta*

Department of Cardiology, Faculty of Medicine, Trakya University; Edirne-Turkey

## ABSTRACT

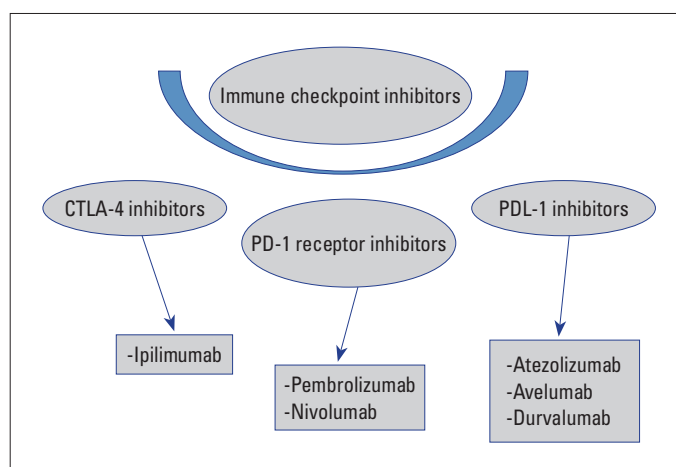
Immune checkpoint inhibitors (ICI) have caused radical changes in the treatment scheme of many types of cancer in the past 10 years. ICIs are specific monoclonal antibodies that increase T-cell mediated immune response against cancer cells. Despite important advances in cancer treatment, uncontrolled activation of cytotoxic T cells has brought along many autoimmune clinical side effects, especially acute myocarditis. Although the incidence of ICI-related myocarditis is about 1%, it is remarkable in terms of mortality rate reaching 46% and demonstrating the necessity of rapid diagnosis and multidisciplinary approach. The present review aimed to summarize the heterogeneous symptomatology of ICI-associated myocarditis, clinical presentation ranging from elevated asymptomatic cardiac enzyme levels to cardiogenic shock, prominent diagnostic value of cardiac magnetic resonance imaging, and current information on the effectiveness of immunosuppressants in therapy. (*Anatol J Cardiol* 2020; 24: 68-75)

**Keywords:** cardiotoxicity, immune checkpoint inhibitor, myocarditis

## Introduction

Immune checkpoint inhibitors (ICIs) have been introduced into clinical practice as specific monoclonal antibodies that demonstrate significant anticancer activity through enhancement of T-cell-mediated immune response against tumor cells (1). These agents have been considered as the most important breakthrough of cancer management over the past 10 years with a significant potential to induce radical changes in the management algorithm of many cancer types including malignant melanoma, non-small cell lung carcinoma, and renal cell carcinoma (1-3). Mechanistically, ICIs, instead of direct anticancer action, primarily inhibit specific pathways that downregulate T lymphocyte response to the tumoral cells potentially rendering them as the target of cytotoxic T cells. ICIs exert their actions through three basic pathways: cytotoxic T lymphocyte-associated antigen-4 (CTLA-4), programmed cell death protein 1 (PD-1), and programmed cell death ligand 1 (PD-L1) (Fig. 1) (4). However, with the gradually expanding use of ICIs in clinical practice, various autoimmune-mediated adverse events including acute myocarditis have been increasingly encountered possibly due to the uncontrolled activation of cytotoxic T cells (5). Table 1 lists major

cardio toxic events reported to be associated with the use of ICIs in the literature (1-10). This study aimed to discuss diagnostic and therapeutic implications of ICI-associated myocarditis in clinical practice.



**Figure 1.** Major types of immune checkpoint inhibitor-related cardiotoxicity

CTLA-4 - cytotoxic T lymphocyte-associated antigen-4; PD-1 - programmed cell death protein receptor; PD-L1 - programmed cell death protein ligand

**Address for correspondence:** Dr. Muhammet Gürdoğan, Trakya Üniversitesi Tıp Fakültesi, Kardiyoloji Anabilim Dalı, Edirne-Türkiye  
Phone: +90 284 235 10 41 (ext. 1475) E-mail: drmgurdogan@gmail.com

**Accepted Date:** 12.06.2020 **Available Online Date:** 27.07.2020

©Copyright 2020 by Turkish Society of Cardiology - Available online at [www.anatoljcardiol.com](http://www.anatoljcardiol.com)  
DOI:10.14744/AnatolJCardiol.2020.79584



**Table 1. Major types of ICI-related cardiotoxicity**

Cardiotoxicity	Incidence*
Myocarditis	0.09%-2.4%
Pericarditis	<1%-2%
Pericardial effusion	2%
Cardiac arrhythmia	4%
Myocardial infarction	<1%-2%
Heart failure	0.4%
Takotsubo cardiomyopathy	Rarely reported
Cardiac arrest	Rarely reported

\*The frequency of ICI-related cardiotoxicity varies according to the molecule used and the method of treatment (monotherapy/combination)

### ICI and immune myocarditis

#### Mechanisms

The mechanism of ICI-related myocarditis has not been clearly elucidated yet. However, immunological homeostasis failure has been suggested to be caused by the inhibition of CTLA-4, PD-1, and PD-L1 receptors, known as the checkpoint immune system, and reduced T cell tolerance to normal tissues initiate all immune-related adverse events, including myocarditis (8, 10-12). CTLA-4 and PD-1 proteins are receptors on cytotoxic T lymphocytes that enable the control of the immune response by suppressing the excessive activation of these cells (1, 2). PD-L1 receptors, on the other hand, are ligands found in normal cells such as cardiomyocytes and bind to receptors on cytotoxic T lymphocytes and play a cardio protective role against excessive activation of these cells (11, 12). In the literature, it has been reported that cytotoxic T cell infiltration and PD-L1 inhibition are observed in myocardial tissue in postmortem analysis of ICI-related lethal myocarditis cases (8, 12). Additionally, lethal myocarditis and dilated cardiomyopathy associated with cytotoxic T-lymphocyte infiltration have been reported in studies with CTLA-4 and PD-1 knockout mice investigating the effects of immunotherapeutics (13). Another study reported that macrophage and B cell infiltrations, mainly CD4+ and CD8+ T cells, were less common in the myocardium of cynomolgus monkeys given with the combination of ipilimumab and nivolumab (14).

As a summary, in the light of data from postmortem analyses and animal studies, the primary mechanisms responsible for the development of ICI-related myocarditis are as follows: 1. Cross-reaction infiltration of normal myocardial tissue, which was detected as a tumor cell by immune system cells (especially cytotoxic T lymphocytes) and 2. Myocardial damage due to inhibition of PD-1/PD-L1 receptors, which play a cardio protective role against uncontrolled immune response (10, 11, 15).

#### Clinical features

Even though the overall incidence of ICI-associated immune myocarditis appears to be around 1%, its mortality rate might

potentially reach 46% absolutely mandating a rapid diagnostic process with a multidisciplinary approach (5-7). Clinical presentation generally ranges from an asymptomatic elevation of cardiac enzymes to sudden death due to heart failure. Accordingly, symptoms generally present with a heterogeneous clinical spectrum that might include dyspnea (usually accompanied by a reduced left ventricular ejection fraction (LVEF) value), palpitations, nausea, fatigue, weight loss, and chest pain (6). In full-blown cases, all aspects of an acute heart failure scenario are usually fully established. However, clinical findings in this setting might be easily overlooked since patients receiving ICI treatment already appear to suffer significant frailty generally manifesting as malaise, low exercise capacity, and dyspnea associated with the primary disease itself (lung cancer, etc.).

#### Temporal emergence

In particular, the first three months of ICI treatment is considered as a high-risk period in the development of immune myocarditis (7, 16, 17). According to a large case series study by Mahmood et al. (7), the median time to onset of myocarditis development from the first ICI dose was reported to be 34 days. Importantly, another study by Atallah-Yunes et al. (17) reported that 93% of subjects with fatal myocarditis received only one or two doses of ICI. Of note, previous cases of immune myocarditis were reported to develop even within the first 15 days of therapy, particularly in those who had received combination therapy (ICI+tyrosine kinase inhibitors (TKI) and/or previous PD-1 inhibition) (6).

#### Accompanying clinical conditions

It is well known that a second immune-related condition can potentially develop with ICI-associated immune myocarditis (7, 16, 17). Accompanying conditions in this setting have been reported such as myositis, colitis, nephritis, and hepatitis. Interestingly, these concomitant conditions might just precede the evolution of myocarditis and, hence, might serve as a predictor of an impending myocarditis (7, 16). However, varied symptoms in these conditions can lead to significant delays in their diagnosis. Particularly in myositis (the most frequently accompanying condition), attribution of symptoms (including fatigue and widespread myalgia) to a metastatic malignancy might delay the diagnosis of an existing myositis (that strongly warrants interruption of ICI therapy) and, hence, also substantially increase the risk for myocarditis with uninterrupted ICI use. Therefore, treating clinicians should also be fully aware of these immune-related events and their clinical implications during ICI therapy (7, 16, 17).

#### Diagnosis

The diagnosis of an immune-related myocarditis generally requires a high index of suspicions and mandates close monitoring of ICI recipients. It should be carefully considered that a timely diagnosis in this setting generally translates into a timely

initiation of life-saving therapeutic strategies for a given patient. In fact, there exists only limited information in the literature regarding the diagnosis and management of ICI-related myocarditis, most of which are primarily based on expert opinion. The fundamental reason for diagnostic delay in ICI-related myocarditis is due to the existing nonspecific symptomatology (frequently encountered in cancer patients) along with the frequent coexistence of noncardiac factors associated with cardiac biomarker elevation in this group of patients. Figure 2 shows an algorithm for the differential diagnosis of ICI-related myocarditis (10, 11, 15, 18-23).

### Identification of high-risk groups

In ICI therapy, the possibility of an ICI-related myocarditis should be considered by the treating clinician even in the presence of asymptomatic troponin elevation and/or myositis that presents with fatigue, widespread muscle pain, and elevated creatine kinase (CK). Particularly in combination therapy (CI+TKI) and/or previous PD-1 inhibitor, asymptomatic troponin elevation should raise a high index of suspicion (8, 17). It has been reported that the risk of myocarditis is fivefold in combination therapy (nivolumab and ipilimumab) compared with nivolumab only (8, 17). It is also noteworthy that myositis occurs in approximately one-third of those with ICI-associated myocarditis. Accordingly, previous studies suggested that an existing myositis should be considered as a “red flag” for the diagnosis of ICI-related myocarditis (8, 16, 17).

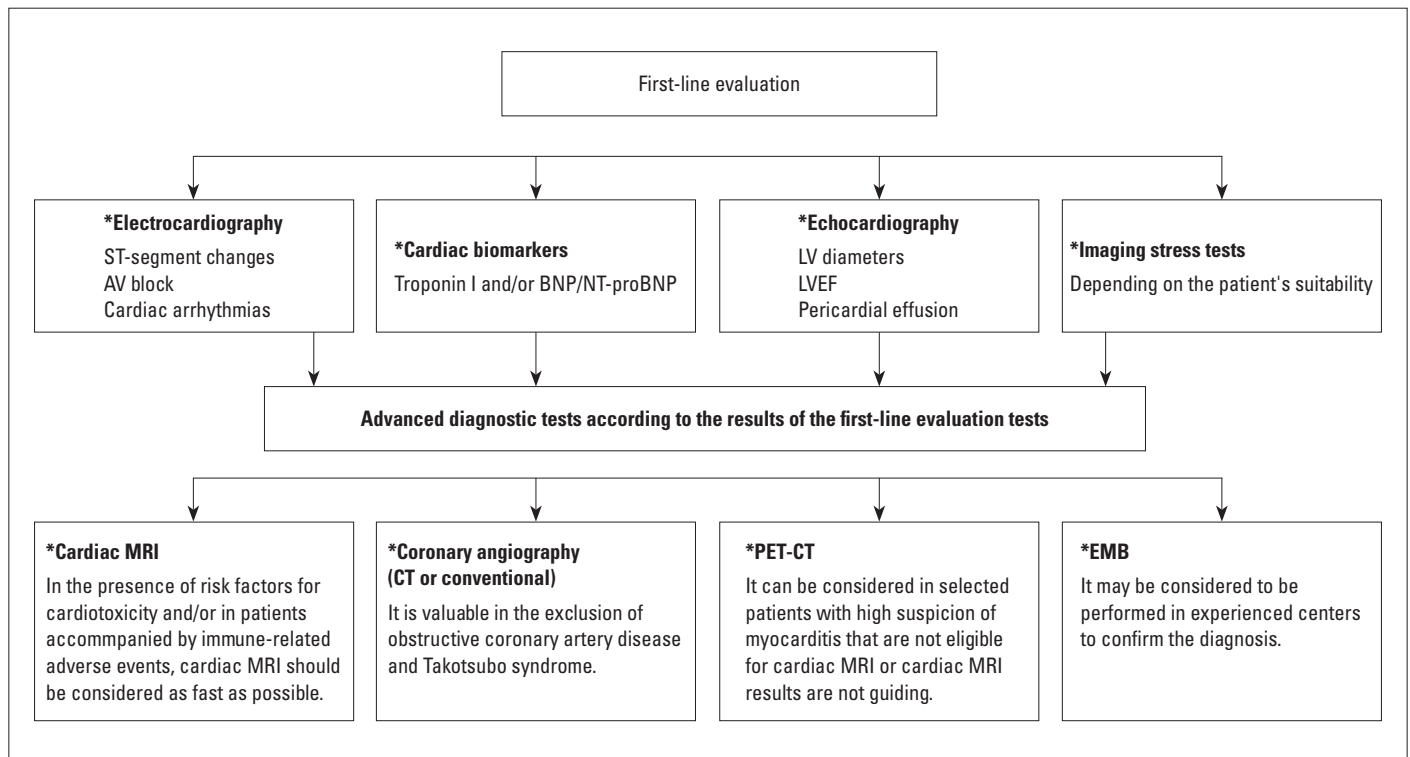
### Electrocardiogram (ECG)

Currently, ECG finding for patients with ICI-related myocarditis remains nonspecific. However, nearly 90% of these patients have been reported to have various new-onset ECG changes (7). An ECG finding has been suggested to include sinus tachycardia, bundle branch block, atrial fibrillation, AV block, bigeminy, ventricular premature beats, ventricular tachycardia, and ST-segment elevation (8, 17, 24, 25). Even though ECG generally has a limited diagnostic value in ICI-associated myocarditis, it is an easily accessible and low-cost test and, hence is recommended at the beginning and before every consecutive dose of ICI treatment (26) so potential changes can be monitored in time.

### Cardiac biomarkers

**Troponin:** Studies showed that almost all patients with ICI-associated myocarditis have elevated high-sensitivity troponin levels (1). High troponin levels strongly suggest the presence of an ongoing damage due to myocardial inflammation (4). As expected, a strong correlation was observed between troponin levels and the risk of major adverse cardiac events including cardiovascular death, shock, and AV complete block in patients with ICI-related myocarditis (8, 17, 24). However, troponins are quite nonspecific in this setting as it is well known that various noncardiac causes of troponin elevation also exist in the clinical setting.

**Natriuretic peptides:** Similar to troponins, these peptides are also nonspecific in this setting (7, 27). Importantly, owing to



**Figure 2.** How to make the differential diagnosis in patients using ICI and presenting nonspecific symptoms: An algorithm for the clinician  
BNP/NT-proBNP - brain natriuretic peptide; LV - left ventricle; EF - ejection fraction; MRI - magnetic resonance imaging; CT - computed tomography; PET-CT - positron emission tomography-computed tomography; EMB - endomyocardial biopsy

the significant inflammatory process induced by cancer itself, N-terminal pro-brain natriuretic peptide (NT-proBNP) might be chronically elevated among cancer patients. Moreover, all other acute cardiac stress conditions that the cancer patient potentially suffers might have elevated NT-proBNP levels (9, 27). However, it is well known that increased myocardial wall stress appears to be the primary trigger for natriuretic peptide release. Therefore, these peptides usually increase to substantial levels in myocarditis accompanied by acute heart failure.

### **Echocardiography**

Results of previous studies on the clinical relevance of echocardiography in diagnosis and long-term risk stratification of ICI-related myocarditis are conflicting. A study by Escudier et al. (9) reported that three-fourth of patients diagnosed with ICI-associated myocarditis developed left ventricular dysfunction on echocardiography, while another study by Mahmood et al. (7) reported that ejection fraction was within normal limits in more than half of the patients who suffered ICI-associated myocarditis. Echocardiography also has a limited value in predicting cardiovascular outcomes among patients with ICI-associated myocarditis (17). An existing normal ejection fraction value does not exclude ICI-related myocarditis (7). Moreover, a previous study reported that the left ventricle might not dilate in fulminant myocarditis (7, 9). Even though an existing normal systolic function potentially denotes a relatively benign and self-limiting course, this does not warrant an absolute sign of perfect prognosis. Therefore, in patients with suspected myocarditis, further tests including cardiac magnetic resonance imaging (MRI) are necessary to detect myocardial inflammation particularly in the presence of normal systolic functions (4).

### **MRI**

Cardiac MRI, a noninvasive method, plays a pivotal role in the early detection and serial monitoring of myocardial inflammation. In T1-/T2-weighted MRI of patients with ICI-related myocarditis, mid-myocardial edema and late gadolinium enhancement that does not correspond to coronary anatomy are of particular importance (25, 26, 28). The specificity and sensitivity of MRI in the diagnosis of myocarditis are 91% and 67%, respectively. It should be carefully considered that MRI may be completely normal in 20–30% of ICI-related myocarditis with diffuse or low-grade inflammation (9, 25, 26, 28), complementing the results for MRI in the diagnosis of ICI-related myocarditis. Furthermore, FDG-PET can also be utilized to monitor the degree of inflammation in myocarditis and manage immunosuppressive therapy accordingly (29).

### **Endomyocardial biopsy**

Endomyocardial biopsy has been suggested as the gold standard diagnostic method in ICI-related myocarditis (17, 30, 31). Detection of lymphocytic infiltration along with myocyte

necrosis in the biopsy material is of diagnostic value. Inflammatory and fibrotic changes characterized by infiltration of CD 4+ and CD 8+ T cells (CD 8+ involvement is reported to be more dominant in the conduction system), macrophages, and occasionally B and plasma cells (with the particular absence of eosinophilic granuloma or giant cells) are quite typical in this setting (4, 17, 32). Since endomyocardial biopsy is an invasive procedure with significant false-negative results (particularly when the biopsy material is taken from disease-free territories), its diagnostic value is limited in this setting (28). Table 2 summarizes diagnostic and follow-up methods for the prevention or early diagnosis of myocarditis in cancer patients receiving ICI therapy.

### **Management Strategies**

#### **Immunosuppressive therapy**

Postmortem analysis in patients who succumbed to ICI-related myocarditis has reported significant infiltration of various T cell populations (7). This substantiates the idea that the fundamental mechanism accounting for myocyte damage results from the over activation of cytotoxic T cells. Although no strong evidence-based recommendations has been reported, suppression of high-grade inflammatory response within the myocardium largely through immunosuppressive agents has been suggested as a milestone in the treatment of ICI-associated myocarditis (24, 30, 33, 34). Within this context, even though corticosteroids (7) appear to be the basis of immunosuppressive therapy, cases have been reported where treatment regimens including antithymocyte globulin (6), mycophenolate mofetil (6), abatacept (33), alemtuzumab (34), tacrolimus (30), and rituximab (30) have been initiated depending on LVEF, hs-troponin level along with hemodynamic status. The common mechanism of action of these agents is to induce the inactivation or destruction of T cells, that are considered to play a pivotal role in the evolution of myocarditis, as confirmed by endomyocardial biopsy findings of patients with ICI-related myocarditis. Therefore, since initiation of immunosuppressive therapy in ICI-related myocarditis implies the reversal of anti-tumor immunity, careful consideration of risks and benefits is strongly warranted beforehand.

In ICI-related myocarditis with left ventricular systolic dysfunction, heart failure treatment as per current guidelines should be immediately started (6). However, clear consensus on the optimal dose of corticosteroids (the first-line treatment to start as an immunosuppressive) and on how and when to add other immunosuppressive agents has not been reported yet. In this regard, the initial dose of corticosteroid [(methyl) prednisolone] is usually recommended as 1–2 mg/kg in the present study (6, 7, 9). Some studies showed strong association of high-dose steroid therapy with a significantly lower rate of major adverse cardiac events (6, 7). In fact, mostly based on hs-Troponin levels of the patient, continuing with a higher steroid dose during the maintenance period is highly recom-

**Table 2. Diagnosis and follow-up strategies for the prevention or early diagnosis of ICI-related myocarditis**

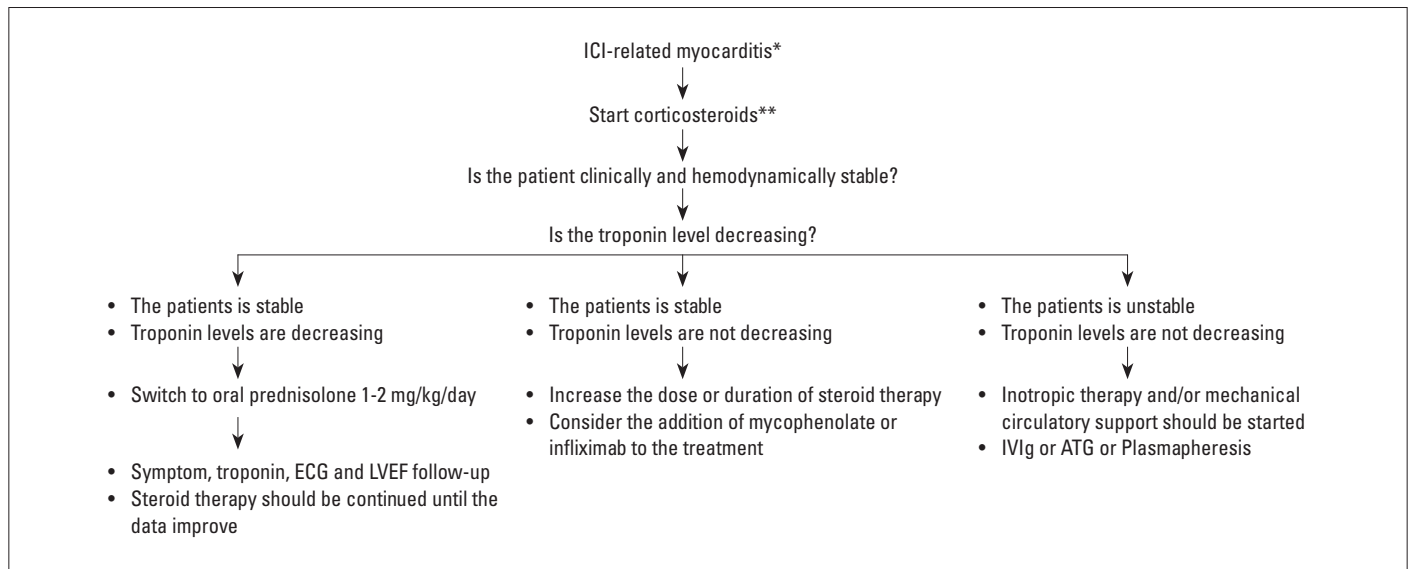
Assess potential risk factors for the evolution of ICI-related myocarditis	<ul style="list-style-type: none"> <li>- The combination of dual ICIs (such as ipilimumab+nivolumab) or ICI+cardio toxic VEGF tyrosine kinase inhibitors</li> <li>- Accompanying immune-related adverse event, especially myositis               <ul style="list-style-type: none"> <li>- History of myocardial infarction, heart failure, myocarditis, previous treatment with an anthracycline, history of cancer therapy-associated left ventricular dysfunction</li> </ul> </li> <li>- Presence of autoimmune diseases such as systemic lupus erythematosus, rheumatoid arthritis, and sarcoidosis.</li> </ul>
Perform basic cardiovascular assessment	<ul style="list-style-type: none"> <li>- Clinical history</li> <li>- ECG</li> <li>- Cardiac biomarkers: troponin, BNP, or NT-proBNP</li> <li>- Creatinine kinase</li> <li>- Echocardiogram</li> </ul>
Close follow-up (particularly during the first 3 months when the risk is high)	<ul style="list-style-type: none"> <li>- In high-risk patients, ECG, cardiac troponin, and NT-proBNP should be checked before 2<sup>nd</sup> or 4<sup>th</sup> doses.</li> <li>- In high-risk patients, echocardiography should be performed before 2<sup>nd</sup> or 3<sup>rd</sup> doses, and echocardiography should be repeated every 3–6 months if there is initial left ventricular or right ventricular dysfunction.</li> <li>- Question the emerging symptoms: fatigue, muscle pain, fever, chest pain, shortness of breath, palpitations, presyncope, or syncope, etc.</li> </ul>
Suspected myocarditis	<p>Follow multidisciplinary approach. Refer to the cardio-oncology outpatient clinic in case of recently elevated troponin, NT-proBNP increase, and ECG or echocardiographic abnormality.</p> <ul style="list-style-type: none"> <li>- The patient should be referred to the cardio-oncology outpatient clinic               <ul style="list-style-type: none"> <li>- ECG (new changes?)</li> <li>- Repeat echocardiography</li> </ul> </li> <li>- In the presence of palpitations, presyncope, or syncope, a 24-hour rhythm Holter test is indicated</li> <li>- Troponin (normal troponin levels during follow-up does not exclude myocarditis)</li> <li>- BNP/NT-proBNP (It should be noted that these peptides may increase in every condition associated with acute cardiac stress and might even remain chronically high due to cancer-related inflammatory process)</li> <li>- CKMB/CK (particularly in the setting of suspected false-positive troponin values)               <ul style="list-style-type: none"> <li>- Cardiac catheterization (±endomyocardial biopsy), cardiac MRI or cardiac CT based on clinical situation</li> </ul> </li> </ul>

ICI - immune checkpoint inhibitor; ECG - electrocardiography; BNP - B-type natriuretic peptide; CK - creatine kinase; MRI - magnetic resonance imaging; CT - computed tomography

mended (28). Previous studies reported on the use of mycophenolate mofetil (1 g oral BD), intravenous immunoglobulin (IVIG) (3 days, 2 g/day), antithymocyte globulin, and infliximab in steroid-refractory myocarditis cases. However, given the relation between infliximab and heart failure, this agent should not be given in high doses (6, 7, 35, 36). Figure 3 shows an algorithm for the treatment of patients according to their response to corticosteroid (7, 11, 17, 22, 31).

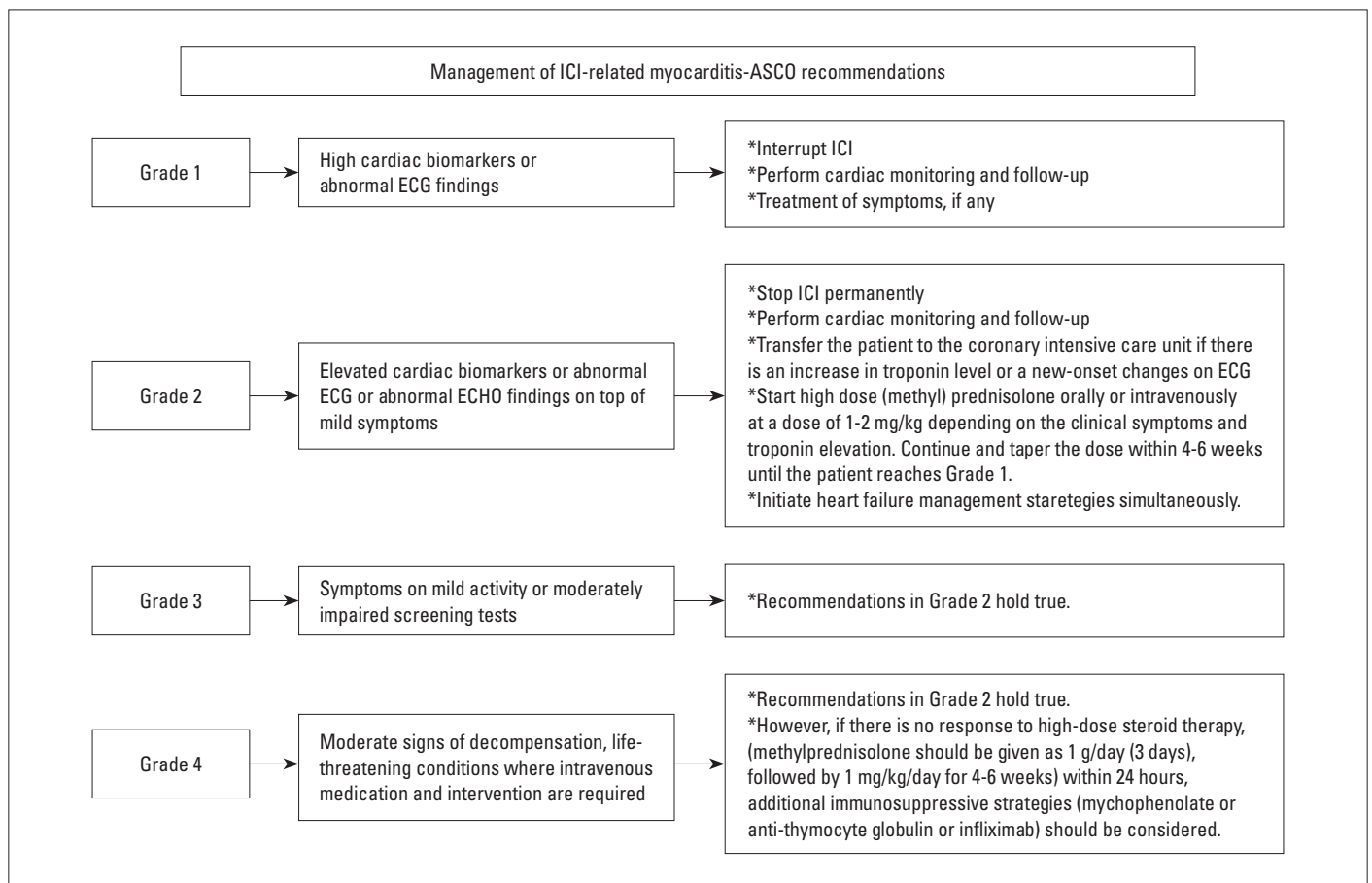
### Prevention of ICI-related myocarditis: General strategies before, during, and after treatment

Currently, evidence for the role of cardiac monitoring, optimal follow-up strategy, or cardio protective strategies in patients with ICI-related myocarditis is nonspecific. Diagnosis and treatment methods suggested for the prevention and early diagnosis of ICI-related myocarditis (Table 2) should apply to all cancer patients receiving ICI therapy (1, 4, 6, 7, 30, 31, 37). The American



**Figure 3.** Follow-up of the patient according to the response to corticosteroid treatment in ICI-related myocarditis

ICI - immune checkpoint inhibitors; ECG - electrocardiogram; LVEF - left ventricular ejection fraction; IVIg - intravenous immunoglobulin; ATG - anti-thymocyte globulin  
 \*There are no prospective or randomized controlled studies evaluating treatment options for ICI-related myocarditis. The available information is based on case series experience. There is no clear information about the optimal duration and dose for corticosteroid therapy. However, based on the experience, it is recommended to continue the treatment for 4-6 weeks and to reduce it according to clinical and troponin levels.  
 \*\*The American Society of Clinical Oncology (ASCO) guidelines recommend the initial dose for corticosteroid therapy as 1 mg/kg/day oral or intravenous (IV). In case series in the literature, it is reported that faster recovery in clinical and troponin levels and lower rates of major adverse cardiovascular events (MACE) are observed during follow-up period with a high initial dose (1000 mg/day/IV 3-5 days) of corticosteroid treatment



**Figure 4.** Management of immune checkpoint inhibitor-related myocarditis-ASCO recommendations

Society of Clinical Oncology (ASCO) recommendations (based on expert opinions in the presence of possible or definitive myocarditis) are presented in Figure 4 (31).

### Clinical course and prognosis

Future evolution of dilated cardiomyopathy has been reported in one-third of subjects with ICI-related myocarditis (38, 39). Mortality rate with the used of monotherapy (nivolumab) is around 10%, while it exceeds 60% in those receiving combination therapy (nivolumab + ipilimumab) (25). On the other hand, whether the occurrence of immune-mediated adverse events during ICI therapy is associated with the degree of antitumor activity still remains to be established (40, 41). Clinical decision-making for resumption of ICI following successful immunosuppression was suggested to be based on the severity of initial ICI-related myocarditis. It seems noteworthy that half of the patients were reported to suffer myocarditis recurrence or another immune-related event when ICI treatment was re-initiated following recovery from myocarditis. In general, restarting ICIs in survivors of life-threatening cardiotoxicity associated with these agents is not recommended (39, 41).

**Conflict of interest:** None declared.

**Peer-review:** Externally peer-reviewed.

**Authorship contributions:** Concept – M.G., K.Y.; Design – M.G., K.Y.; Supervision – M.G., K.Y.; Funding – M.G., K.Y.; Materials – M.G., K.Y.; Data collection and/or processing – M.G., K.Y.; Analysis and/or interpretation – M.G., K.Y.; Literature search – M.G., K.Y.; Writing – M.G., K.Y.; Critical review – M.G., K.Y.

### References

- Lyon AR, Yousaf N, Battisti NML, Moslehi J, Larkin J. Immune checkpoint inhibitors and cardiovascular toxicity. *Lancet Oncol* 2018; 19: e447-58.
- Gong J, Chehrazhi-Raffle A, Reddi S, Salgia R. Development of PD-1 and PD-L1 inhibitors as a form of cancer immunotherapy: a comprehensive review of registration trials and future considerations. *J Immunother Cancer* 2018; 6: 8.
- Zadok OIB, Ben-Avraham B, Nohria A, Orvin K, Nassar M, Iakobishvili Z, et al. Immune-Checkpoint Inhibitor-Induced Fulminant Myocarditis and Cardiogenic Shock. *J Am Coll Cardiol CardioOnc* 2019; 1: 141-4.
- Chen DY, Huang WK, Chien-Chia Wu V, Chang WC, Chen JS, et al. Cardiovascular toxicity of immune checkpoint inhibitors in cancer patients: A review when cardiology meets immuno-oncology. *J Formos Med Assoc* 2019; S0929-6646(19)30408-5.
- Friedman CF, Proverbs-Singh TA, Postow MA. Treatment of the Immune-Related Adverse Effects of Immune Checkpoint Inhibitors: A Review. *JAMA Oncol* 2016; 2: 1346-53.
- Guo CW, Alexander M, Dib Y, Lau PKH, Wepler AM, Au-Yeung G, et al. A closer look at immune-mediated myocarditis in the era of combined checkpoint blockade and targeted therapies. *Eur J Cancer* 2020; 124: 15-24.
- Mahmood SS, Fradley MG, Cohen JV, Nohria A, Reynolds KL, Heinzerling LM, et al. Myocarditis in patients treated with immune checkpoint inhibitors. *J Am Coll Cardiol* 2018; 71: 1755-64.
- Johnson DB, Balko JM, Compton ML, Chalkias S, Gorham J, Xu Y, et al. Fulminant myocarditis with combination immune checkpoint blockade. *N Engl J Med* 2016; 375: 1749-55.
- Escudier M, Cautela J, Malissen N, Ancedy Y, Orabona M, Pinto J, et al. Clinical features, management, and outcomes of immune checkpoint inhibitor-related cardiotoxicity. *Circulation* 2017; 136: 2085-7.
- Choi J, Lee SY. Clinical Characteristics and Treatment of Immune-Related Adverse Events of Immune Checkpoint Inhibitors. *Immune Netw* 2020; 20: e9.
- Palaskas N, Lopez-Mattei J, Durand JB, Iliescu C, Deswal A. Immune Checkpoint Inhibitor Myocarditis: Pathophysiological Characteristics, Diagnosis, and Treatment. *J Am Heart Assoc* 2020; 9: e013757.
- Yang Y. Cancer immunotherapy: harnessing the immune system to battle cancer. *J Clin Invest* 2015; 125: 3335-7.
- Waterhouse P, Penninger JM, Timms E, Wakeham A, Shahinian A, Lee KP, et al. Lymphoproliferative disorders with early lethality in mice deficient in Ctlα-4. *Science* 1995; 270: 985-8.
- Ji C, Roy MD, Golas J, Vitsky A, Ram S, Kumpf SW, et al. Myocarditis in cynomolgus monkeys following treatment with immune checkpoint inhibitors. *Clin Cancer Res* 2019; 25: 4735-48.
- Varricchi G, Marone G, Mercurio V, Galdiero MR, Bonaduce D, Tocchetti CG. Immune Checkpoint Inhibitors and Cardiac Toxicity: An Emerging Issue. *Curr Med Chem* 2018; 25: 1327-39.
- Moslehi JJ, Salem JE, Sosman JA, Lebrun-Vignes B, Johnson DB. Increased reporting of fatal immune checkpoint inhibitor-associated myocarditis. *Lancet* 2018; 391: 933.
- Atallah-Yunes SA, Kadado AJ, Kaufman GP, Hernandez-Montfort J. Immune checkpoint inhibitor therapy and myocarditis: a systematic review of reported cases. *J Cancer Res Clin Oncol* 2019; 145: 1527-57.
- Ederhy S, Cautela J, Ancedy Y, Escudier M, Thuny F, Cohen A. Takotsubo-like syndrome in cancer patients treated with immune checkpoint inhibitors. *JACC Cardiovasc Imaging* 2018; 11: 1187-90.
- Pradhan R, Nautiyal A, Singh S. Diagnosis of immune checkpoint inhibitor-associated myocarditis: A systematic review. *Int J Cardiol* 2019; 296: 113-21.
- Bonaca MP, Olenchok BA, Salem JE, Wiviott SD, Ederhy S, Cohen A, et al. Myocarditis in the Setting of Cancer Therapeutics: Proposed Case Definitions for Emerging Clinical Syndromes in Cardio-Oncology. *Circulation* 2019; 140: 80-91.
- Geisler BP, Raad RA, Esaian D, Sharon E, Schwartz DR. Apical ballooning and cardiomyopathy in a melanoma patient treated with ipilimumab: a case of takotsubo-like syndrome. *J Immunother Cancer* 2015; 3: 4.
- Zhang L, Jones-O'Connor M, Awadalla M, Zlotoff DA, Thavendiranathan P, Groarke JD, et al. Cardiotoxicity of Immune Checkpoint Inhibitors. *Curr Treat Options Cardiovasc Med* 2019; 21: 32.
- Miyachi H, Kumita S, Tanaka K. PET/CT and SPECT/CT cardiac fusion imaging in a patient with takotsubo cardiomyopathy. *Eur Heart J* 2013; 34: 397.
- Hu JR, Florido R, Lipson EJ, Naidoo J, Ardehali R, Tocchetti CG, et al. Cardiovascular toxicities associated with immune checkpoint inhibitors. *Cardiovasc Res* 2019; 115: 854-68.
- Zhang L, Awadalla M, Mahmood SS, Nohria A, Hassan MZO, Thuny F, et al. Cardiovascular magnetic resonance in immune checkpoint inhibitor-associated myocarditis. *Eur Heart J* 2020; 41: 1733-43.

26. Friedrich MG, Sechtem U, Schulz-Menger J, Holmvang G, Alakija P, Cooper LT, et al.; International Consensus Group on Cardiovascular Magnetic Resonance in Myocarditis. Cardiovascular magnetic resonance in myocarditis: A JACC White Paper. *J Am Coll Cardiol* 2009; 53: 1475-87.
27. Bando S, Soeki T, Matsuura T, Tobiume T, Ise T, Kusunose K, et al. Plasma brain natriuretic peptide levels are elevated in patients with cancer. *PLoS One* 2017; 12: e0178607.
28. Kindermann I, Barth C, Mahfoud F, Ukena C, Lenski M, Yilmaz A, et al. Update on myocarditis. *J Am Coll Cardiol* 2012; 59: 779-92.
29. Nensa F, Kloth J, Tezgah E, Poeppel TD, Heusch P, Goebel J, et al. Feasibility of FDG-PET in myocarditis: Comparison to CMR using integrated PET/MRI. *J Nucl Cardiol* 2018; 25: 785-94.
30. Zhou YW, Zhu YJ, Wang MN, Xie Y, Chen CY, Zhang T, et al. Immune Checkpoint Inhibitor-Associated Cardiotoxicity: Current Understanding on Its Mechanism, Diagnosis and Management. *Front Pharmacol* 2019; 10: 1350.
31. Brahmer JR, Lacchetti C, Schneider BJ, Atkins MB, Brassil KJ, Caterino JM, et al.; National Comprehensive Cancer Network. Management of Immune-Related Adverse Events in Patients Treated With Immune Checkpoint Inhibitor Therapy: American Society of Clinical Oncology Clinical Practice Guideline. *J Clin Oncol* 2018; 36: 1714-68.
32. Koelzer VH, Rothschild SI, Zihler D, Wicki A, Willi B, Willi N, et al. Systemic inflammation in a melanoma patient treated with immune checkpoint inhibitors-an autopsy study. *J Immunother Cancer* 2016; 4: 13.
33. Salem JE, Allenbach Y, Vozy A, Brechot N, Johnson DB, Moslehi JJ, et al. Abatacept for Severe Immune Checkpoint Inhibitor-Associated Myocarditis. *N Engl J Med* 2019; 380: 2377-9.
34. Esfahani K, Buhlaiga N, Thébault P, Lapointe R, Johnson NA, Miller WH Jr. Alemtuzumab for Immune-Related Myocarditis Due to PD-1 Therapy. *N Engl J Med* 2019; 380: 2375-6.
35. Norwood TG, Westbrook BC, Johnson DB, Litovsky SH, Terry NL, McKee SB, et al. Smoldering myocarditis following immune checkpoint blockade. *J Immunother Cancer* 2017; 5: 91.
36. Chung ES, Packer M, Lo KH, Fasanmade AA, Willerson JT; Anti-TNF Therapy Against Congestive Heart Failure Investigators. Randomized, double-blind, placebo-controlled, pilot trial of infliximab, a chimeric monoclonal antibody to tumor necrosis factor-alpha, in patients with moderate-to-severe heart failure: results of the anti-TNF Therapy Against Congestive Heart Failure (ATTACH) trial. *Circulation* 2003; 107: 3133-40.
37. Michel L, Rassaf T, Totzeck M. Cardiotoxicity from immune checkpoint inhibitors. *Int J Cardiol Heart Vasc* 2019; 25: 100420.
38. Tajiri K, Aonuma K, Sekine I. Immune checkpoint inhibitor-related myocarditis. *Jpn J Clin Oncol* 2018; 48: 7-12.
39. Çiçin İ. Side Effect Management in Immunotherapy. 1<sup>st</sup> Edition. Clinics Turkey; 2019.
40. Horvat TZ, Adel NG, Dang TO, Momtaz P, Postow MA, Callahan MK, et al. Immune-Related Adverse Events, Need for Systemic Immunosuppression, and Effects on Survival and Time to Treatment Failure in Patients With Melanoma Treated With Ipilimumab at Memorial Sloan Kettering Cancer Center. *J Clin Oncol* 2015; 33: 3193-8.
41. Teulings HE, Limpens J, Jansen SN, Zwinderman AH, Reitsma JB, Spuls PI, et al. Vitiligo-like depigmentation in patients with stage III-IV melanoma receiving immunotherapy and its association with survival: a systematic review and meta-analysis. *J Clin Oncol* 2015; 33: 773-81.