

# Thread Delamination in 4.5 mm AO Cannulated Screws: A Small Case Series in the Pediatric Trauma Population

Christopher D. Murawski, MD,\* Rajiv P. Reddy, BS,† Robert T. Tisherman, MD,\*  
Patrick P. Bosch, MD,\* Jan S. Grudziak, MD, PhD,\* Stephen A. Mendelson, MD,\*  
W. Timothy Ward, MD,\* and Zeynep Deniz Olgun, MD\*

**Background:** Thread delamination associated with cannulated screws have been reported but likely represent an under-recognized complication in the orthopaedic literature. The purpose of this study is to report the occurrence of repeated hardware failures through thread delamination in the setting of a commonly used orthopaedic cannulated screw implant in a small cohort involving pediatric fracture care at a single academic level I trauma center.

**Methods:** Between August 2015 and December 2020, 9 cases of hardware failure associated with 4.5 mm arbeitsgemeinschaft für osteosynthesefragen cannulated stainless-steel screws were identified within a pediatric orthopaedic division at a single academic level I trauma center. Three cases were excluded, and 6 cases of thread delamination were retrospectively reviewed.

**Results:** Six cases of thread delamination comprised a cohort of patients with a mean age of 13.7 years (range: 12 to 15 y). All cases involved 4.5 mm arbeitsgemeinschaft für osteosynthesefragen cannulated screws, including 5 partially threaded and 1 fully threaded screw. Five cases involved open reduction and internal fixation of incarcerated medial humeral epicondylar fragments and the other case was an open reduction and internal fixation of a displaced medial malleolar fracture. Five of these occurred within a recent 18-month period of time. There were 4 cases of partial, distal thread delamination, 1 case of partial proximal thread delamination and another case of complete thread delamination which had unwound into the tibiotalar joint and required an anterior ankle arthrotomy to retrieve the thread. None of the 5 patients in this series who currently harbor a retained thread have experienced symptoms because of this issue.

**Conclusions:** Thread delamination associated with cannulated screw implantation likely represents an under-reported phenomenon in

orthopaedic surgery. In cases where retained, delaminated threads exist, these do not appear to cause short-term concern.

**Level of Evidence:** Level IV—case series.

**Key Words:** thread delamination, thread unraveling, ORIF, cannulated screw, trauma, pediatric

(*J Pediatr Orthop* 2022;42:e257–e261)

Cannulated screw systems are self-drilling, self-tapping orthopaedic implants commonly used in fracture care in both the adult and pediatric populations.<sup>1</sup> While no implant is devoid of its own unique set of advantages and disadvantages, the complications associated with cannulated screws are relatively low.<sup>1</sup> Nonetheless, complications have been reported, including fractures of the screw heads and guidewires during both hardware implantation and removal.<sup>2,3</sup> Furthermore, isolated case reports have described a unique complication in the form of thread failure with screw unraveling.<sup>4–9</sup>

Kupperman et al have previously summarized 8 cases of cannulated screws unraveling in a total of 6 published case reports spanning a 23-year period of time.<sup>9</sup> These studies included varying diameter screw sizes from multiple manufacturers implanted in several different anatomic locations. Despite these previous reports, thread delamination can be considered a relatively under-recognized complication in the orthopaedic literature. Multiple recent thread failures at our institution have prompted further investigation into this phenomenon.

The purpose of this study is to report the occurrence of repeated hardware failures through thread delamination in the setting of a commonly used orthopaedic cannulated screw implant in a small cohort involving pediatric fracture care at a single academic level I trauma center.

## METHODS

Between August 2015 and December 2020, 9 cases of hardware failure associated with 4.5 mm arbeitsgemeinschaft für osteosynthesefragen (AO) cannulated stainless-steel screws (Depuy Synthes Companies, Johnson & Johnson Medical Devices; Warsaw, IN) were identified within a pediatric orthopaedic division among 5 experienced surgeons at a single academic level I trauma center. These were identified by obtaining internal occurrence reports for hardware failure. We also cross referenced

From the \*Department of Orthopaedic Surgery, University of Pittsburgh Medical Center; and †University of Pittsburgh School of Medicine, Pittsburgh, PA.

No funding was utilized for this study.

The authors declare no conflicts of interest.

Reprints: Christopher D. Murawski, MD, Department of Orthopaedic Surgery, University of Pittsburgh, 3471 Fifth Avenue, Suite 911, Pittsburgh, PA 15213. E-mail: murawskid@upmc.edu.

Copyright © 2022 The Author(s). Published by Wolters Kluwer Health, Inc. This is an open access article distributed under the terms of the Creative Commons Attribution-Non Commercial-No Derivatives License 4.0 (CCBY-NC-ND), where it is permissible to download and share the work provided it is properly cited. The work cannot be changed in any way or used commercially without permission from the journal.

DOI: 10.1097/BPO.0000000000002047

these with case conference lists within our division where every operative case is discussed weekly amongst house staff and the attending surgeons. We also obtained information regarding the total number of similar implants used during our study period.

Of the 9 cases identified, 2 were excluded because they did not involve delamination. One involved failure at the screw head, which fractured during hardware removal of a medial humeral epicondyle fracture, and another involved a fracture of the cannulated screw at the level of the self-tapping flute during screw insertion for a proximal fifth metatarsal fracture. A third case was discrepant as to whether it truly involved delamination of the thread or whether a piece of the drill bit had fractured; this third case was therefore excluded as well, leaving a total 6 cases of thread delamination for analysis. After discussion with our Institutional Review Board, Health Insurance Portability and Accountability Act (HIPAA) authorization was obtained from each parent or guardian who agreed to having de-identified data included in this series.

For each case, patient age, sex, as well as procedural details, including the type of procedure performed and screw type utilized, were collected. In addition, screw length, thread type, whether the thread was retained or removed, and the type of delamination that occurred, were also noted. Intraoperative fluoroscopic images, as well as postoperative x-rays and follow-up office notes were reviewed.

### Surgical Technique

The surgeons involved in the current study who collectively performed the involved cases included in this report each utilize a standard surgical technique for implanting 4.5 mm AO cannulated stainless-steel screws. Briefly, a guidewire was inserted across the relevant fracture site, driven toward the far cortex and confirmed using multiplanar fluoroscopy. At this juncture, a 3.2 mm drill bit was introduced to predrill a portion of the proximal screw length. The necessary screw length was then measured, and a 4.5 mm cannulated screw was then inserted using a hand screwdriver over the guidewire with the final position confirmed fluoroscopically. One of the surgeons involved in this study utilizes a washer with final screw placement.

### Statistical Analysis

Statistical analysis was performing using a standard statistical software package (SAS; IBM Corp., Armonk, NY) and de-identified before further analysis. Where applicable, descriptive statistics were calculated, and study variables were reported as a mean and range. Fisher exact test was utilized to compare the rate of thread delamination in the current study to the rate of 1 in 6500 per month worldwide provided by the manufacturer. Time points within our cohort were also compared.

## RESULTS

Six cases of thread delamination among 4 surgeons comprised the overall cohort (Table 1). There were 2 male and 4 female patients and mean age of the overall

TABLE 1. Patient Characteristics and Procedural Details Associated With the 6 Cases of Thread Delamination

Age	Sex	Procedure	Screw Type	Screw Length	Thread Type	Complication	Retained Thread
15	F	ORIF L medial epicondyle	4.5 mm cannulated	34 mm	Partially	Partial proximal thread delamination	Yes
14	F	ORIF R medial epicondyle	4.5 mm cannulated	46 mm	Partially	Partial distal thread delamination	Yes
12	F	ORIF R medial malleolus	4.5 mm cannulated	34 mm	Partially	Complete thread delamination into the tibiotalar joint requiring anterior arthrotomy	No
14	F	ORIF R medial epicondyle	4.5 mm cannulated	64 mm	Partially	Partial distal thread delamination	Yes
13	M	ORIF R medial epicondyle	4.5 mm cannulated	50 mm	Partially	Partial distal thread delamination	No
14	M	ORIF L medial epicondyle	4.5 mm cannulated	56 mm	Fully	Partial distal thread delamination	Yes

F indicates female; M, male; ORIF, open reduction internal fixation.

population was 13.7 years (range: 12 to 15 y). All cases involved 4.5 mm AO cannulated screws, of which 5 utilized partially threaded screws and one was a fully threaded construct. Screw lengths ranged from 34 to 64 mm. Five cases involved open reduction and internal fixation of incarcerated medial humeral epicondylar fragments and the other case was an open reduction and internal fixation of a displaced medial malleolar fracture.

All complications were noted intraoperatively. There were 4 cases of partial, distal thread delamination (Fig. 1). Of these, 2 of the screws were removed intraoperatively and new screws were placed, but the retained threads were lodged within the bone and unable to be retrieved. In the other 2 cases, the delaminated thread was not felt to affect the fixation and was left in situ. There was another case of partial proximal thread delamination; this screw was removed intraoperatively. The thread was unable to be retrieved and a 4.5 mm, partially threaded, noncannulated screw was placed for final fixation. The medial malleolar case involved a complete thread delamination. The delaminated thread penetrated the tibial plafond and unwound into the tibiotalar joint, requiring an anterior ankle arthrotomy to retrieve the thread (Fig. 2). In this case, the thread and screw were able to be removed in their entirety, after which a new screw was placed without complication to achieve final fixation.

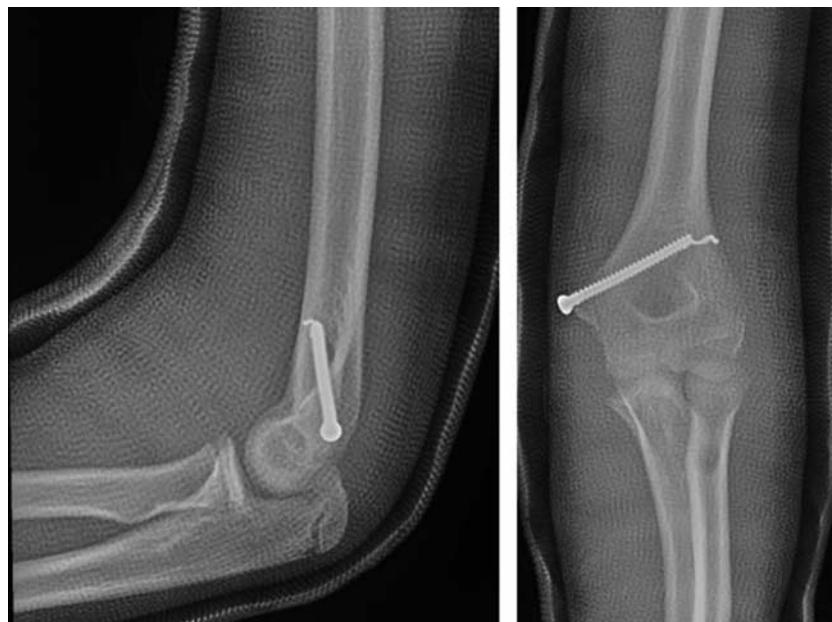None of the 4 patients in this series who currently harbor a retained thread have experienced symptoms because of this issue at a mean clinical follow-up time of 9 months (range: 6 to 12 mo). Of these 4 patients, 2 underwent elective removal of symptomatic hardware at the medial humeral epicondyle, but the retained threads remain and were asymptomatic at final follow-up. These elective procedures occurred at 10 and 11 months after the index procedures. The

other 2 patients had no complaints relating to their hardware at final follow-up (Fig. 3).

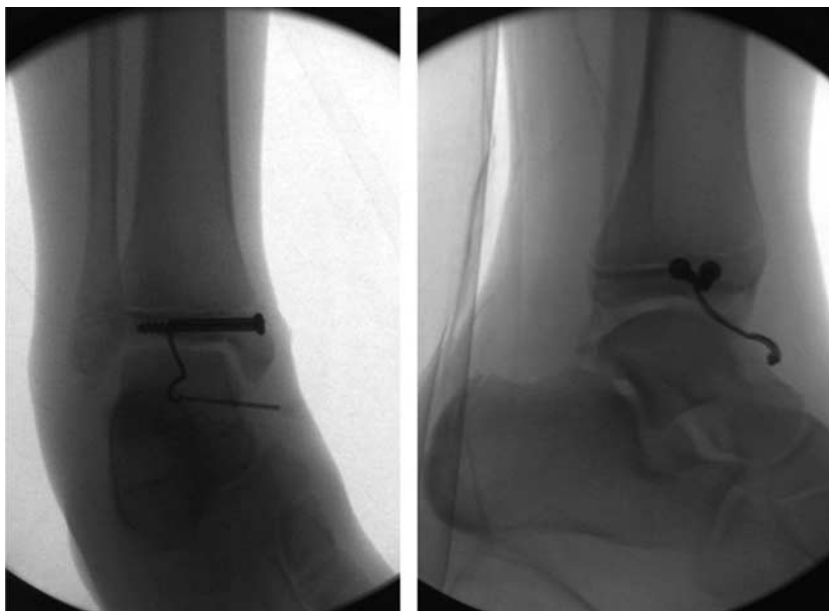
Overall, five hundred and thirty-two 4.5 mm AO cannulated screws were implanted at our institution during the study period and the rate of thread delamination, 1.1% (6/532), was significantly higher than the worldwide rate of 1 in 6500 per month provided by the manufacturer ( $P < 0.00001$ ). Five of the 6 cases in the current cohort occurred within a recent 18-month period between July 2019 and December 2020; the rate of thread delamination during this period was 3.2% (5/157) and was also significantly higher than the rate provided by the manufacturer ( $P < 0.00001$ ). In the period before this between August 2015 and June 2019, the rate of thread delamination was 0.2% (1/366) at our institution and this was not significantly different than the rate provided by the manufacturer ( $P = 0.056$ ). When these 2 periods were compared, the rate of thread delamination at our institution between July 2019 and August 2020 was significantly higher than between August 2015 and June 2019 ( $P = 0.012$ ).

## DISCUSSION

This small series reports 6 cases of thread delamination in a pediatric population associated with 4.5 mm AO cannulated stainless-steel screws, most commonly in the setting of fixation of medial humeral epicondyle fractures. It is important to note that each case that occurred at our institution generated an occurrence report internally, which according to standard procedure was subsequently entered into a reporting system to the United States Food and Drug Administration. Each case was also submitted for consideration for presentation at our department's morbidity and mortality conference. While previous case reports and a small case series



**FIGURE 1.** Postoperative anteroposterior and lateral radiographs of the elbow obtained in a cast demonstrating a partial, distal thread delamination after open reduction and internal fixation of a medial humeral epicondyle fracture.

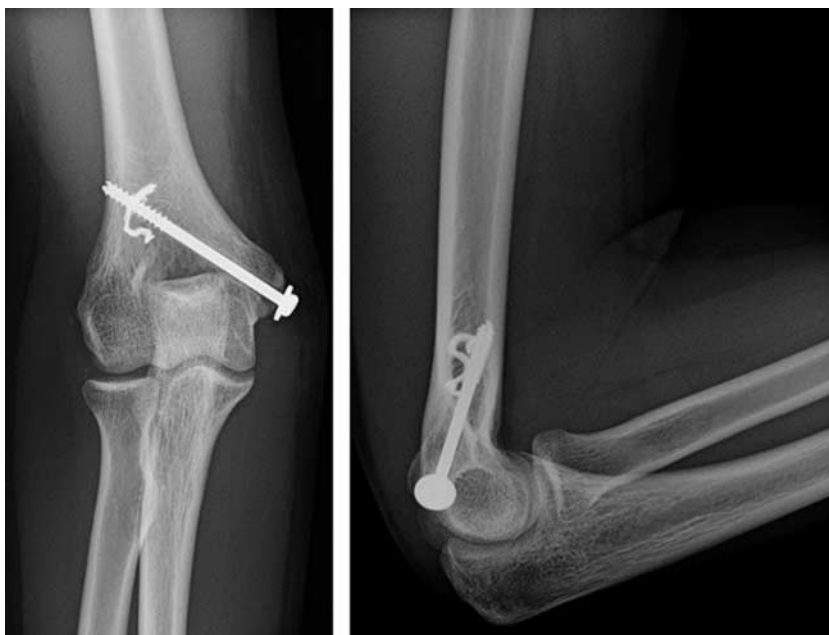

**FIGURE 2.** Intraoperative anteroposterior and lateral fluoroscopic images of the ankle demonstrating complete thread delamination of a 4.5 mm AO screw with unwinding of the thread into the tibiotalar joint. A second 4.5 mm AO screw that did not delaminate can be visualized just anterior to the delaminated screw. AO indicates *Arbeitsgemeinschaft für Osteosynthesefragen*.

have been reported on this phenomenon,<sup>4-10</sup> this study is, to the best of our knowledge, the largest single study to date involving one specific implant occurring over a relatively short period of time. AO screws remain widely accepted in orthopaedic fracture fixation and this seemingly recent development is therefore concerning.

Although the surgical technique guide for the orthopaedic implant referenced in the current study does

include a cannulated tap for use in subjectively denser bone, it is important to emphasize that predrilling and pretapping are unnecessary in the majority of cases as the implants themselves contain self-drilling and self-tapping flutes.<sup>11</sup> This is consistent with the technique utilized in the current study in that none of the cases were predrilled or pretapped over the length of the screw. While it is plausible to suggest that predrilling and pretapping along the



**FIGURE 3.** One-year postoperative anteroposterior and lateral radiographs of the elbow after open reduction and internal fixation of a medial humeral epicondyle fracture demonstrate that the retained thread from the index procedure remains in situ.

entirety of the guidewire may help to avoid this phenomenon, it does not explain why 5 of these cases have occurred within an 18-month period in the current study.

Kupperman et al<sup>9</sup> have previously summarized 8 cases of cannulated screw unraveling, including 7 cases in 5 previously published studies and 1 single case from their own institution. These cases were of majority male patients (7/8; 88%), included a range of patient ages from 12 to 38 years, as well as involved multiple anatomic locations, including the proximal and distal humerus, proximal and distal tibia and the medial cuneiform. In their review, thread diameters varied from 4.0 to 5.0 mm, involved multiple companies and the majority of cases did not involve predrilling (6/8; 75%). The 2 cases that did perform predrilling only involved the outer cortex. The metal composition (eg, titanium or stainless steel) or thread type (eg, partial, full) of the screws were not reported in all cases.

The majority of cases (5/6; 83.3%) in the current study involved the distal humerus in the form of medial humeral epicondyle fractures and all (6/6; 100%) involved 4.5 mm AO cannulated stainless-steel screws, of which the majority (5/6; 83.3%) were partially threaded. Generally, distal humeral bone can be quite dense, particularly in younger patients, and we agree with previous authors that cannulated screws contacting endosteal cortical bone does provide a reasonable environment for the flute to perceptibly contact the thread, thereby causing delamination (6 to 9). Interestingly, though, we are unable to specifically attribute any of our cases to contact with dense cortical bone and, similar to Mooney and Simmons,<sup>5</sup> would postulate that, in the absence of any defect(s) in the hardware itself, dense cancellous bone and the rotational process of inserting the hardware appears to be a more relevant explanation. In cases where thread delamination was experienced in our study, the surgeons recalled an unusual increase in tactile feedback during screw insertion prompting further evaluation with fluoroscopy.

It is unclear to the current authors whether changes and/or defects in the manufacturing process or the implant material itself may play some role in this phenomenon. To the best of our knowledge, the screws are cast from a single piece of steel without a metallic interface which would otherwise represent a weak point for delamination to occur. Our informal communications with the manufacturer lead us to believe that similar cases have not been reported to them from other institutions and that there are no recently disclosed changes to the manufacturing process within at least the past several years. Interestingly, the manufacturer disclosed to us that there is a known delamination rate of 1 screw per month worldwide among ~6500 similar screws. The rate of delamination at our institution was statistically significantly higher than this rate reported by the manufacturer in addition to an earlier period within our same cohort. This would appear to suggest at least a transient issue in the manufacturing process.

In an effort to avoid this new concern surrounding thread delamination, one senior surgeon in the current study

is now utilizing open reduction and percutaneous pinning for medial humeral epicondyle fractures with the use of standard Kirschner wires instead of screw fixation. A technique using K-wires is not without its own set of drawbacks, including the need for subsequent removal in the office and the possibility of disrupting a fibrous union at the medial epicondyle during removal. Furthermore, percutaneous pinning is not a technique that is generalizable to all potential scenarios in which this phenomenon can be extrapolated, but perhaps represents a more benign technique as opposed to screw fixation in at least 1 setting. Alternatively, solid screw fixation may represent an additional option to consider.

This study is not without limitation. The retrospective study design carries its own inherent disadvantages and the small sample size undoubtedly implies at least some level of selection bias particularly in the setting of a short follow-up time without a true hypothesis-driven clinical endpoint. The current study was also such that we are unable to derive an estimate of the true prevalence of this phenomenon of thread delamination without a proper prospective observational study. Despite these limitations, a small case series involving the largest known cohort to date is therefore compelling.

Thread delamination associated with cannulated screw implantation likely represents an under-reported phenomenon in orthopaedic surgery. Surgeons should be aware of this potential complication and ensure fluoroscopic confirmation of final hardware integrity. In cases where retained threads exist, these do not appear to cause short-term concern.

## REFERENCES

1. Moehring HD, Johnson PG. The use of cannulated screws in musculoskeletal trauma. A review of surgical techniques. *Orthop Rev.* 1994;(suppl):10–21.
2. Schwend RK, Hennrikus WL, O'Brien TJ, et al. Complications when using the cannulated 3.5 mm screw system. *Orthopedics.* 1997;20:221–223.
3. Robb JE, Annan IH, Macnicol MF. Guidewire damage during cannulated screw fixation for slipped capital femoral epiphysis. *J Pediatr Orthop B.* 2003;12:219–221.
4. Brown CH, Cullen NC. Disassembly of a small cannulated cancellous screw. *Foot Ankle Int.* 1999;20:468–469.
5. Mooney JF III, Simmons TW. A previously unreported complication of the AO cannulated 4.0- and 4.5-mm screw systems: a review of three cases. *J South Orthop Assoc.* 2003;12:160–162.
6. Levene AP, Templeton P. Previously unreported failure of a Synthes 4.0 mm diameter cannulated screw. *Injury Extra.* 2008;39:212–215.
7. Sabnis B, Brenkel I, Chesney D, et al. Unusual mode of mechanical failure of an AO cannulated self drilling screw. A case report. *Acta Orthop Belg.* 2009;75:557–560.
8. Chen A, Willis-Owen C, Akhtar K, et al. Failure of ASNIS III 5.0 mm cannulated screw: a case report. *Cases J.* 2010;3:9.
9. Kupperman E, Franko O, Indresano A, et al. Cannulated screw unraveling: a case series and literature-based review of an under-recognized complication. *Arch Orthop Trauma Surg.* 2013;133:65–67.
10. Patel M. Cannulated screw dethreading during fixation of a pediatric distal humerus medial condyle fracture. *J POSNA.* 2020;2. [Epub ahead of print].
11. Depuy Synthes 4.5 mm Cannulated Screws Surgical Technique. 2016–17. Available at: [http://synthes.vo.llnwd.net/o16/LLNWMB8/US%20Mobile/Synthes%20North%20America/Product%20Support%20Materials/Technique%20Guides/DSUSTRM02160832-1\\_4\\_5\\_CannScrew\\_STG\\_150dpi.pdf](http://synthes.vo.llnwd.net/o16/LLNWMB8/US%20Mobile/Synthes%20North%20America/Product%20Support%20Materials/Technique%20Guides/DSUSTRM02160832-1_4_5_CannScrew_STG_150dpi.pdf). Accessed January 21, 2020.