



Contents lists available at ScienceDirect

Journal of Hand Surgery Global Online

journal homepage: www.JHSGO.org

Original Research

Rupture Site Location of Surgically Treated Thumb Metacarpophalangeal Ulnar and Radial Collateral Ligaments

Alejandro Morales-Restrepo, MD, * Sumail Bhogal, MD, * John R. Fowler, MD *

* Department of Orthopaedic Surgery, University of Pittsburgh Medical Center, Pittsburgh, PA



ARTICLE INFO

Article history:

Received for publication December 29, 2020

Accepted in revised form May 19, 2021

Available online June 9, 2021

Key words:

Hand
Ligament
Soft tissue reconstruction
Thumb
Trauma

Purpose: Thumb metacarpophalangeal collateral ligament injuries occur in 50 per 100,000 people. The most frequent rupture site locations that are often cited are the thumb ulnar collateral ligament (UCL) occurring distally from the proximal phalanx and the radial collateral ligament (RCL) occurring proximally from the metacarpal head.^{2,16} In this study, we report the frequency of the rupture site location of both thumb UCL and RCL injuries.

Methods: A retrospective analysis of 1,004 consecutive finger collateral ligament surgeries performed at a single academic institution over 17 years was conducted. The inclusion criteria were any patient who underwent either a thumb UCL or RCL surgical repair. Patients were excluded if the rupture etiology was secondary to a laceration or a congenital or chronic deformity. Descriptive statistics were presented.

Results: Three hundred forty-seven patients were included in this study, including 288 thumb UCL injuries and 59 thumb RCL injuries. The rupture site location for the thumb UCL was proximal in 5.9% (n = 17) of the cases, distal in 92.7% (n = 267), and midsubstance in 1.4% (n = 4). Fifty-three (18.4%) Stener lesions were noted. The rupture site location for the thumb RCL was proximal in 69.5% (n = 41) of the cases, distal in 25.4% (n = 15), and midsubstance in 5.1% (n = 3).

Conclusions: In thumb UCL ruptures, the rupture site occurred most often at the proximal phalanx, whereas RCL injuries occurred most often at the metacarpal head. Overall, there was greater heterogeneity of RCL rupture site location frequency. Careful surgical exposure should be performed when repairing either the UCL or RCL. Further studies will determine if differences in rupture site location portend a difference in prognosis.

Type of study/level of evidence: Prognostic III.

Copyright © 2021, THE AUTHORS. Published by Elsevier Inc. on behalf of The American Society for Surgery of the Hand. This is an open access article under the CC BY-NC-ND license (<http://creativecommons.org/licenses/by-nc-nd/4.0/>).

Ulnar proper collateral ligament (UCL) injuries occur approximately 10 times more frequently than radial proper collateral ligament (RCL) injuries to the thumb.¹ The thumb metacarpophalangeal joint (MCPJ) is stabilized by static and dynamic stabilizers. Primary stability is imparted by the static stabilizers, which consist of the UCL, RCL, their corresponding accessory collateral ligaments, volar plate, and dorsal capsule.^{1–4} Injuries to the thumb MCPJ collateral ligaments are common, with UCL injuries being the most common and RCL injuries accounting for anywhere from 10% to 42%.^{5,6}

Declaration of interests: No benefits in any form have been received or will be received related directly or indirectly to the subject of this article.

Corresponding author: Sumail Bhogal, MD, Kaufmann Medical, 3471 Fifth Ave Building, Suite 1010, Pittsburgh, PA 15213.

E-mail address: bhogals@upmc.edu (S. Bhogal).

<https://doi.org/10.1016/j.jhsg.2021.05.007>

2589-5141/Copyright © 2021, THE AUTHORS. Published by Elsevier Inc. on behalf of The American Society for Surgery of the Hand. This is an open access article under the CC BY-NC-ND license (<http://creativecommons.org/licenses/by-nc-nd/4.0/>).

The diagnosis and identification of the rupture site of a proper collateral ligament allows an appropriate treatment regimen, nonsurgical or operative intervention, to be developed. Obviously, at the time of any surgical intervention, the surgeon should be able to inspect the ligament and determine the location of the rupture. However, surgical preplanning is often helpful in allowing the performance of an efficient surgery that limits dissection. In addition, for a rare midsubstance tear, a reconstruction may be required. Ultimately, the goal of the treatment is to prevent further instability and delay the progression of arthritis.^{5,7}

Physical examination alone cannot be used to determine the specific rupture location of the ligament, such as whether it is a distal, proximal, or midsubstance tear. Radiographs, magnetic resonance imaging, and ultrasound are imaging modalities that have been widely used to help establish a diagnosis.^{8–15} Of these, magnetic resonance imaging is the only modality found to be 99%

sensitive and 100% specific in determining the correct diagnosis.¹⁰ However, among the abovementioned studies, the specific rupture site location has often not been reported.

The literature supports that UCL tears occur up to 90% of the time distally, and RCL tears have a more heterogenous rupture location.^{2,16} However, the abovementioned studies have all been small surgical case series comprising less than 50 patients.^{17–25}

The purpose of this study was to evaluate the frequency of UCL and RCL rupture site locations during surgery in a heterogenous patient population at a tertiary referral center. We hypothesized that this larger surgical series confirms that UCL tears occur most often distally, whereas RCL tears have more heterogenous tear locations. We aim to update the current literature with these data that may have important clinical implications.

Materials and Methods

We retrospectively reviewed 1,004 consecutive patient records from 2000 to 2017 at a single level-1 trauma tertiary referral care center for all patients who underwent surgical repair or reconstruction of the metacarpophalangeal collateral ligament of any finger according to all Current Procedural Terminology codes containing the phrase “collateral ligament.” This study was reviewed and approved by the institutional review board, and all data were collected in a manner compliant with the Health Insurance Portability and Accountability Act. All procedures followed were in accordance with the ethical standards of the responsible committee on human experimentation (institutional and national) and with the Helsinki Declaration of 1975, as revised in 2008.

The inclusion criteria for this study were patients with a metacarpophalangeal UCL or RCL injury of the thumb, with collateral ligament repair or reconstruction being the primary indication for surgery. Patients were excluded if the collateral ligament that was repaired was present at a site other than in the thumb; no operative report was available; no rupture site location was explicitly stated in the operative report; the rupture etiology was secondary to a laceration, infection, or tumor excision; the rupture was associated with a congenital deformity reconstruction or chronic deformity reconstruction, such as in rheumatoid arthritis; there was simultaneous rupture of both the collateral ligaments; and the index surgical procedure was performed by an outside institution.

Descriptive statistics were calculated and presented for the entire study population (mean \pm SD, range), and the Fisher exact test was used to assess the significance of relationships between categorical variables.

Results

After the review of the 1,004 consecutive patient records from 2000 to 2017, 347 patient records were included in the study. Six hundred fifty-seven records were eliminated based on the following exclusion criteria: 248 for having undergone collateral ligament repair at a site other than in the thumb; 170 for no operative report available in either electronic medical records or paper records; 119 for lacerations as the primary etiology for the rupture; 88 for not having a rupture site identified during surgery; 13 for etiologies secondary to chronic rheumatoid arthritis, infection, tumor excision, and congenital deformities; 9 for having undergone simultaneous repair of both the UCL and RCL; 8 for duplicated charts in the database; and finally, 2 for having undergone revisions where the index surgery was performed at an outside institution. Of the remaining 347 charts included, 197 (56.8%) belonged to men and 150 (43.2%) to women. The mean age of the patients was 34 ± 15.6 years (range, 12–82).

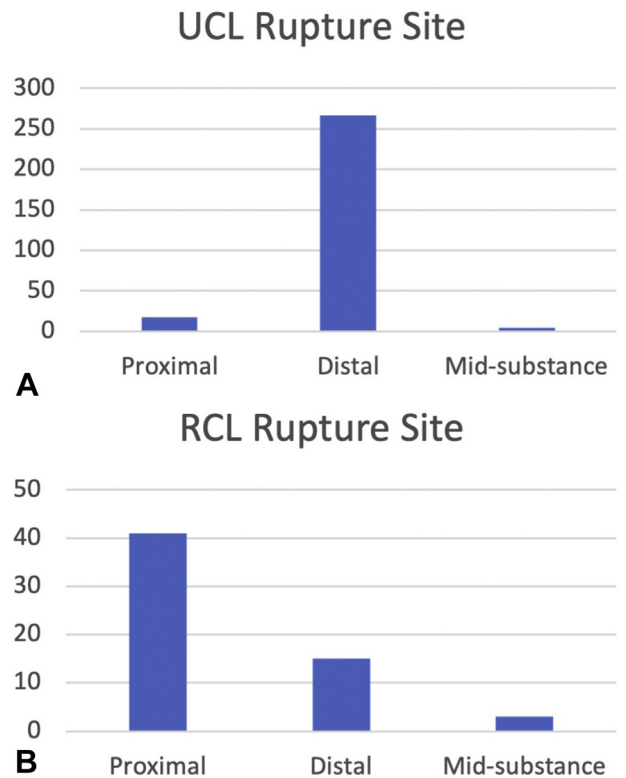


Figure. Rupture site location frequency of surgically treated **A** thumb UCL and **B** thumb RCL tears.

UCL

For our UCL data, 288 thumbs were included in the final analysis. Of them, 158 (54.9%) belonged to men with a mean age of 32.8 ± 16.5 years (range, 14–82) and 130 (45.1%) to women with a mean age of 36.9 ± 14.9 years (range, 14–76). Two hundred eleven acute (<3 months) injuries were due to a high-energy mechanism, such as a motor vehicle collision, and 22 were due to a low-energy mechanism, such as a fall while standing or due to a fight; 55 injuries were chronic in nature. The rupture site location was found to be distal in 267 (92.7%) cases, proximal in 17 (5.9%), and mid-substance in 4 (1.4%). Avulsion fractures off the proximal phalanx were noted in 18.4% ($n = 53$) of the injuries. These results are summarized in [Figure](#). There was no evidence of an association between the location of rupture and the mechanism of injury for UCL ruptures ($P = .75$).

RCL

For our RCL data, 59 thumbs were included in the final analysis. Of them, 39 (66.1%) belonged to men with a mean age of 29.8 ± 12.1 years (range, 12–66) and 20 (33.9%) to women with a mean age of 31.9 ± 16.1 years (range, 11–64). Twenty-seven were acute injuries due to a high-energy mechanism, and 1 injury was due to a low-energy mechanism; 31 injuries were chronic in nature. The rupture site location was found to be distal in 15 (25.4%) cases, proximal in 41 (69.5%), and midsubstance in 3 (5.1%), as graphically depicted in [Figure](#). There was no evidence of an association between the location of rupture and the mechanism of injury for RCL ruptures ($P = 1.00$).

Discussion

The purpose of this study was to determine the rupture site locations for main lateral stabilizers of the thumb, the UCL and RCL,

Table
Review of the Frequency of Rupture Site Location for Both UCL and RCL Ruptures Reported in the Literature

UCL Rupture Site				
Study	Total Patients (n)	Distal % (n)	Proximal % (n)	Midsubstance % (n)
Stener (1962) ¹⁶	9	89 (8)	11 (1)	-
Coonrad and Goldner (1968) ²⁷	6	33 (2)	67 (4)	-
Smith (1977) ²	48	98 (47)	2 (1)	-
Louis et al (1986) ¹⁷	20	90 (18)	10 (2)	-
Weiland et al (1997) ²⁸	36	(34)	(2)	-
Melone et al (2000) ⁴	60	100 (60)	-	-
Harley et al (2004) ^{19,*}	16	63 (10)	38 (6)	-
Moharram et al (2013) ²⁹	27	93 (25)	7 (2)	-
Boesmueller et al (2017) ²⁶	1,582	84 (1333)	5 (75)	11 (174)
RCL Rupture Site				
Study	Total Patients (n)	Distal % (n)	Proximal % (n)	Midsubstance % (n)
Coonrad and Goldner (1968) ²⁷	5	60 (3)	40 (2)	-
Smith (1977) ²	17	35 (6)	24 (4)	-
Camp et al (1980) ²⁰	9	44 (4)	33 (3)	22 (2)
Durham et al (1993) ²¹	18	22 (4)	22 (4)	56 (10)
McDermott et al (1998) ²³	5	80 (4)	20 (1)	-
Melone et al (2000) ⁴	40	20 (8)	40 (16)	20 (8)
Coyle (2002) ²⁴	45	29 (13)	55 (25)	16 (7)
Catalano et al (2006) ³⁰	16	44 (7)	37 (6)	19 (3)
Taylor et al (2013) ²⁵	11	36 (4)	27 (3)	36 (4)

* Cadaveric study.

in a heterogenous patient population at a tertiary care referral center. In this study, we showed that thumb UCL tears occur distally from the phalangeal insertion 93% (n = 267) of the time, proximally at the metacarpal origin 6% (n = 17) of the time, and lastly, mid-substance 1% (n = 4) of the time. Thumb RCL tears occurred distally in 25% (n = 15) of the cases, proximally in 70% (n = 41) of the cases, and midsubstance in 5% (n = 3) (Fig.).

The above findings are in agreement with those published in smaller surgical case series dating from Stener's original publication to the only other large surgical series published in 2017 by Boesmueller et al²⁶ in Austria. Table reviews the values seen in 15 studies.^{2,4,16,17,18,19,20,21,24,25,26,27,28,29,30} Across nearly 60 years of published data, the UCL has been shown to predominantly tear distally at the proximal phalanx insertion, and the RCL has a more heterogenous tear location, with tears occurring frequently at both the proximal metacarpal origins and distally at the phalangeal insertion.

Despite the data reported in this study and data amassed from the literature regarding differences in rupture site locations, very little is known about the etiology of this specific rupture site pattern. In an anatomic study of the radial thumb by Lyons et al,²² the authors suggested that a difference in the origin and insertion size may explain the higher proximal origin rupture rate of RCL tears. However, they reported that the proximal metacarpal origin site was only smaller in 16% of cases. The distal phalangeal insertion site was smaller 54% of the time, and both the origin and insertion sites were equal 29% of the time. Since then, several studies have cited Lyon's findings suggesting that the smaller size of metacarpal origin plays a role in the higher rate of proximal ruptures.^{6,25,31} Our results show a 70% proximal rupture rate of the RCL, whereas other studies have shown a higher predominance of distal tears.^{2,27,20,23,25} Thus, the abovementioned explanation for the higher rate of proximal ruptures appears inadequate. Further, we have no available literature describing differences in the size of the UCL origin or insertion sites to compare the above data with. Carlson et al³² published their anatomic data describing the exact metacarpal origin and phalangeal insertion for both the UCL and RCL. Unfortunately, they did not report the size of the origins or insertions. Their findings have important implications for the

recreation of the anatomic footprint. Bean et al³³ previously reported that as much as a 2-mm displacement of either the UCL origin or insertion can result in significant changes in both the radial deviation and flexion of the thumb metacarpophalangeal joint.

Distal UCL tears may be more frequently reported in the surgical literature because the anatomy of the ulnar side of the thumb may impede healing. As reported in the literature, Stener lesions are fairly common and are an indication for surgical repair because the adductor aponeurosis entraps the distal free end of the ligament.¹⁶ However, in proximal UCL tears, the adductor aponeurosis overlies the distal end of the MCPJ and allows the free end of the torn ligament to remain adjacent to its origin, acting as a natural splint for the ligament. Perhaps, there are more proximal UCL tears, but because of the reasons mentioned above, they are more stable and may be treated nonsurgically. In contrast, on the radial side of the thumb, the abductor aponeurosis does not directly overlie the RCL. This difference in anatomical relationship possibly allows the ligament to remain against the MCPJ, allowing eventual healing and not necessitating surgery. We propose that future studies be performed assessing specific rupture site locations in thumb UCL and RCL tears managed operatively versus nonsurgically. This can include a review of available magnetic resonance imaging or ultrasound data on nonsurgically treated tears.

Limitations

A limitation of our study is that these results were collected at a single institution. However, our diverse patient cohort ranged from 12 to 82 years of age and from athletes to elderly patients. Another limitation is the retrospective nature of the study. Although obtaining prospective data on tear location is not feasible, future biomechanical cadaver studies of the thumb can be performed to assess the specific in situ origin and insertion widths of the ligaments. Additionally, 170 of the total 1,004 charts reviewed could not be included in the study because of the lack of available data in the electronic medical or paper records. This group with missing data may have contributed to the overall frequencies reported, specifically in the RCL group (n = 59). Our data go back to the year

2000, when paper medical records were, at times, incompletely transferred to new electronic medical records. Lastly, most of the studies that have reported the rupture site location were surgical series, including our own, and thus could have caused a bias in the results such that surgically treated UCL or RCL ruptures are more often distal and proximal, respectively. Our study found that operatively treated UCL ruptures occur more often at the distal phalangeal insertion, whereas RCL ruptures have a more heterogeneous rupture site location, with a higher predominance of proximal ruptures. These findings support the need for defining the specific rupture site location during surgery and, thus, limiting surgical dissection when possible.

References

1. Minami A, An KN, Cooney WP III, Linscheid RL, Chao EY. Ligamentous structures of the metacarpophalangeal joint: a quantitative anatomic study. *J Orthop Res.* 1983;1(4):361–368.
2. Smith RJ. Post-traumatic instability of the metacarpophalangeal joint of the thumb. *J Bone Joint Surg.* 1977;59(1):14–21.
3. Loebig TG, Anderson DD, Baratz ME, Imbriglia JE. Radial instability of the metacarpophalangeal joint of the thumb: a biomechanical investigation. *J Hand Surg.* 1995;20(1):102–104.
4. Melone CP Jr, Beldner S, Basuk RS. Thumb collateral ligament injuries: an anatomic basis for treatment. *Hand Clin.* 2000;16(3):345–357.
5. Rhee PC, Jones DB, Kakar S. Management of thumb metacarpophalangeal ulnar collateral ligament injuries. *J Bone Joint Surg.* 2012;94(21):2005–2012.
6. Edelstein DM, Kardashian G, Lee SK. Radial collateral ligament injuries of the thumb. *J Hand Surg.* 2008;33(5):760–770.
7. Gluck JS, Balutis EC, Glickel SZ. Thumb ligament injuries. *J Hand Surg.* 2015;40(4):835–842.
8. McKeon KE, Gelberman RH, Calfee RP. Ulnar collateral ligament injuries of the thumb: phalangeal translation during valgus stress in human cadavera. *J Bone Joint Surg.* 2013;95(10):881–887.
9. Hinke DH, Erickson SJ, Chamoy L, Timins ME. Ulnar collateral ligament of the thumb: MR findings in cadavers, volunteers, and patients with ligamentous injury (gamekeeper's thumb). *Am J Roentgenol.* 1994;163(6):1431–1434.
10. Rashidi A, Haj-Mirzaian A, Dalili D, Fritz B, Fritz J. Evidence-based use of clinical examination, ultrasonography, and MRI for diagnosing ulnar collateral ligament tears of the metacarpophalangeal joint of the thumb: systematic review and meta-analysis. *Eur Radiol.* 2021; <https://doi.org/10.1007/s00330-020-07666-z>.
11. Louis DS, Buckwalter KA. Magnetic resonance imaging of the collateral ligaments of the thumb. *J Hand Surg.* 1989;14(4):739–741.
12. Plancher KD, Ho CP, Cofield SS, Viola R, Hawkins RJ. Role of MR imaging in the management of "skier's thumb" injuries. *Magn Reson Imaging Clin N Am.* 1999;7(1):73–84.
13. Mahajan M, Tolman C, Würth B, Rhemrev SJ. Clinical evaluation vs magnetic resonance imaging of the skier's thumb: a prospective cohort of 30 patients. *Eur J Radiol.* 2016;85(10):1750–1756.
14. Papandrea RF, Fowler T. Injury at the thumb UCL: is there a Stener lesion? *J Hand Surg.* 2008;33(10):1882–1884.
15. Shekarchi B, Dashti MM, Shahrezaei M, Karimi E. The accuracy of ultrasonography in detection of ulnar collateral ligament of thumb injuries; a cross-sectional study. *Emerg.* 2018;6(1):e15.
16. Stener B. Displacement of the ruptured ulnar collateral ligament of the metacarpo-phalangeal joint of the thumb. *J Bone Joint Surg.* 1962;44(4):869–879.
17. Louis DS, Huebner JJ, Hankin FM. Rupture and displacement of the ulnar collateral ligament of the metacarpophalangeal joint of the thumb. *J Bone Joint Surg.* 1986;68(1):1320–1326.
18. Alzaga F, Molina J. Acute ulnar collateral ligament injuries of the thumb metacarpophalangeal joint: an anatomical and clinical study. *Acta Orthop.* 1998;64(4):378–384.
19. Harley BJ, Werner FW, Green JK. A biomechanical modeling of injury, repair, and rehabilitation of ulnar collateral ligament injuries of the thumb. *J Hand Surg.* 2004;29(5):915–920.
20. Camp RA, Weatherwax RJ, Miller EB. Chronic posttraumatic radial instability of the thumb metacarpophalangeal joint. *J Hand Surg.* 1980;5(3):221–225.
21. Durham JW, Khuri S, Kim MH. Acute and late radial collateral ligament injuries of the thumb metacarpophalangeal joint. *J Hand Surg.* 1993;18(2):232–237.
22. Lyons RP, Kozin SH, Failla JM. The anatomy of the radial side of the thumb: static restraints in preventing subluxation and rotation after injury. *Am J Orthop.* 1998;27(11):759–763.
23. McDermott TP, Levin LS. Suture anchor repair of chronic radial ligament injuries of the metacarpophalangeal joint of the thumb. *J Hand Surg.* 1998;23(2):271–274.
24. Coyle MP. Grade III radial collateral ligament injuries of the thumb metacarpophalangeal joint: treatment by soft tissue advancement and bony reattachment. *J Hand Surg.* 2003;28(1):14–20.
25. Taylor KF, Lanzi JT, Cage JM, Drake ML. Radial collateral ligament injuries of the thumb metacarpophalangeal joint: epidemiology in a military population. *J Hand Surg.* 2013;38(3):532–536.
26. Boesmueller S, Huf W, Retzl G, et al. The influence of sex and trauma impact on the rupture site of the ulnar collateral ligament of the thumb. *PLoS ONE.* 2017;12(7):e0181754.
27. Coonrad RW, Goldner JL. A study of the pathological findings and treatment in soft-tissue injury of the thumb metacarpophalangeal joint: with a clinical study of the normal range of motion in one thousand thumbs and a study of post mortem findings of ligamentous structures in relation to function. *J Bone Joint Surg.* 1968;50(3):439–451.
28. Weiland AJ, Berner SH, Hotchkiss RN, McCormack RR, Gerwin M. Repair of acute ulnar collateral ligament injuries of the thumb metacarpophalangeal joint with an intraosseous suture anchor. *J Hand Surg.* 1997;22(4):585–591.
29. Moharram AN. Repair of thumb metacarpophalangeal joint ulnar collateral ligament injuries with microanchors. *Ann Plast Surg.* 2013;71(5):500–502.
30. Catalano LW III, Gupta S, Ragland R III, Glickel SZ, Johnson C, Barron OA. Closed treatment of nonrheumatoid extensor tendon dislocations at the metacarpophalangeal joint. *J Hand Surg.* 2006;31(2):242–245.
31. Avery DM, Inkellis ER, Carlson MG. Thumb collateral ligament injuries in the athlete. *Curr Rev Musculoskelet Med.* 2017;10(1):28–37.
32. Carlson MG, Warner KK, Meyers KN, Hearn KA, Kok PL. Anatomy of the thumb metacarpophalangeal ulnar and radial collateral ligaments. *J Hand Surg.* 2012;37(10):2021–2026.
33. Bean CH, Tencer AF, Trumble TE. The effect of thumb metacarpophalangeal ulnar collateral ligament attachment site on joint range of motion: an in vitro study. *J Hand Surg.* 1999;24(2):283–287.